A 38-year-old woman, gravida 1, para 0, comes to the office for a routine prenatal checkup at approximately 32 weeks gestation. The patient has started having persistent, throbbing headaches that are not relieved by acetaminophen. She has no nausea, vomiting, or abdominal pain. She eats a well-balanced diet, takes prenatal vitamins, and has normal bowel movements. Medical history is unremarkable and prenatal care has been uneventful. Review of medical records show that her blood pressure was 130/80 mm Hg at 28 weeks gestation. Today, blood pressure is 165/100 mm Hg, and heart rate is 90/min. Which of the following additional findings is most likely present in this patient?

A. Arteriovenous nicking

B. Fasting hyperglycemia

C. Ketonuria

D. Proteinuria

E. Splenomegaly

F. Thrombocytosis

Submit

A 38-year-old woman, gravida 1, para 0, comes to the office for a routine prenatal checkup at approximately 32 weeks gestation. The patient has started having persistent, throbbing headaches that are not relieved by acetaminophen. She has no nausea, vomiting, or abdominal pain. She eats a well-balanced diet, takes prenatal vitamins, and has normal bowel movements. Medical history is unremarkable and prenatal care has been uneventful. Review of medical records show that her blood pressure was 130/80 mm Hg at 28 weeks gestation. Today, blood pressure is 165/100 mm Hg, and heart rate is 90/min. Which of the following additional findings is most likely present in this patient?

- A. Arteriovenous nicking (6%)
- B. Fasting hyperglycemia (6%)
- C. Ketonuria (0%)
- ✓ D. Proteinuria (80%)
- E. Splenomegaly (1%)
- F. Thrombocytosis (4%)

Omitted
Correct answer
D

80%
Answered correctly

44 secs
Time Spent

06/29/2020
Last Updated

Explanation

Hypertensive disorders of pregnancy	
[illegible]	• Systolic pressure **≥140 mm Hg** &/or diastolic pressure **≥90 mm Hg** prior to conception or 20

Hypertensive disorders of pregnancy	
Chronic hypertension	• Systolic pressure **≥140 mm Hg** &/or diastolic pressure **≥90 mm Hg** prior to conception or 20 weeks gestation
Gestational hypertension	• New-onset elevated blood pressure at ≥20 weeks gestation • No proteinuria or end-organ damage
Preeclampsia	• New-onset elevated blood pressure at ≥20 weeks gestation **AND** • Proteinuria **OR** signs of end-organ damage
Eclampsia	• Preeclampsia **AND** • New-onset grand mal seizures

A patient with **preeclampsia** has **gestational hypertension** (**systolic pressure ≥140 mm Hg** and/or **diastolic pressure ≥90 mm Hg** after 20 weeks gestation) and **proteinuria** or signs of **end-organ damage**. Risk factors for preeclampsia include nulliparity, personal or family history of preeclampsia, obesity, and chronic hypertension.

The pathophysiology of preeclampsia is based on abnormal placentation. **Abnormal placental vasculature** leads to placental hypoxia and ischemia, which in turn result in the release of antiangiogenic factors into maternal circulation. The release of these inflammatory factors from the hypoxic placenta causes endothelial injury. Damage to the endothelium increases its permeability, resulting in proteinuria. In addition, dysregulation of vascular tone results in elevated blood pressure, which can cause end-organ damage, such as to the brain (eg, headaches, visual changes) and liver (eg, abdominal pain).

(Choice A) Arteriovenous nicking is a funduscopic finding in patients with chronic hypertension. It is an early manifestation of retinopathy in patients with years of hypertension due to exudative vascular changes, a consequence of endothelial necrosis. This patient has new-onset

A patient with **preeclampsia** has **gestational hypertension** (**systolic pressure ≥140 mm Hg** and/or **diastolic pressure ≥90 mm Hg** after 20 weeks gestation) and **proteinuria** or signs of **end-organ damage**. Risk factors for preeclampsia include nulliparity, personal or family history of preeclampsia, obesity, and chronic hypertension.

The pathophysiology of preeclampsia is based on abnormal placentation. **Abnormal placental vasculature** leads to placental hypoxia and ischemia, which in turn result in the release of antiangiogenic factors into maternal circulation. The release of these inflammatory factors from the hypoxic placenta causes endothelial injury. Damage to the endothelium increases its permeability, resulting in proteinuria. In addition, dysregulation of vascular tone results in elevated blood pressure, which can cause end-organ damage, such as to the brain (eg, headaches, visual changes) and liver (eg, abdominal pain).

(Choice A) Arteriovenous nicking is a funduscopic finding in patients with chronic hypertension. It is an early manifestation of retinopathy in patients with years of hypertension due to exudative vascular changes, a consequence of endothelial necrosis. This patient has new-onset hypertension and no previous medical history, making retinopathy unlikely.

(Choice B) Gestational diabetes is a state of insulin resistance causing fasting hyperglycemia due to increased levels of human placental lactogen. It is usually diagnosed at 24-28 weeks gestation and is unlikely in this patient with uncomplicated prenatal care.

(Choice C) Ketonuria occurs in starvation and diabetic ketoacidosis. Any condition with decreased carbohydrate metabolism and increased fat degradation will produce this finding. This patient reports a healthy diet and no nausea or vomiting, making ketonuria unlikely.

(Choice E) Splenomegaly is a nonspecific finding that can occur in a variety of conditions, such as portal hypertension or splenic infiltration by hematologic malignancies. Portal hypertension is unlikely in the absence of bloody vomitus or tarry stools.

(Choice F) Thrombocytosis occurs most commonly in myeloproliferative diseases. Pre-eclampsia and HELLP syndrome can have associated thrombocytopenia, not increased platelets. Patients with HELLP syndrome also have hemolysis and elevated liver enzyme levels.

Educational objective:
Preeclampsia is defined as hypertension onset after 20 weeks gestation plus proteinuria or signs of end-organ damage. End-organ damage is due to endothelial damage secondary to the release of inflammatory factors from abnormal placentation.

References

Hypertension in pregnancy. Report of the American College of Obstetricians and Gynecologists' Task Force on Hypertension in Pregnancy

changes) and liver (eg, abdominal pain).

(Choice A) Arteriovenous nicking is a funduscopic finding in patients with chronic hypertension. It is an early manifestation of retinopathy in patients with years of hypertension due to exudative vascular changes, a consequence of endothelial necrosis. This patient has new-onset hypertension and no previous medical history, making retinopathy unlikely.

(Choice B) Gestational diabetes is a state of insulin resistance causing fasting hyperglycemia due to increased levels of human placental lactogen. It is usually diagnosed at 24-28 weeks gestation and is unlikely in this patient with uncomplicated prenatal care.

(Choice C) Ketonuria occurs in starvation and diabetic ketoacidosis. Any condition with decreased carbohydrate metabolism and increased fat degradation will produce this finding. This patient reports a healthy diet and no nausea or vomiting, making ketonuria unlikely.

(Choice E) Splenomegaly is a nonspecific finding that can occur in a variety of conditions, such as portal hypertension or splenic infiltration by hematologic malignancies. Portal hypertension is unlikely in the absence of bloody vomitus or tarry stools.

(Choice F) Thrombocytosis occurs most commonly in myeloproliferative diseases. Pre-eclampsia and HELLP syndrome can have associated thrombocytopenia, not increased platelets. Patients with HELLP syndrome also have hemolysis and elevated liver enzyme levels.

Educational objective:
Preeclampsia is defined as hypertension onset after 20 weeks gestation plus proteinuria or signs of end-organ damage. End-organ damage is due to endothelial damage secondary to the release of inflammatory factors from abnormal placentation.

References

- Hypertension in pregnancy. Report of the American College of Obstetricians and Gynecologists' Task Force on Hypertension in Pregnancy.
- Mapping the theories of preeclampsia and the role of angiogenic factors: a systematic review.

Pathology	Pregnancy, Childbirth & Puerperium	Preeclampsia
Subject	System	Topic

Copyright © UWorld. All rights reserved.

A 59-year-old man is being evaluated for markedly elevated prostate-specific antigen levels. He has no bone pain or urinary symptoms. The patient has no chronic medical conditions or surgical history. His father died of prostate cancer. Vital signs are normal. Digital rectal examination reveals an indurated prostate with no palpable nodules. The remainder of the examination is normal. Prostate biopsy is planned. Which of the following is the best way to obtain a diagnosis in this patient?

A. Cystoscopy guided; multiple random biopsies of the prostate

B. Cystoscopy guided; single biopsy of the central portion of the prostate

C. Transperineal approach; fine-needle aspiration of the prostate

D. Transrectal route; multiple random biopsies of the prostate

E. Transrectal route; single biopsy from the center of the gland

Submit

A 59-year-old man is being evaluated for markedly elevated prostate-specific antigen levels. He has no bone pain or urinary symptoms. The patient has no chronic medical conditions or surgical history. His father died of prostate cancer. Vital signs are normal. Digital rectal examination reveals an indurated prostate with no palpable nodules. The remainder of the examination is normal. Prostate biopsy is planned. Which of the following is the best way to obtain a diagnosis in this patient?

- A. Cystoscopy guided; multiple random biopsies of the prostate (19%)
- B. Cystoscopy guided; single biopsy of the central portion of the prostate (6%)
- C. Transperineal approach; fine-needle aspiration of the prostate (9%)
- ✓ D. Transrectal route; multiple random biopsies of the prostate (56%)
- E. Transrectal route; single biopsy from the center of the gland (8%)

Omitted
Correct answer
D

56%
Answered correctly

01 sec
Time Spent

06/08/2020
Last Updated

Explanation

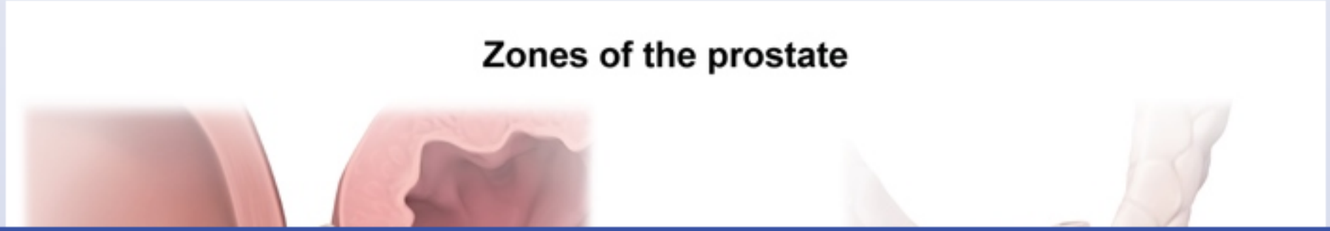

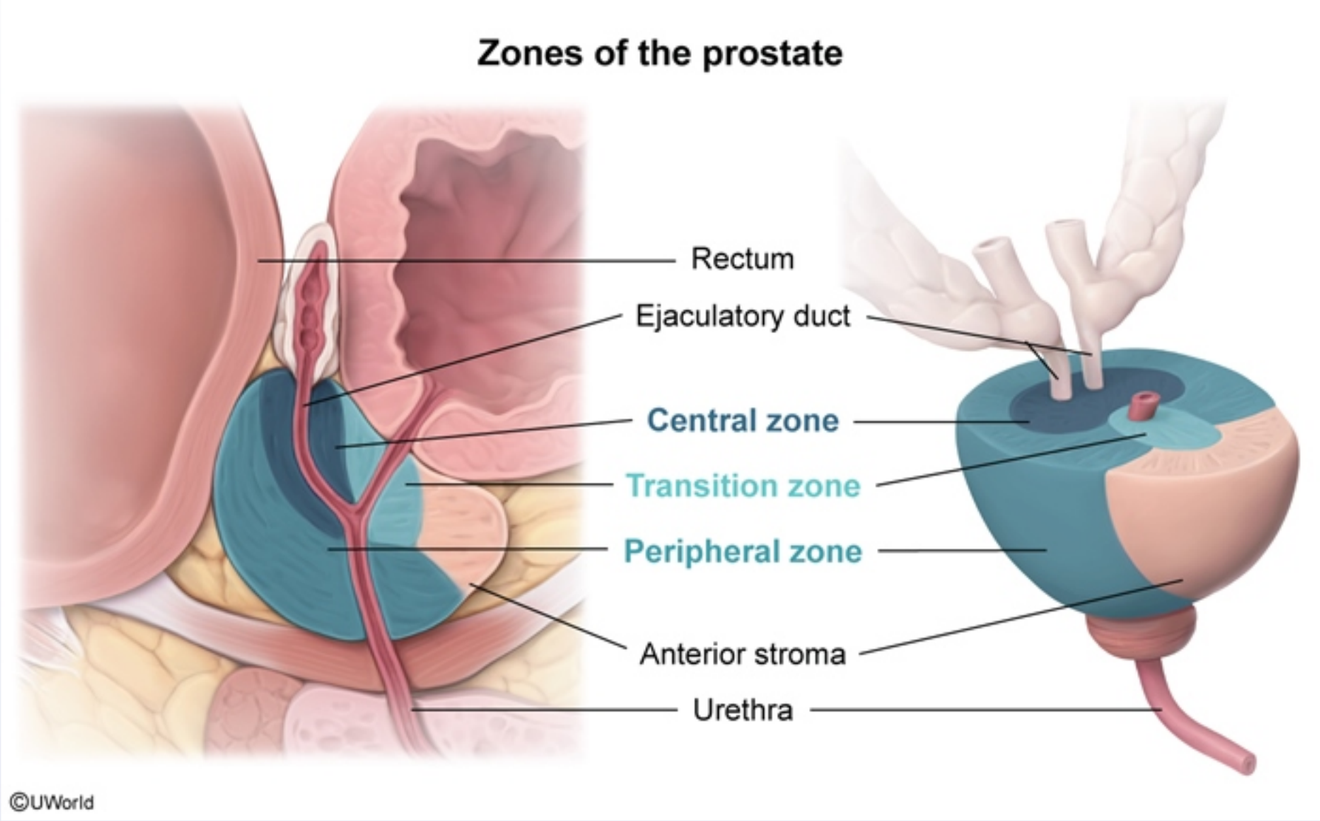

The **prostate** is a walnut-sized gland that encases the urethra and vas deferens. It abuts the urinary bladder superiorly and the rectum posteriorly and is composed of 3 distinct zones:

- The **peripheral zone** is largely glandular and is the site of **>85%** of prostate **adenocarcinoma**. Because this zone borders the rectum, patients with suspected prostate cancer generally undergo **transrectal ultrasound–guided biopsy**. In this procedure, transrectal ultrasound identifies the borders of the prostate and suspicious hypoechoic lesions; **multiple core biopsies** (usually 10-12) are then obtained from random locations within the apical and far-lateral prostate (peripheral zone). Because the distal urethra passes through only

©UWorld

The **prostate** is a walnut-sized gland that encases the urethra and vas deferens. It abuts the urinary bladder superiorly and the rectum posteriorly and is composed of 3 distinct zones:

- The **peripheral zone** is largely glandular and is the site of **>85%** of prostate **adenocarcinoma**. Because this zone borders the rectum, patients with suspected prostate cancer generally undergo **transrectal ultrasound–guided biopsy**. In this procedure, transrectal ultrasound identifies the borders of the prostate and suspicious hypoechoic lesions; **multiple core biopsies** (usually 10-12) are then obtained from random locations within the apical and far-lateral prostate (peripheral zone). Because the distal urethra passes through only a small portion of the peripheral zone, prostate cancer does not typically present with urinary symptoms (eg, voiding difficulty, hematuria).
- The **central zone** surrounds the ejaculatory duct. This zone is primarily composed of stroma elements; prostate cancer rarely develops in this area.
- The **transition zone** surrounds the **urethra**. This is the primary site of benign prostatic hyperplasia. Because only 10% of prostate cancers arise in this region, cystoscopy approaches (via the urethra) are not typically used to sample the prostate for cancer **(Choices A and B)**.

(Choice C) Fine-needle aspiration is not recommended for the diagnosis of prostate cancer because tissue architecture is lost during sampling. Transperineal core biopsies are occasionally used to diagnose prostate cancer in men who cannot tolerate the transrectal approach.

(Choice E) The diagnosis of prostate cancer requires multiple core biopsies to obtain adequate sampling of the prostate. A single biopsy would dramatically increase the risk of a false negative result. Furthermore, the central portion of the gland is less likely to develop prostate cancer than the peripheral portion.

Educational objective:
Most prostate cancer arises in the peripheral zone of the gland, which abuts the rectum. Therefore, prostate biopsies are primarily obtained via the transrectal approach; multiple random core samples of the prostate are typically taken. Because only a small part of the peripheral zone encases the distal urethra, patients with prostate cancer do not typically present with urinary symptoms.

Pathology	Male Reproductive System	Prostate cancer
Subject	System	Topic

and is composed of 3 distinct zones:

- The **peripheral zone** is largely glandular and is the site of **>85%** of prostate **adenocarcinoma**. Because this zone borders the rectum, patients with suspected prostate cancer generally undergo **transrectal ultrasound–guided biopsy**. In this procedure, transrectal ultrasound identifies the borders of the prostate and suspicious hypoechoic lesions; **multiple core biopsies** (usually 10-12) are then obtained from random locations within the apical and far-lateral prostate (peripheral zone). Because the distal urethra passes through only a small portion of the peripheral zone, prostate cancer does not typically present with urinary symptoms (eg, voiding difficulty, hematuria).
- The **central zone** surrounds the ejaculatory duct. This zone is primarily composed of stroma elements; prostate cancer rarely develops in this area.
- The **transition zone** surrounds the **urethra**. This is the primary site of benign prostatic hyperplasia. Because only 10% of prostate cancers arise in this region, cystoscopy approaches (via the urethra) are not typically used to sample the prostate for cancer **(Choices A and B)**.

(Choice C) Fine-needle aspiration is not recommended for the diagnosis of prostate cancer because tissue architecture is lost during sampling. Transperineal core biopsies are occasionally used to diagnose prostate cancer in men who cannot tolerate the transrectal approach.

(Choice E) The diagnosis of prostate cancer requires multiple core biopsies to obtain adequate sampling of the prostate. A single biopsy would dramatically increase the risk of a false negative result. Furthermore, the central portion of the gland is less likely to develop prostate cancer than the peripheral portion.

Educational objective:
Most prostate cancer arises in the peripheral zone of the gland, which abuts the rectum. Therefore, prostate biopsies are primarily obtained via the transrectal approach; multiple random core samples of the prostate are typically taken. Because only a small part of the peripheral zone encases the distal urethra, patients with prostate cancer do not typically present with urinary symptoms.

Pathology	Male Reproductive System	Prostate cancer
Subject	System	Topic

Copyright © UWorld. All rights reserved.

A 34-year-old African American woman, gravida 3 para 3, comes to the office for increasing pelvic pressure. For the past year, the patient has had chronic, dull pelvic pressure. In addition, she has had increased urinary frequency, but no dysuria or hematuria. The patient has no chronic medical conditions and no prior surgeries. She had 3 term vaginal deliveries in her 20s and is currently using a progestin-only contraceptive. The patient has 3-4 days of monthly menstrual bleeding. She follows a vegan diet and works in a textile factory. There is a family history of ovarian cancer. Blood pressure is 112/68 mm Hg and pulse is 64/min. Cardiopulmonary examination is normal. The abdomen is soft, nontender, and nondistended. There is a palpable, irregular mass slightly above the pubic symphysis. On pelvic examination, the cervix has no lesions and the uterus is irregularly enlarged and mobile. Urinalysis is normal. Which of the following is the most likely risk factor for this patient's clinical presentation?

- A. Family history of ovarian cancer
- B. Occupational exposure in a textile factory
- C. Prior vaginal deliveries
- D. Progestin-only contraception use
- E. Race
- F. Vegan diet

Submit

A 34-year-old African American woman, gravida 3 para 3, comes to the office for increasing pelvic pressure. For the past year, the patient has had chronic, dull pelvic pressure. In addition, she has had increased urinary frequency, but no dysuria or hematuria. The patient has no chronic medical conditions and no prior surgeries. She had 3 term vaginal deliveries in her 20s and is currently using a progestin-only contraceptive. The patient has 3-4 days of monthly menstrual bleeding. She follows a vegan diet and works in a textile factory. There is a family history of ovarian cancer. Blood pressure is 112/68 mm Hg and pulse is 64/min. Cardiopulmonary examination is normal. The abdomen is soft, nontender, and nondistended. There is a palpable, irregular mass slightly above the pubic symphysis. On pelvic examination, the cervix has no lesions and the uterus is irregularly enlarged and mobile. Urinalysis is normal. Which of the following is the most likely risk factor for this patient's clinical presentation?

- A. Family history of ovarian cancer (20%)
- B. Occupational exposure in a textile factory (13%)
- C. Prior vaginal deliveries (10%)
- D. Progestin-only contraception use (16%)
- ✓ E. Race (39%)
- F. Vegan diet (0%)

Omitted
Correct answer
E

Collecting Statistics

02 secs
Time Spent

07/08/2020
Last Updated

Explanation

Uterine leiomyomas (fibroids)	

Clinical features	• Heavy, prolonged menses
	• Pressure symptoms
	  ◦ Pelvic pain
	  ◦ Constipation
	  ◦ Urinary frequency
	• Obstetric complications
	  ◦ Impaired fertility
	  ◦ Pregnancy loss
	  ◦ Preterm labor
	• Enlarged, irregular uterus

Workup	• Ultrasound
Treatment	• Asymptomatic: observation • Symptomatic: CHC, surgery

CHC = combined hormonal contraception.

This patient with an **irregularly enlarged uterus** likely has **uterine leiomyomas**, more commonly known as fibroids. Uterine fibroids are benign, monoclonal smooth muscle tumors that develop within the uterine myometrium. Depending on their size and location, leiomyomas may cause heavy menses (due to increased endometrial surface area), obstetric complications, and bulk symptoms (eg, **chronic pelvic pressure**, **urinary frequency**, constipation).

Uterine leiomyomas are relatively common (up to 25%) in reproductive-age women. The differing prevalence, size, and symptom severity among patients likely depends on multiple factors such as family history and race. **African American women** are 2-3 times more likely than Caucasian women to develop fibroids, and symptom onset typically occurs earlier (eg, mid to late 20s). This may be due to African American women having an early age of menarche, which is an additional risk factor for fibroid development.

Diagnosis is confirmed by ultrasound. Treatment can be either medical (eg, combined estrogen-progestin contraceptive pills) or surgical (eg

CHC = combined hormonal contraception.

This patient with an **irregularly enlarged uterus** likely has **uterine leiomyomas**, more commonly known as fibroids. Uterine fibroids are benign, monoclonal smooth muscle tumors that develop within the uterine myometrium. Depending on their size and location, leiomyomas may cause heavy menses (due to increased endometrial surface area), obstetric complications, and bulk symptoms (eg, **chronic pelvic pressure**, **urinary frequency**, constipation).

Uterine leiomyomas are relatively common (up to 25%) in reproductive-age women. The differing prevalence, size, and symptom severity among patients likely depends on multiple factors such as family history and race. **African American women** are 2-3 times more likely than Caucasian women to develop fibroids, and symptom onset typically occurs earlier (eg, mid to late 20s). This may be due to African American women having an early age of menarche, which is an additional risk factor for fibroid development.

Diagnosis is confirmed by ultrasound. Treatment can be either medical (eg, combined estrogen-progestin contraceptive pills) or surgical (eg, hysterectomy).

(Choice A) A family history of ovarian cancer increases the risk for ovarian cancer in those with *BRCA* 1 and 2 gene mutations. Patients with ovarian cancer can present with bulk symptoms; however, examination typically reveals large, immobile ovaries. There is no correlation between a family history of ovarian cancer and fibroids.

(Choice B) Working in a textile factory can be a risk factor for bladder cancer due to occupational exposure to chemical carcinogens. Patients with bladder cancer can present with increased urinary frequency but typically have concomitant hematuria.

(Choice C) Prior deliveries (ie, increased parity) increase the risk of adenomyosis, or endometrial tissue within the myometrium. Adenomyosis may present with pelvic pressure; however, patients typically have a symmetrically enlarged, tender, globular uterus. Increased parity may decrease the risk of fibroids.

(Choice D) Progestin-only contraception may decrease fibroid size and can be used to treat symptomatic fibroids. It is not a risk factor for fibroid development.

(Choice F) Some environmental factors, such as increased red meat consumption, may increase the risk of uterine fibroids. A vegan diet has not been associated with an increased risk.

Diagnosis is confirmed by ultrasound. Treatment can be either medical (eg, combined estrogen progestin contraceptive pills) or surgical (eg, hysterectomy).

(Choice A) A family history of ovarian cancer increases the risk for ovarian cancer in those with *BRCA* 1 and 2 gene mutations. Patients with ovarian cancer can present with bulk symptoms; however, examination typically reveals large, immobile ovaries. There is no correlation between a family history of ovarian cancer and fibroids.

(Choice B) Working in a textile factory can be a risk factor for bladder cancer due to occupational exposure to chemical carcinogens. Patients with bladder cancer can present with increased urinary frequency but typically have concomitant hematuria.

(Choice C) Prior deliveries (ie, increased parity) increase the risk of adenomyosis, or endometrial tissue within the myometrium. Adenomyosis may present with pelvic pressure; however, patients typically have a symmetrically enlarged, tender, globular uterus. Increased parity may decrease the risk of fibroids.

(Choice D) Progestin-only contraception may decrease fibroid size and can be used to treat symptomatic fibroids. It is not a risk factor for fibroid development.

(Choice F) Some environmental factors, such as increased red meat consumption, may increase the risk of uterine fibroids. A vegan diet has not been associated with an increased risk.

Educational objective:
Uterine leiomyoma (ie, fibroids) can present with bulk symptoms (eg, pelvic pressure, urinary frequency) and an irregularly enlarged uterus. African American women are at increased risk of developing fibroids.

References

- Racial differences in fibroid prevalence and ultrasound findings in asymptomatic young women (18-30 years old): a pilot study.

Pathology	Female Reproductive System & Breast	Uterine fibroids
Subject	System	Topic

Copyright © UWorld. All rights reserved.

Diagnosis is confirmed by ultrasound. Treatment can be either medical (eg, combined estrogen progestin contraceptive pills) or surgical (eg, hysterectomy).

Exhibit Display

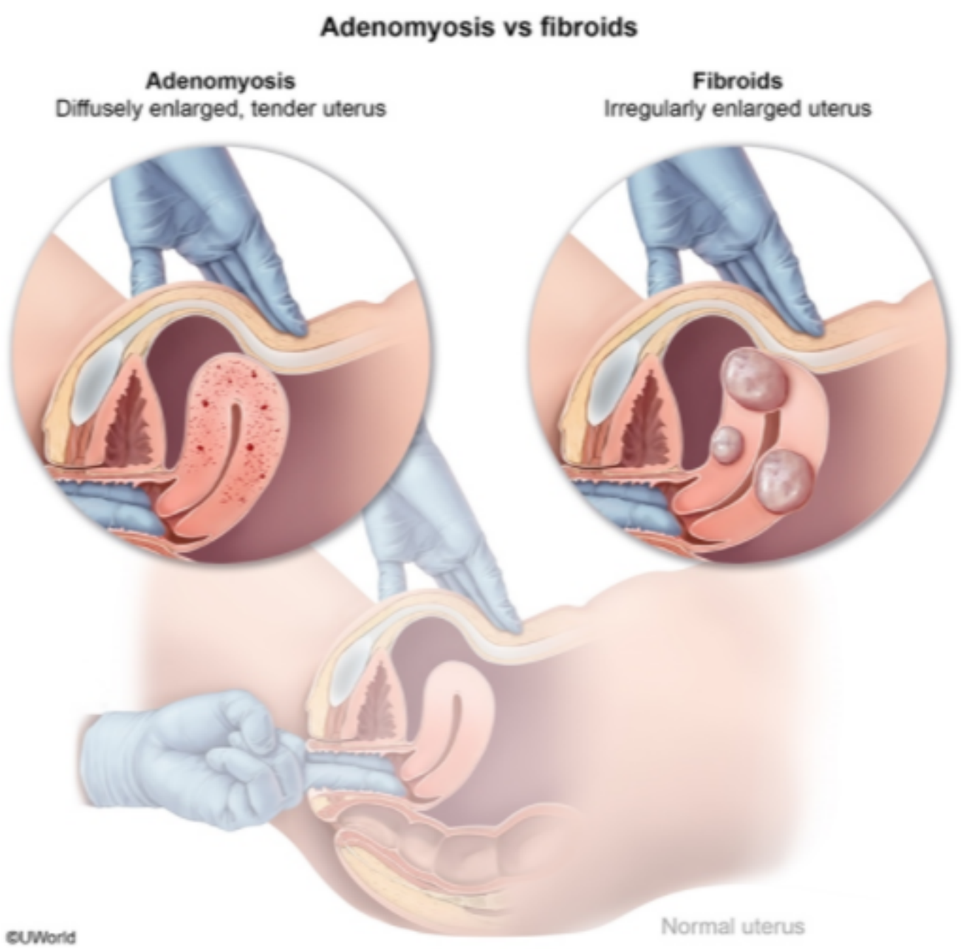

Zoom In Zoom Out Reset Add To Flash Card

A 45-year-old woman comes to the office due to unintentional loss of 6.8 kg (15 lb) over the past 6 months. She used to enjoy dining with friends but has become concerned about lower abdominal pressure and feeling full very quickly. She also has epigastric pain but no dysphagia, regurgitation, vomiting, or diarrhea. Physical examination shows bilateral adnexal fullness. A pelvic ultrasound shows bilateral complex ovarian masses with solid and cystic components. Chest x-ray is normal. CT scan shows stomach wall thickening and ovarian masses. Which of the following is most likely to be seen on histologic evaluation of the ovaries?

A. Bilobed nuclei and inclusion-like nucleoli

B. Intercellular bridges and keratin pearls

C. Mucin-secreting signet cells

D. Nests of epithelial cells with abundant clear cytoplasm

E. Sebaceous glands and keratinaceous debris

Submit

A 45-year-old woman comes to the office due to unintentional loss of 6.8 kg (15 lb) over the past 6 months. She used to enjoy dining with friends but has become concerned about lower abdominal pressure and feeling full very quickly. She also has epigastric pain but no dysphagia, regurgitation, vomiting, or diarrhea. Physical examination shows bilateral adnexal fullness. A pelvic ultrasound shows bilateral complex ovarian masses with solid and cystic components. Chest x-ray is normal. CT scan shows stomach wall thickening and ovarian masses. Which of the following is most likely to be seen on histologic evaluation of the ovaries?

A. Bilobed nuclei and inclusion-like nucleoli (2%)

B. Intercellular bridges and keratin pearls (4%)

✓ C. Mucin-secreting signet cells (78%)

D. Nests of epithelial cells with abundant clear cytoplasm (10%)

E. Sebaceous glands and keratinaceous debris (4%)

Omitted
Correct answer
C

78%
Answered correctly

02 secs
Time Spent

02/26/2020
Last Updated

Explanation

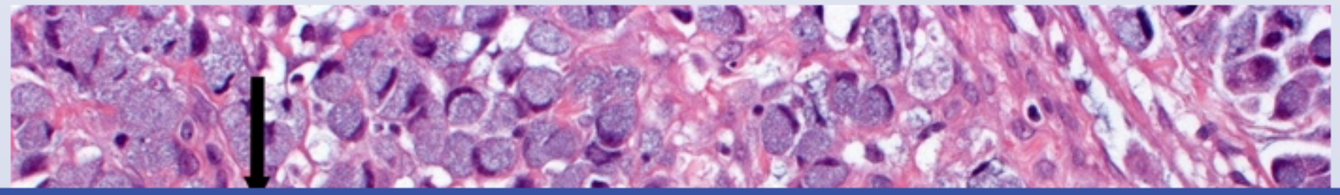

Explanation

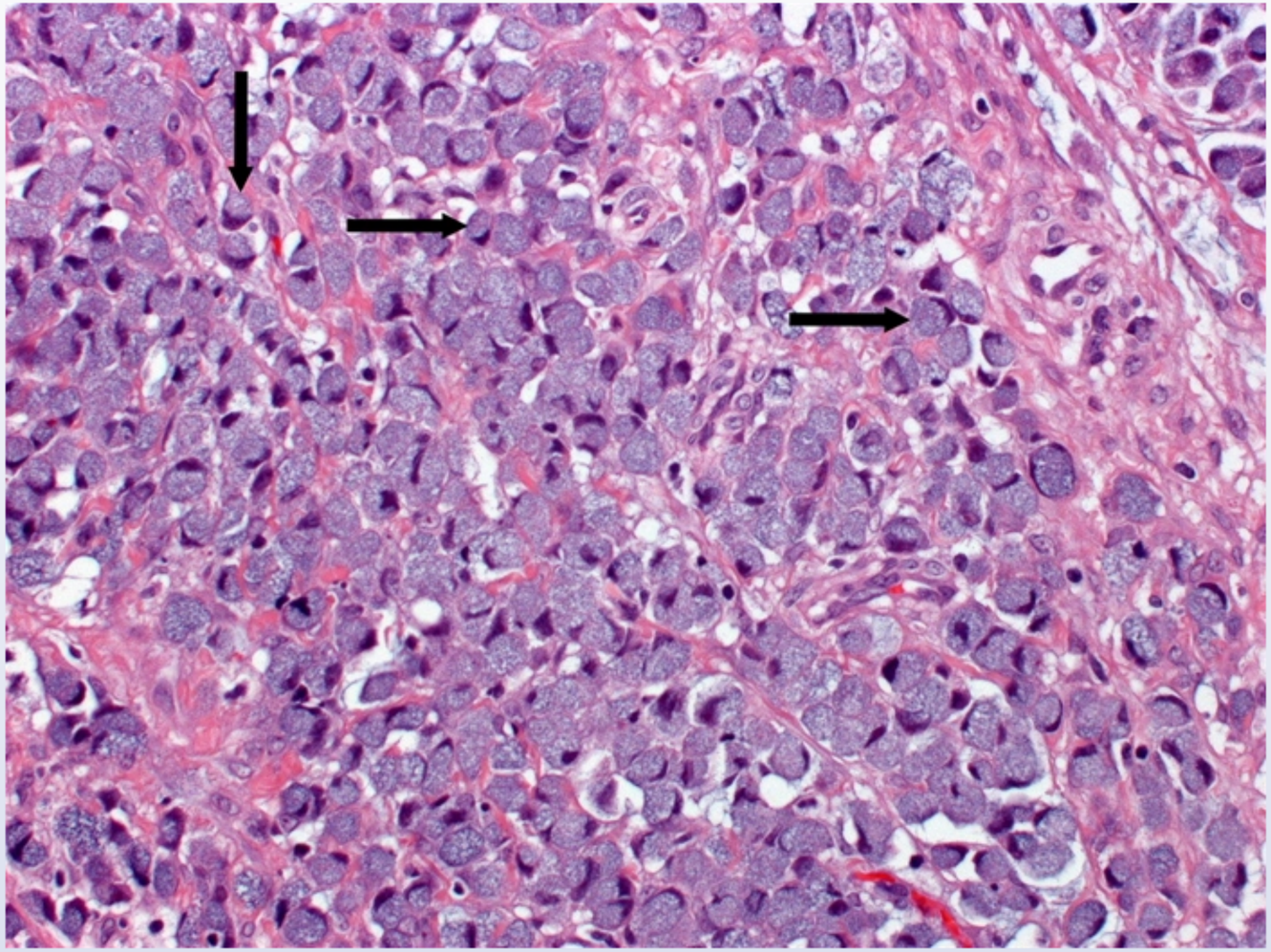

This patient's unintentional weight loss and early satiety are concerning for malignancy. The epigastric pain and gastric thickening on CT scan, as well as the lower abdominal pressure and adnexal masses, suggest gastric and ovarian involvement, respectively. The ovaries are a common site

This patient's unintentional weight loss and early satiety are concerning for malignancy. The epigastric pain and gastric thickening on CT scan, as well as the lower abdominal pressure and adnexal masses, suggest gastric and ovarian involvement, respectively. The ovaries are a common site for metastases, most typically from a primary gastrointestinal tract cancer. This patient likely has a **Krukenberg tumor**, a primary **gastric cancer** that has **metastasized to the ovary**. The cardinal histologic feature is nests of **signet ring cells** (black arrows). The appearance is a result of large amounts of **mucin displacing the nucleus**.

Gastric signet ring cell cancer is particularly infiltrative and spreads to the ovaries by lymphatic invasion and peritoneal seeding. In contrast, primary ovarian and other cancers rarely metastasize to the stomach.

(Choice A) Hodgkin lymphoma is notable for Reed-Sternberg cells, which are giant B cells with bilobed ("owl's eye") or multiple nuclei and prominent inclusion-like nucleoli. Most patients have an enlarged lymph node in the neck or a mediastinal mass on chest x-ray, with no involvement of other organ systems.

(Choice B) Intercellular bridges are connections between squamous epithelial cells, and keratin pearls are whorl-shaped accumulations of keratin from squamous cell cancer (SCC). Common sites of SCC include the skin (eg, scaly patch or plaque on face), lung (cough, hemoptysis, chest pain, dyspnea), and middle third of the esophagus (dysphagia, unintentional weight loss).

(Choice D) Renal cell carcinoma causes the triad of flank pain, hematuria, and a palpable abdominal mass. Clear-cell type is the most common type and appears as nests of epithelial cells with abundant clear cytoplasm (black arrows) separated by branching vascular tissue. This tumor spreads to the lungs and bone by invasion of the inferior vena cava without gastric or ovarian involvement.

(Choice E) Mature cystic teratomas of the ovaries are most commonly asymptomatic or can cause torsion (acute pelvic pain) if very large. Sebaceous glands and keratinaceous debris indicate the presence of skin and hair follicles and are hallmarks of this benign tumor.

Educational objective:
A Krukenberg tumor is a gastric tumor that has metastasized to the ovary and can present with unintentional weight loss, epigastric pain, and adnexal masses. Histologically, the metastatic tumor cells have large amounts of mucin with apically displaced nuclei, resulting in a signet ring appearance.

References

Settings

1 2 3 4 5 6 7 8 9 10 11 12 13 14 15 16 17 18 19 20 21 22 23 24 25 26 27 28 29 30

Item 4 of 32
Question Id: 127

Mark | Previous | Next | Full Screen | Tutorial | Lab Values | Notes | Calculator | Reverse Color | Text Zoom | Settings

Exhibit Display

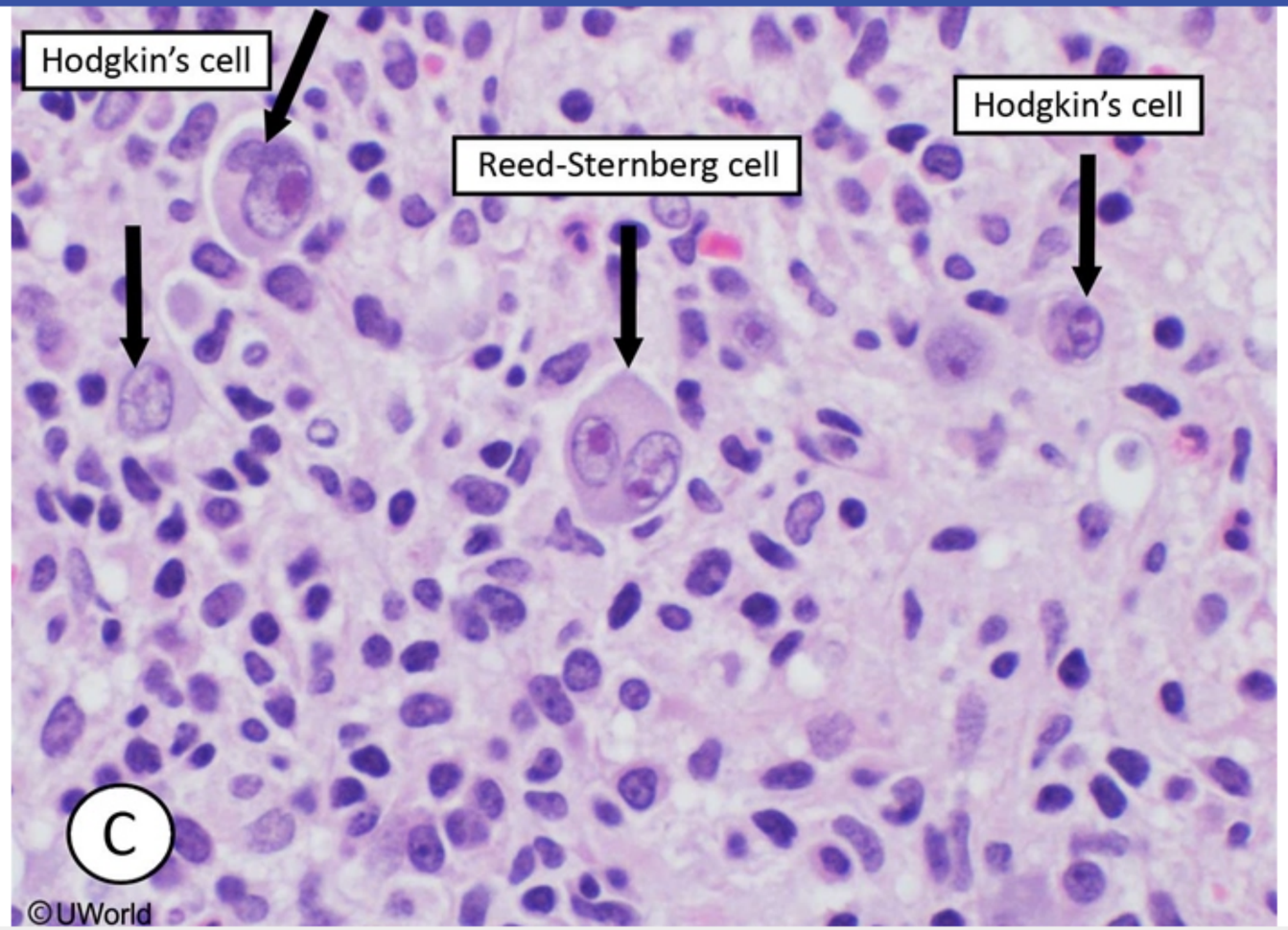

Zoom In | Zoom Out | Reset | Add To New Card | Existing Card

References

Block Time Remaining: 00:00:49
TUTOR

5 | Feedback | Suspend | End Block

Settings

1
2
3
4
5
6
7
8
9
10
11
12
13
14
15
16
17
18
19
20
21
22
23
24
25
26
27
28
29
30

Item 4 of 32
Question Id: 127

Mark | Previous | Next | Full Screen | Tutorial | Lab Values | Notes | Calculator | Reverse Color | Text Zoom | Settings

Exhibit Display

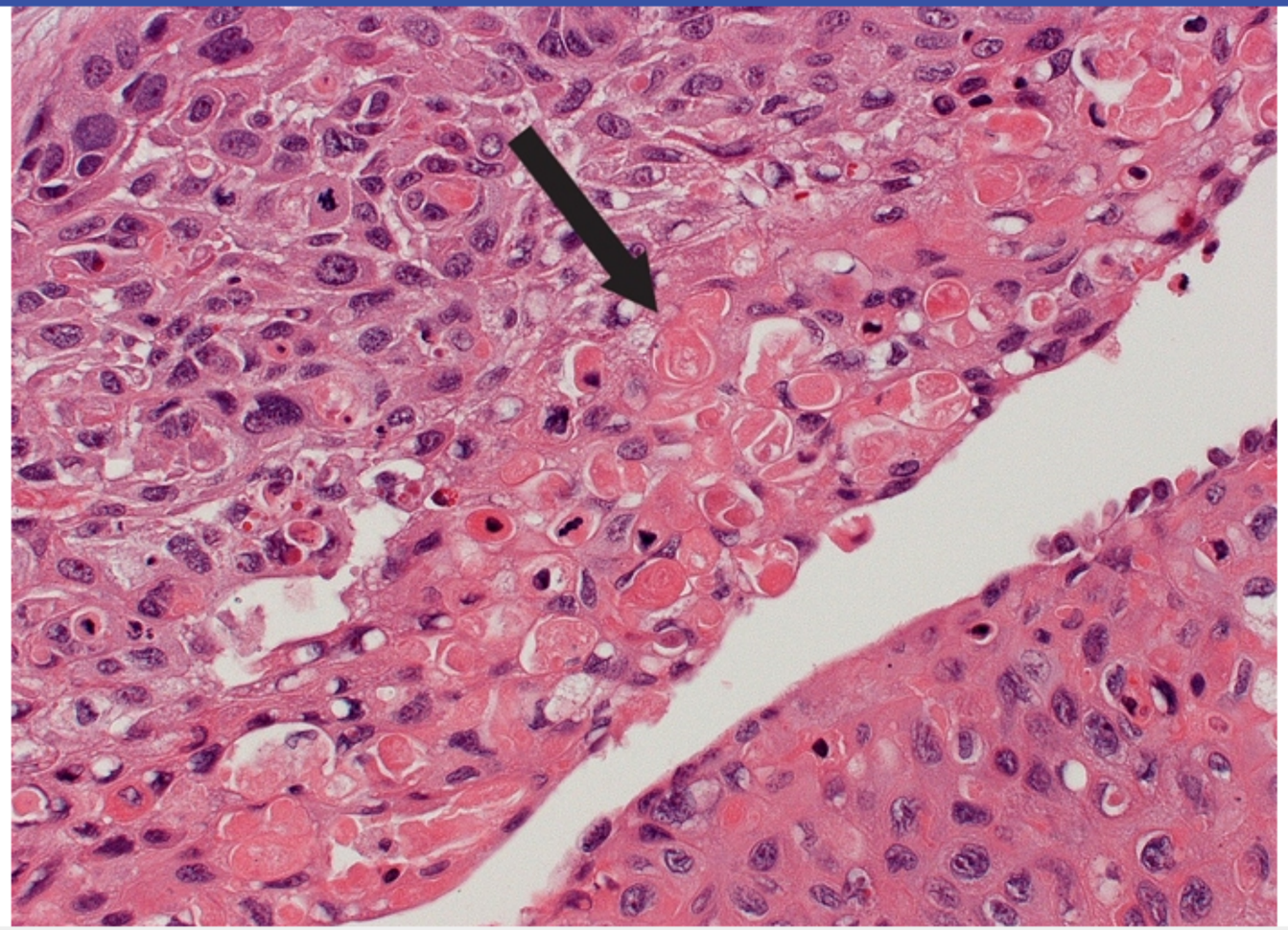

Zoom In | Zoom Out | Reset | Add To New Card | Existing Card

References

Block Time Remaining: 00:00:49
TUTOR

5 | Feedback | Suspend | End Block

Settings

1
2
3
4
5
6
7
8
9
10
11
12
13
14
15
16
17
18
19
20
21
22
23
24
25
26
27
28
29
30

Item 4 of 32
Question Id: 127

Mark | Previous | Next | Full Screen | Tutorial | Lab Values | Notes | Calculator | Reverse Color | Text Zoom | Settings

Exhibit Display

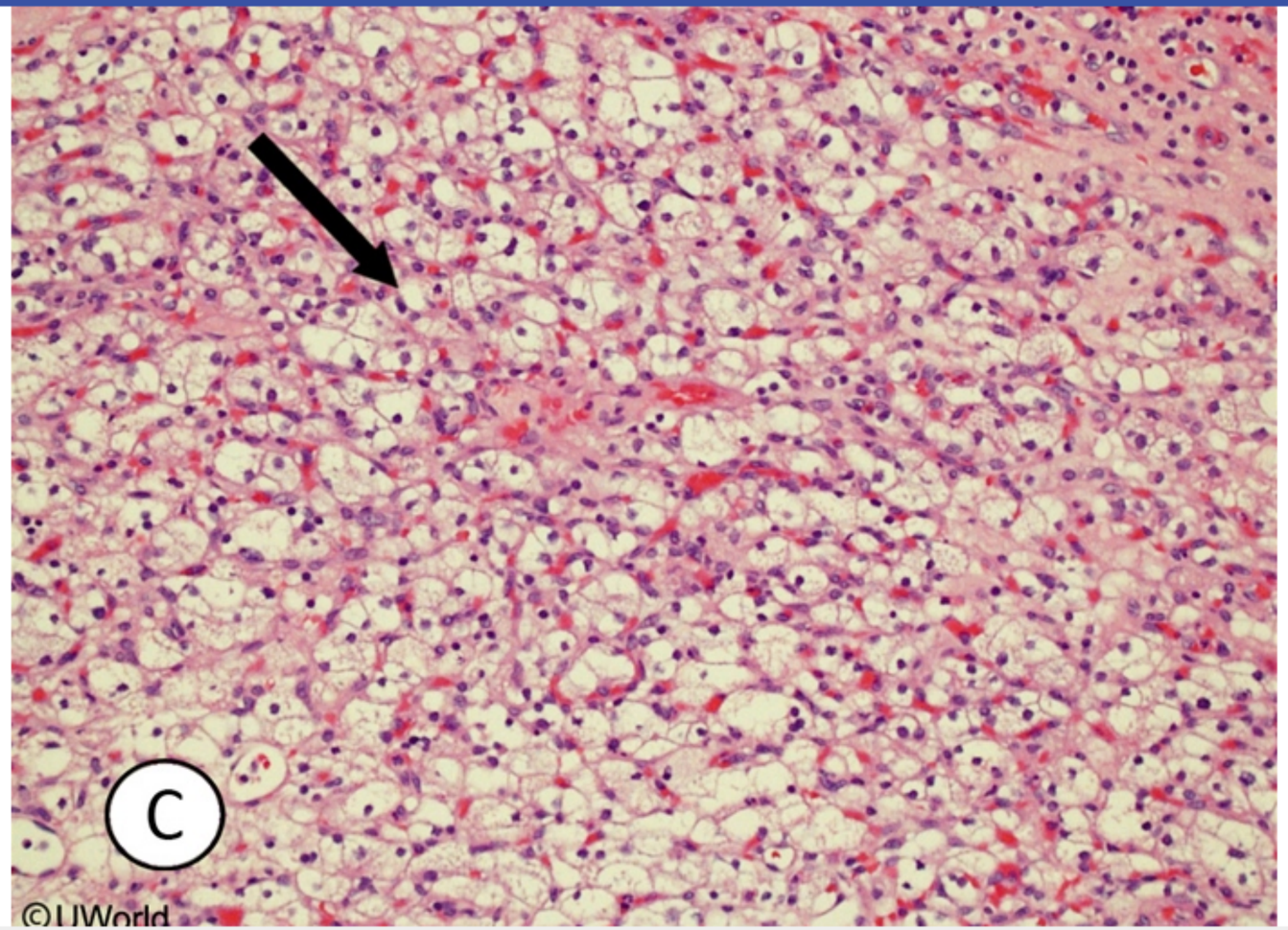

Zoom In | Zoom Out | Reset | Add To New Card | Existing Card

References

Block Time Remaining: 00:00:49
TUTOR

5 | Feedback | Suspend | End Block

Settings

1
2
3
4
5
6
7
8
9
10
11
12
13
14
15
16
17
18
19
20
21
22
23
24
25
26
27
28
29
30

Item 4 of 32
Question Id: 127

Mark | Previous | Next | Full Screen | Tutorial | Lab Values | Notes | Calculator | Reverse Color | Text Zoom | Settings

Exhibit Display

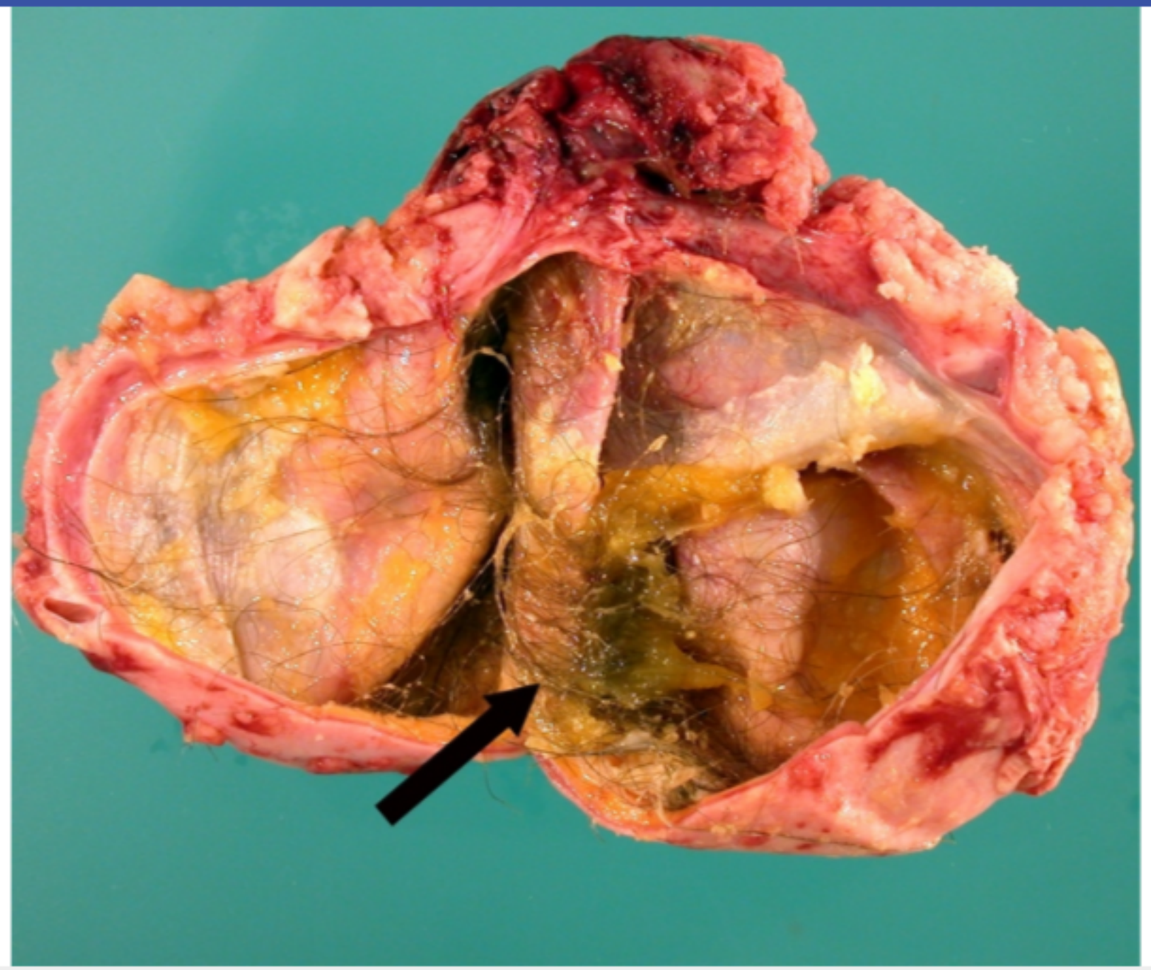

Zoom In | Zoom Out | Reset | Add To New Card | Existing Card

References

Block Time Remaining: 00:00:49
TUTOR

5 | Feedback | Suspend | End Block

A 13-year-old boy is brought to the office for a new patient visit. The patient recently immigrated to the United States with his family. He has no history of significant illness, trauma, or surgery. Physical examination shows Tanner stage IV genitalia but an empty right scrotal sac. A round mass can be palpated in the right inguinal canal. Biopsy of the mass shows marked fibrotic changes with prominent Leydig cells and hypoplastic Sertoli cells. The patient's parents are advised that the mass should be removed. Which of the following is the most likely explanation for the need for surgery in this patient?

A. Maintain adequate function of the contralateral organ

B. Preserve virilization

C. Prevent recurrent infections

D. Reduce the risk of future infertility

E. Reduce the risk of malignancy

Submit

A 13-year-old boy is brought to the office for a new patient visit. The patient recently immigrated to the United States with his family. He has no history of significant illness, trauma, or surgery. Physical examination shows Tanner stage IV genitalia but an empty right scrotal sac. A round mass can be palpated in the right inguinal canal. Biopsy of the mass shows marked fibrotic changes with prominent Leydig cells and hypoplastic Sertoli cells. The patient's parents are advised that the mass should be removed. Which of the following is the most likely explanation for the need for surgery in this patient?

- A. Maintain adequate function of the contralateral organ (1%)
- B. Preserve virilization (1%)
- C. Prevent recurrent infections (1%)
- D. Reduce the risk of future infertility (6%)
- ✓ E. Reduce the risk of malignancy (89%)

Omitted
Correct answer
E

89%
Answered correctly

03 secs
Time Spent

04/16/2020
Last Updated

Explanation

Cryptorchidism	
Clinical features	• Empty scrotum or hemiscrotum

Cryptorchidism	
Clinical features	• Empty scrotum or hemiscrotum • +/– Mass in inguinal canal
Treatment	• Orchiopexy before age 1
Complications	• Decreased fertility • Testicular cancer • Testicular torsion

©UWorld

This patient has an undescended testis, or **cryptorchidism**. Embryologically, the testes originate within the abdomen and then migrate to the scrotal sac via the inguinal canal. The cause of cryptorchidism is poorly understood in most cases. Undescended testes may be unilateral or bilateral and can lie anywhere along the path from the abdomen to the scrotal sac. The temperature inside the scrotal sac is lower than normal body temperature, creating an ideal environment for sperm production. The **seminiferous tubules** and the Sertoli cells within them are very temperature-sensitive and prone to heat-induced damage.

If uncorrected, cryptorchidism leads to atrophy and necrosis of the seminiferous tubules, resulting in **decreased fertility**. Patients with cryptorchidism are at increased risk for **testicular cancer**. Orchiopexy (moving the testes into the scrotal sac) reduces but does not eliminate the risk of malignancy and is most effective when performed between age 6 months and 1 year.

(Choice A) In unilateral cryptorchidism, the contralateral testis functions normally and is not at increased risk for malignancy or torsion.

(Choice B) Unlike the seminiferous tubules, the testosterone-producing Leydig cells are not very sensitive to temperature. Testosterone levels and virilization are usually normal.

(Choice C) No increased risk for testicular or genitourinary tract infection is found with cryptorchidism.

(Choice D) Orchiopexy before age 1-2 may provide some advantage to future fertility. Beyond age 2, no evidence demonstrates that orchiopexy

bilateral and can lie anywhere along the path from the abdomen to the scrotal sac. The temperature inside the scrotal sac is lower than normal body temperature, creating an ideal environment for sperm production. The **seminiferous tubules** and the Sertoli cells within them are very temperature-sensitive and prone to heat-induced damage.

If uncorrected, cryptorchidism leads to atrophy and necrosis of the seminiferous tubules, resulting in **decreased fertility**. Patients with cryptorchidism are at increased risk for **testicular cancer**. Orchiopexy (moving the testes into the scrotal sac) reduces but does not eliminate the risk of malignancy and is most effective when performed between age 6 months and 1 year.

(Choice A) In unilateral cryptorchidism, the contralateral testis functions normally and is not at increased risk for malignancy or torsion.

(Choice B) Unlike the seminiferous tubules, the testosterone-producing Leydig cells are not very sensitive to temperature. Testosterone levels and virilization are usually normal.

(Choice C) No increased risk for testicular or genitourinary tract infection is found with cryptorchidism.

(Choice D) Orchiopexy before age 1-2 may provide some advantage to future fertility. Beyond age 2, no evidence demonstrates that orchiopexy can preserve sperm count in the undescended testis.

Educational objective:
In undescended testes, the seminiferous tubules atrophy if uncorrected due to higher body temperatures, resulting in decreased fertility and increased risk for malignancy. Orchiopexy (surgical placement of the testes in the scrotal sac) can minimize damage and decrease risk for testicular cancer.

References

- The undescended testis: diagnosis, treatment and long-term consequences.

Pathology	Male Reproductive System	Cryptorchidism
Subject	System	Topic

Copyright © UWorld. All rights reserved.

A 28-year-old man comes to the office due to a bump on his right testicle. The patient is otherwise asymptomatic and healthy. Vital signs are normal. A solid mass is palpated in the right testicle. The rest of the examination is unremarkable. A scrotal ultrasound reveals a suspicious, partially necrotic mass. Serum lactate dehydrogenase and alpha-fetoprotein levels are markedly elevated. The patient undergoes a right radical inguinal orchiectomy. Which of the following is the most likely histologic diagnosis?

- A. Leydig cell tumor
- B. Nonseminomatous germ cell tumor
- C. Sertoli cell tumor
- D. Teratoma
- E. Testicular lymphoma

Submit

A 28-year-old man comes to the office due to a bump on his right testicle. The patient is otherwise asymptomatic and healthy. Vital signs are normal. A solid mass is palpated in the right testicle. The rest of the examination is unremarkable. A scrotal ultrasound reveals a suspicious, partially necrotic mass. Serum lactate dehydrogenase and alpha-fetoprotein levels are markedly elevated. The patient undergoes a right radical inguinal orchiectomy. Which of the following is the most likely histologic diagnosis?

- A. Leydig cell tumor (4%)
- ✓ B. Nonseminomatous germ cell tumor (79%)
- C. Sertoli cell tumor (6%)
- D. Teratoma (9%)
- E. Testicular lymphoma (1%)

Omitted
Correct answer
B

79%
Answered correctly

02 secs
Time Spent

03/30/2020
Last Updated

Explanation

Testicular cancer	
Epidemiology	• Age 15-35 • Risk factors: family history, cryptorchidism
	• Germ cell tumors (95%): seminomatous or nonseminomatous (embryonal carcinoma, yolk sac, choriocarcinoma,

Testicular cancer	
Epidemiology	• Age 15-35 • Risk factors: family history, cryptorchidism
Types	• Germ cell tumors (95%): seminomatous or nonseminomatous (embryonal carcinoma, yolk sac, choriocarcinoma, teratoma, mixed) • Sex cord–stromal tumors: Sertoli cell, Leydig cell
Manifestations	• Unilateral, painless testicular mass • Dull ache in lower abdomen
Diagnosis	• Examination: firm, ovoid mass • Elevated tumor markers (AFP, β-hCG, LDH) • Scrotal ultrasound

AFP = alpha-fetoprotein; **LDH** = lactate dehydrogenase.

This patient's painless testicular lesion, necrotic mass on ultrasound, and elevated serum alpha-fetoprotein (AFP) level raises strong suspicion for **testicular cancer**, the most common solid organ malignancy in men age 15-35. Most cases (>95%) arise from pluripotent germ cells that normally differentiate into sperm (**germ-cell tumors**), which are categorized as follows:

- **Non-seminomatous germ cell tumors** (NSGCT) contain undifferentiated or partially differentiated germ cells (eg, embryonal carcinoma, yolk sac tumor, choriocarcinoma). They often generate abnormal hormones (human chorionic growth [**hCG**] hormone) or proteins (**AFP**) that can be measured in the blood to aid diagnosis and evaluate for recurrence following treatment.
- Seminomas contain large uniform germ cells that retain the phenotypic features of spermatogonia. They do not produce AFP but some seminomas secrete limited quantities of hCG.

Lactate dehydrogenase (LDH), a marker of tissue injury and cell turnover, is also often elevated in patients with germ cell tumors but is less

- **Non-seminomatous germ cell tumors** (NSGCT) contain undifferentiated or partially differentiated germ cells (eg, embryonal carcinoma, yolk sac tumor, choriocarcinoma). They often generate abnormal hormones (human chorionic growth [**hCG**] hormone) or proteins (**AFP**) that can be measured in the blood to aid diagnosis and evaluate for recurrence following treatment.
- Seminomas contain large uniform germ cells that retain the phenotypic features of spermatogonia. They do not produce AFP but some seminomas secrete limited quantities of hCG.

Lactate dehydrogenase (LDH), a marker of tissue injury and cell turnover, is also often elevated in patients with germ cell tumors but is less sensitive and specific than hCG or AFP.

(Choice A) Leydig cells secrete testosterone and are found in the testicular stroma. Leydig cell tumors often produce estrogen or testosterone, leading to feminization (eg, gynecomastia) or precocious puberty, respectively. They do not generate AFP or hCG.

(Choice C) Sertoli cells nourish sperm and secrete inhibin, which moderates pituitary gonadotropin release. Sertoli cell tumors are sometimes associated with the excessive production of estrogen but do not typically elevate AFP.

(Choice D) Teratomas are terminally differentiated germ cells that may contain skin or gastrointestinal epithelium, cartilage, and/or neuronal tissue. They are often malignant in adults and may be part of some nonseminomatous germ cell tumors. However, terminally differentiated cells are not generally able to produce AFP or hCG; therefore, these tumor markers are usually not elevated.

(Choice E) Primary testicular lymphoma is uncommon and usually occurs in men age >60. Although lymphoma can be associated with elevated LDH, AFP is almost always normal.

Educational objective:
Most cases of testicular cancer are either seminomatous or nonseminomatous germ cell tumors. Nonseminomatous germ cell tumors are composed of partially differentiated germ cells, which often retain the ability to secrete human chorionic growth hormone and alpha-fetoprotein (serum tumor markers). Serum lactate dehydrogenase, a marker of tissue injury and cell turnover, is also frequently increased.

References

- The present and future of serum diagnostic tests for testicular germ cell tumours.

seminomas secrete limited quantities of hCG.

Lactate dehydrogenase (LDH), a marker of tissue injury and cell turnover, is also often elevated in patients with germ cell tumors but is less sensitive and specific than hCG or AFP.

(Choice A) Leydig cells secrete testosterone and are found in the testicular stroma. Leydig cell tumors often produce estrogen or testosterone, leading to feminization (eg, gynecomastia) or precocious puberty, respectively. They do not generate AFP or hCG.

(Choice C) Sertoli cells nourish sperm and secrete inhibin, which moderates pituitary gonadotropin release. Sertoli cell tumors are sometimes associated with the excessive production of estrogen but do not typically elevate AFP.

(Choice D) Teratomas are terminally differentiated germ cells that may contain skin or gastrointestinal epithelium, cartilage, and/or neuronal tissue. They are often malignant in adults and may be part of some nonseminomatous germ cell tumors. However, terminally differentiated cells are not generally able to produce AFP or hCG; therefore, these tumor markers are usually not elevated.

(Choice E) Primary testicular lymphoma is uncommon and usually occurs in men age >60. Although lymphoma can be associated with elevated LDH, AFP is almost always normal.

Educational objective:
Most cases of testicular cancer are either seminomatous or nonseminomatous germ cell tumors. Nonseminomatous germ cell tumors are composed of partially differentiated germ cells, which often retain the ability to secrete human chorionic growth hormone and alpha-fetoprotein (serum tumor markers). Serum lactate dehydrogenase, a marker of tissue injury and cell turnover, is also frequently increased.

References

- The present and future of serum diagnostic tests for testicular germ cell tumours.

Pathology	Male Reproductive System	Testicular cancer
Subject	System	Topic

Copyright © UWorld. All rights reserved.

An 18-year-old man comes to the office due to a mass in his left scrotum. He has no other symptoms. The patient plays basketball regularly but does not recall any recent trauma to the testicle. He is sexually active with 2 partners and does not use condoms. Vital signs are within normal limits. Physical examination shows a left intrascrotal nodule that is difficult to distinguish from the left testis. The mass is nontender, does not change in size upon supine positioning, and does not transilluminate. There is no inguinal lymphadenopathy. Which of the following is the most likely diagnosis?

- A. Epididymitis
- B. Hydrocele
- C. Syphilitic gumma
- D. Testicular cancer
- E. Testicular hematoma
- F. Varicocele

Submit

An 18-year-old man comes to the office due to a mass in his left scrotum. He has no other symptoms. The patient plays basketball regularly but does not recall any recent trauma to the testicle. He is sexually active with 2 partners and does not use condoms. Vital signs are within normal limits. Physical examination shows a left intrascrotal nodule that is difficult to distinguish from the left testis. The mass is nontender, does not change in size upon supine positioning, and does not transilluminate. There is no inguinal lymphadenopathy. Which of the following is the most likely diagnosis?

- A. Epididymitis (13%)
- B. Hydrocele (0%)
- C. Syphilitic gumma (7%)
- ✓ D. Testicular cancer (64%)
- E. Testicular hematoma (6%)
- F. Varicocele (7%)

Omitted
Correct answer
D

64%
Answered correctly

02 secs
Time Spent

03/30/2020
Last Updated

Explanation

Testicular cancer	
	• Age 15-35

Testicular cancer	
Epidemiology	• Age 15-35 • Risk factors: family history, cryptorchidism
Types	• Germ cell tumors (95%): seminomatous or nonseminomatous (embryonal carcinoma, yolk sac, choriocarcinoma, teratoma, mixed) • Sex cord–stromal tumors: Sertoli cell, Leydig cell
Manifestations	• Unilateral, painless testicular mass • Dull ache in lower abdomen
Diagnosis	• Examination: firm, ovoid mass • Elevated tumor markers (AFP, β-hCG, LDH) • Scrotal ultrasound

AFP = alpha-fetoprotein; **LDH** = lactate dehydrogenase.

The presence of a **painless, solid testicular mass** should always be considered **testicular cancer** until proven otherwise. Most cases present with a nodule or solid swelling in one testicle, which is often initially noticed by a partner or after a minor trauma. Bimanual examination of scrotal contents generally reveals a firm, hard, or fixed **nodule** within the tunica albuginea (fibrous covering of testes) that is ovoid in shape and painless to palpation. Because light does not penetrate solid tumors, testicular cancer does not transilluminate (unlike fluid-filled hydroceles) **(Choice B)**. Bilateral scrotal ultrasound and serum tumor markers (eg, alpha-fetoprotein, beta human chorionic growth hormone) are usually obtained next to aid diagnosis.

Most testicular tumors arise in young men (age 15-35) and are derived from a pluripotent testicular germ cell; these testicular **germ cell tumors** are generally curable with surgery and (when needed) chemotherapy.

(Choice A) Epididymitis is common in young, sexually active men and is usually due to a sexually transmitted infection (eg, *Chlamydia trachomatis*, *Neisseria gonorrhoeae*). However, most cases are quite painful, and careful examination usually shows swelling adjacent to, rather than within, the testis.

AFP = alpha-fetoprotein; LDH = lactate dehydrogenase.

The presence of a **painless, solid testicular mass** should always be considered **testicular cancer** until proven otherwise. Most cases present with a nodule or solid swelling in one testicle, which is often initially noticed by a partner or after a minor trauma. Bimanual examination of scrotal contents generally reveals a firm, hard, or fixed **nodule** within the tunica albuginea (fibrous covering of testes) that is ovoid in shape and painless to palpation. Because light does not penetrate solid tumors, testicular cancer does not transilluminate (unlike fluid-filled hydroceles) **(Choice B)**. Bilateral scrotal ultrasound and serum tumor markers (eg, alpha-fetoprotein, beta human chorionic growth hormone) are usually obtained next to aid diagnosis.

Most testicular tumors arise in young men (age 15-35) and are derived from a pluripotent testicular germ cell; these testicular **germ cell tumors** are generally curable with surgery and (when needed) chemotherapy.

(Choice A) Epididymitis is common in young, sexually active men and is usually due to a sexually transmitted infection (eg, *Chlamydia trachomatis*, *Neisseria gonorrhoeae*). However, most cases are quite painful, and careful examination usually shows swelling adjacent to, rather than within, the testis.

(Choice C) Syphilitic gummas are a manifestation of tertiary syphilis that can develop many years after initial infection in untreated patients. They generally present with painless, white-gray lesions on the skin that may ulcerate; testicular gummas (syphilitic orchitis) are rare and usually associated with pain and fever.

(Choice E) Testicular hematoma usually occurs after scrotal trauma and generally presents with significant testicular pain and tenderness to palpation.

(Choice F) Varicoceles are due to venous dilation in the pampiniform plexus. They can present with painless testicular swelling but characteristically feel like a "bag of worms" on physical examination. Most decompress with recumbency and grow in size with standing.

Educational objective:
A painless, solid scrotal mass should be considered testicular cancer until proven otherwise. Examination generally reveals a solid, firm, or fixed nodule in the tunica albuginea that is ovoid in shape and painless to palpation. Testicular tumors do not transilluminate.

Pathology Male Reproductive System Testicular cancer

contents generally reveals a firm, hard, or fixed **nodule** within the tunica albuginea (fibrous covering of testes) that is ovoid in shape and painless to palpation. Because light does not penetrate solid tumors, testicular cancer does not transilluminate (unlike fluid-filled hydroceles) **(Choice B)**. Bilateral scrotal ultrasound and serum tumor markers (eg, alpha-fetoprotein, beta human chorionic growth hormone) are usually obtained next to aid diagnosis.

Most testicular tumors arise in young men (age 15-35) and are derived from a pluripotent testicular germ cell; these testicular **germ cell tumors** are generally curable with surgery and (when needed) chemotherapy.

(Choice A) Epididymitis is common in young, sexually active men and is usually due to a sexually transmitted infection (eg, *Chlamydia trachomatis*, *Neisseria gonorrhoeae*). However, most cases are quite painful, and careful examination usually shows swelling adjacent to, rather than within, the testis.

(Choice C) Syphilitic gummas are a manifestation of tertiary syphilis that can develop many years after initial infection in untreated patients. They generally present with painless, white-gray lesions on the skin that may ulcerate; testicular gummas (syphilitic orchitis) are rare and usually associated with pain and fever.

(Choice E) Testicular hematoma usually occurs after scrotal trauma and generally presents with significant testicular pain and tenderness to palpation.

(Choice F) Varicoceles are due to venous dilation in the pampiniform plexus. They can present with painless testicular swelling but characteristically feel like a "bag of worms" on physical examination. Most decompress with recumbency and grow in size with standing.

Educational objective:
A painless, solid scrotal mass should be considered testicular cancer until proven otherwise. Examination generally reveals a solid, firm, or fixed nodule in the tunica albuginea that is ovoid in shape and painless to palpation. Testicular tumors do not transilluminate.

Pathology	Male Reproductive System	Testicular cancer
Subject	System	Topic

Copyright © UWorld. All rights reserved.

contents generally reveals a firm, hard, or fixed **nodule** within the tunica albuginea (fibrous covering of testes) that is ovoid in shape and painless

Exhibit Display

Varicocele

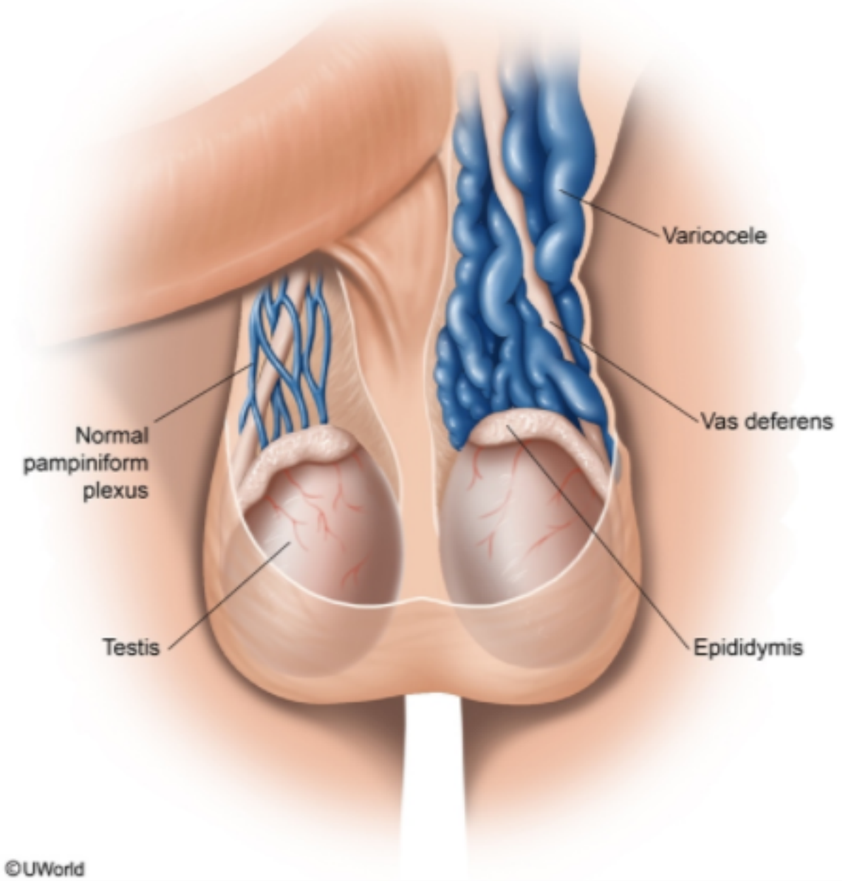

Zoom In | Zoom Out | Reset | Add To New Card | Existing Card

A 16-year-old boy comes to the office due to 2 days of right testicular pain. The pain is constant and exacerbated by movement. Vital signs are within normal limits. On physical examination, there is swelling and tenderness to palpation localized to the posterior and superior areas of the right testis. The left testis is normal. Cremasteric reflexes are normal bilaterally. Urinalysis shows numerous leukocytes but no bacteria. Which of the following factors most likely contributed to this patient's current condition?

- A. Inadequate childhood vaccination
- B. Increased gonadal venous pressure
- C. Lack of normal testicular fixation
- D. Unprotected sexual intercourse
- E. Urethral colonization by coliforms

Submit

A 16-year-old boy comes to the office due to 2 days of right testicular pain. The pain is constant and exacerbated by movement. Vital signs are within normal limits. On physical examination, there is swelling and tenderness to palpation localized to the posterior and superior areas of the right testis. The left testis is normal. Cremasteric reflexes are normal bilaterally. Urinalysis shows numerous leukocytes but no bacteria. Which of the following factors most likely contributed to this patient's current condition?

- A. Inadequate childhood vaccination (29%)
- B. Increased gonadal venous pressure (14%)
- C. Lack of normal testicular fixation (15%)
- ✓ D. Unprotected sexual intercourse (36%)
- E. Urethral colonization by coliforms (4%)

Omitted
Correct answer
D

36%
Answered correctly

02 secs
Time Spent

03/08/2020
Last Updated

Explanation

Acute epididymitis	
Epidemiology	• Age <35: **sexually transmitted** (chlamydia, gonorrhea) • Age >35: bladder outlet obstruction (**coliform bacteria**)
	• Unilateral testicular **pain**

Acute epididymitis	
Epidemiology	• Age <35: **sexually transmitted** (chlamydia, gonorrhea) • Age >35: bladder outlet obstruction (**coliform bacteria**)
Symptoms	• Unilateral testicular **pain** • Epididymal **edema** • Dysuria, frequency (with coliform infection)
Diagnosis	• **NAAT** for chlamydia and gonorrhea • **Urinalysis**/culture

NAAT = nucleic acid amplification test; **STI** = sexually transmitted infection.

This patient's acute testicular pain, **posterior testicle tenderness**, and pyuria raise strong suspicion for **acute epididymitis**. Most cases occur when genitourinary pathogens travel in a retrograde fashion from the urethra via the ejaculatory duct to the vas deferens. The most likely underlying organism can often be inferred based upon the age of the patient, as follows:

- Young men (age <35) usually develop acute epididymitis due to ***Chlamydia trachomatis*** or ***Neisseria gonorrhoeae***, sexually transmitted pathogens acquired during **unprotected sexual intercourse**. Although these organisms often cause asymptomatic urethritis (no dysuria), pyuria is typically seen on urinalysis. Nucleic acid amplification testing is required for diagnosis because urine culture is generally negative.
- Older men (age >35) are less likely to have sexually transmitted infections due to fewer sexual partners and increased rates of monogamy. Acute epididymitis in these patients is generally due to gram-negative colonic flora (eg, *Escherichia coli*), which contaminate the urethra, ascend into the urinary system, and subsequently invade the ejaculatory duct and vas deferens. Most cases arise in the setting of urethral obstruction (eg, benign prostatic hypertrophy) and are characterized by urinary tract symptoms (eg, dysuria, urinary frequency), bacteruria on urinalysis, and positive urine culture **(Choice E)**.

(Choice A) Mumps can occur in those who did not receive appropriate childhood vaccinations and usually presents with a nonspecific prodrome (fever, malaise, myalgias) followed by parotitis. Complications include orchitis, with high fever and severe testicular pain. This patient is afebrile

- Young men (age <35) usually develop acute epididymitis due to ***Chlamydia trachomatis*** or ***Neisseria gonorrhoeae***, sexually transmitted pathogens acquired during **unprotected sexual intercourse**. Although these organisms often cause asymptomatic urethritis (no dysuria), pyuria is typically seen on urinalysis. Nucleic acid amplification testing is required for diagnosis because urine culture is generally negative.
- Older men (age >35) are less likely to have sexually transmitted infections due to fewer sexual partners and increased rates of monogamy. Acute epididymitis in these patients is generally due to gram-negative colonic flora (eg, *Escherichia coli*), which contaminate the urethra, ascend into the urinary system, and subsequently invade the ejaculatory duct and vas deferens. Most cases arise in the setting of urethral obstruction (eg, benign prostatic hypertrophy) and are characterized by urinary tract symptoms (eg, dysuria, urinary frequency), bacteruria on urinalysis, and positive urine culture **(Choice E)**.

(Choice A) Mumps can occur in those who did not receive appropriate childhood vaccinations and usually presents with a nonspecific prodrome (fever, malaise, myalgias) followed by parotitis. Complications include orchitis, with high fever and severe testicular pain. This patient is afebrile and did not have prodromal or parotid symptoms.

(Choice B) Varicocele is characterized by distension of the pampiniform plexus due to elevated gonadal venous pressure. It presents as a soft scrotal mass that feels like a "bag of worms" on palpation. Pain is mild or absent.

(Choice C) Testicular torsion is the result of inadequate fixation of the lower pole of the testis to the tunica vaginalis. It is usually characterized by sudden-onset, severe, unilateral testicular pain; nausea; a high-riding testis; and loss of the cremasteric reflex (elevation of testis on pinching of the skin at the upper thigh).

Educational objective:
Epididymitis presents with acute testicular pain, tenderness, and pyuria. It is caused by retrograde passage of organisms from the urethra into the ejaculatory duct and vas deferens. The microbiology is largely influenced by patient age: epididymitis in young men is usually due to sexually acquired infections (eg, *Chlamydia trachomatis*, *Neisseria gonorrhoeae*), whereas in older men (age >35) it is usually due to gram-negative colonic flora.

References

- Epididymitis: an overview.

A 17-year-old boy is brought to the office for evaluation of bilateral breast enlargement. He first noticed it a few months ago and says that it is slightly painful. His parents are concerned that his breasts are gradually becoming more prominent. The patient is in special education classes due to a long-standing history of learning disabilities. His father has type 2 diabetes mellitus and is on dialysis for chronic renal failure. Height is at the 95th percentile, and weight is at the 25th percentile for age and sex. Symmetrical glandular tissue is palpated under both nipple-areolar complexes. His sense of smell is normal, and his testicles are small and firm. Laboratory evaluation would most likely show which of the following findings?

- A. Decreased estradiol
- B. Increased androstenedione
- C. Increased β-hCG
- D. Increased creatinine
- E. Increased FSH
- F. Increased prolactin
- G. Prolonged prothrombin time

Submit

A 17-year-old boy is brought to the office for evaluation of bilateral breast enlargement. He first noticed it a few months ago and says that it is slightly painful. His parents are concerned that his breasts are gradually becoming more prominent. The patient is in special education classes due to a long-standing history of learning disabilities. His father has type 2 diabetes mellitus and is on dialysis for chronic renal failure. Height is at the 95th percentile, and weight is at the 25th percentile for age and sex. Symmetrical glandular tissue is palpated under both nipple-areolar complexes. His sense of smell is normal, and his testicles are small and firm. Laboratory evaluation would most likely show which of the following findings?

- A. Decreased estradiol (1%)
- B. Increased androstenedione (16%)
- C. Increased β-hCG (1%)
- D. Increased creatinine (0%)
- ✓ E. Increased FSH (62%)
- F. Increased prolactin (16%)
- G. Prolonged prothrombin time (0%)

Omitted
Correct answer
E

62%
Answered correctly

02 secs
Time Spent

04/26/2020
Last Updated

Explanation

Klinefelter syndrome	
Pathogenesis	Nondisjunction of the sex chromosomes, resulting in a 47,XXY male
Clinical features	• Primary hypogonadism • Increased long bone length • Gynecomastia • Learning & socialization difficulties
Laboratory findings	• ↓ Testosterone • ↑ LH & FSH (due to loss of feedback inhibition) • ↑ Estradiol

©UWorld

Klinefelter syndrome (KS) is caused by sex chromosome aneuploidy, which most commonly results in a 47,XXY karyotype. These patients typically have atrophied, hyalinized seminiferous tubules (resulting in low inhibin levels) and damaged Leydig cells (resulting in **low testosterone** levels). The lack of feedback inhibition results in **excess gonadotropins** (increased LH and FSH), which in turn **increase estrogen** levels **(Choice A).**

Primary hypogonadism is the cardinal feature. Phenotypic findings include azoospermia, **small/firm testes**, absent secondary male characteristics (including deep voice, beard, and male-pattern pubic hair), and **tall** stature. **Gynecomastia** is also common and associated with a risk of malignant transformation. Cognitive impairment is characterized by learning and socialization difficulties.

(Choice B) Increased androstenedione levels due to anabolic steroid abuse can cause irreversible gynecomastia and testicular atrophy. Exogenous steroid use can be distinguished from KS by the additional findings of acne, male-pattern baldness, hastened epiphyseal closure (reduced height potential), and aggressive behavior.

Exhibit Display

Gonadotropin regulation

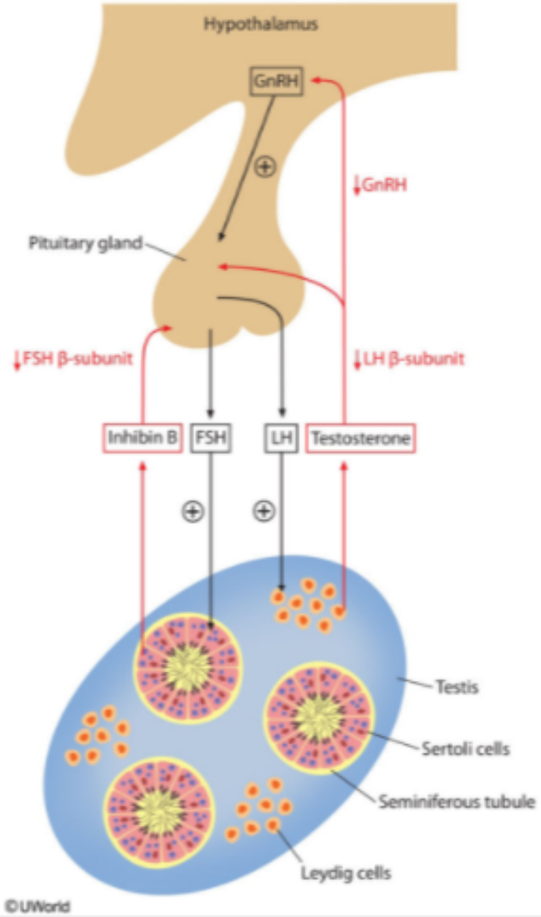

Zoom In | Zoom Out | Reset | Add To New Card | Existing Card

(reduced height potential), and aggressive behavior.

Primary hypogonadism is the cardinal feature. Phenotypic findings include azoospermia, **small/firm testes**, absent secondary male characteristics (including deep voice, beard, and male-pattern pubic hair), and **tall** stature. **Gynecomastia** is also common and associated with a risk of malignant transformation. Cognitive impairment is characterized by learning and socialization difficulties.

(Choice B) Increased androstenedione levels due to anabolic steroid abuse can cause irreversible gynecomastia and testicular atrophy. Exogenous steroid use can be distinguished from KS by the additional findings of acne, male-pattern baldness, hastened epiphyseal closure (reduced height potential), and aggressive behavior.

(Choice C) Testicular germ cell tumors produce excessive β-hCG, resulting in gynecomastia in addition to a firm, rapidly growing testicular mass.

(Choice D) Chronic renal insufficiency is marked by high creatinine and uremia. Uremia is toxic to the testicles and suppresses testosterone production. Renal abnormalities are not a typical feature of KS.

(Choice F) Antipsychotics (eg, haloperidol) can cause hyperprolactinemia, which in turn can induce gynecomastia. Excess prolactin is also secreted from prolactinomas. Prolactin levels are not typically elevated in other causes of gynecomastia.

(Choice G) Gynecomastia is commonly seen in cirrhosis, particularly in the setting of alcohol abuse. The estrogen-to-testosterone ratio is disrupted due to impaired hepatic degradation of estrogens in addition to ethanol's direct inhibition of testosterone production. Patients with cirrhosis are often coagulopathic due to diminished clotting factor production, which results in increased prothrombin time/International Normalized Ratio.

Educational objective:
Patients with Klinefelter syndrome (47,XXY) have primary hypogonadism characterized by low testosterone and elevated gonadotropin (FSH, LH) levels. In addition, elevated estradiol results in the common finding of gynecomastia.

References

- Klinefelter syndrome: the commonest form of hypogonadism, but often overlooked or untreated.
- Phenotypic differences in mosaic Klinefelter patients as compared with non-mosaic Klinefelter patients.
- Clinical review: Klinefelter syndrome--a clinical update.

A 50-year-old woman, gravida 0 para 0, comes to the office for a well visit. She has no family history of cancer. Breast examination is normal. The patient has a screening mammography that reveals microcalcifications. Due to this finding, she undergoes a breast biopsy. Histopathology reveals ducts distended by pleomorphic cells with prominent central necrosis. The lesion does not extend beyond the ductal basal membrane. Which of the following is most likely the origin of the lesion?

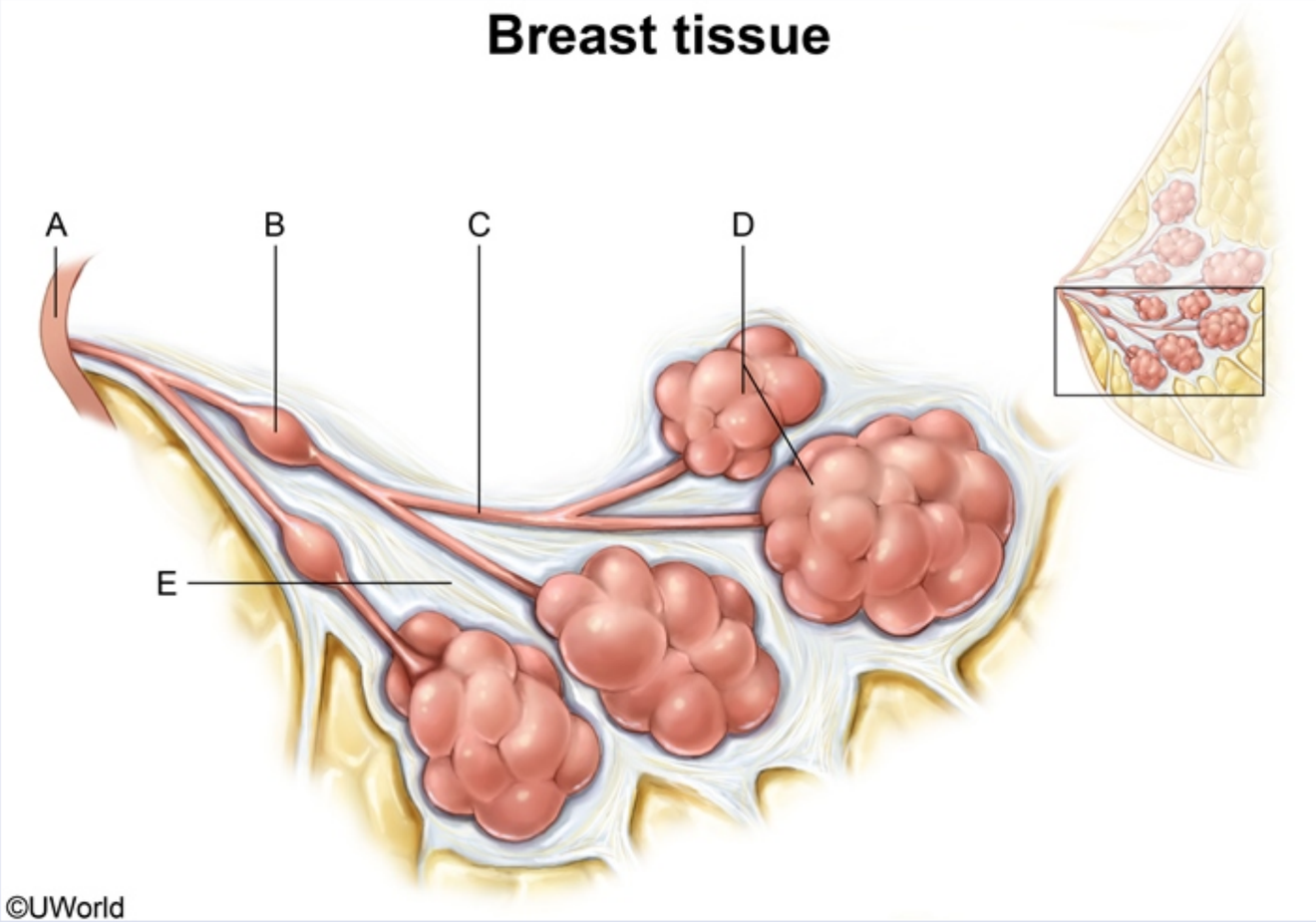

Settings

1 2 3 4 5 6 7 8 9 10 11 12 13 14 15 16 17 18 19 20 21 22 23 24 25 26 27 28 29 30

Item 10 of 32
Question Id: 1057

Mark | Previous | Next | Full Screen | Tutorial | Lab Values | Notes | Calculator | Reverse Color | Text Zoom | Settings

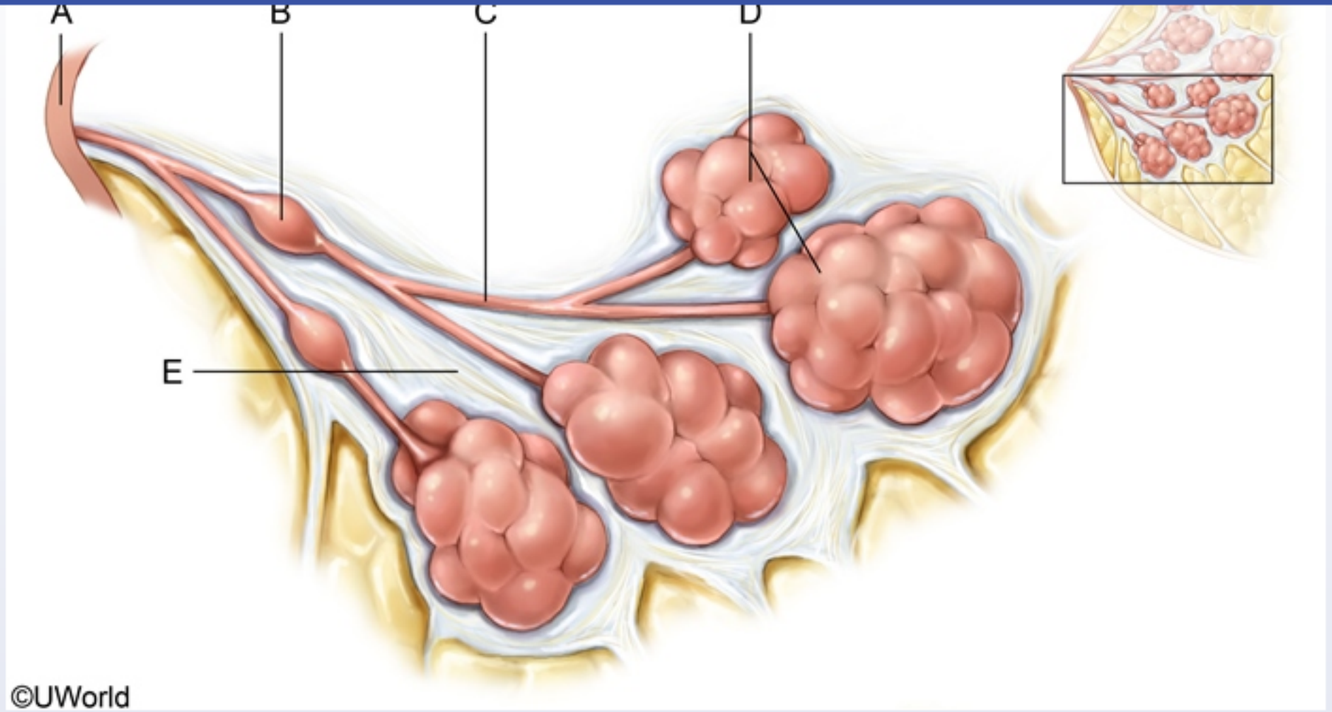

A. A
B. B
C. C
D. D
E. E

Submit

Block Time Remaining: 00:01:02
TUTOR

6 | Feedback | Suspend | End Block

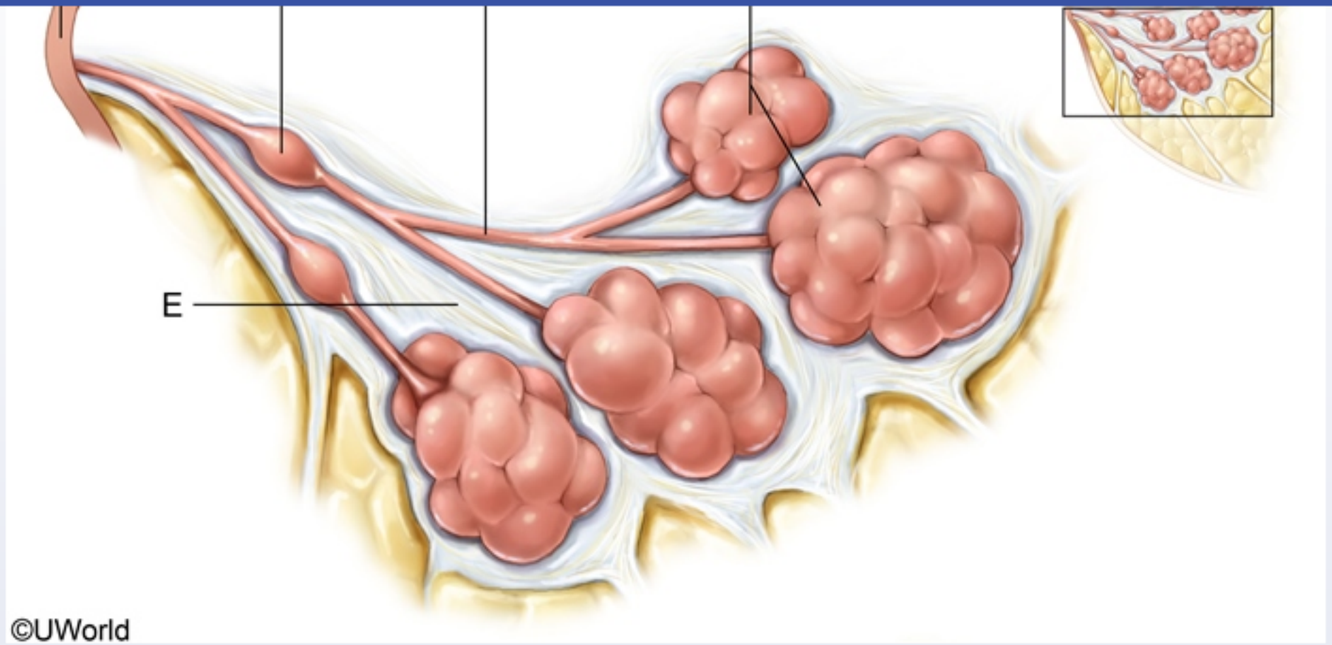

A. A (1%)

B. B (12%)

✓ C. C (68%)

D. D (13%)

E. E (3%)

Omitted
Correct answer

68%
Answered correctly

05 secs
Time Spent

02/18/2020
Last Updated

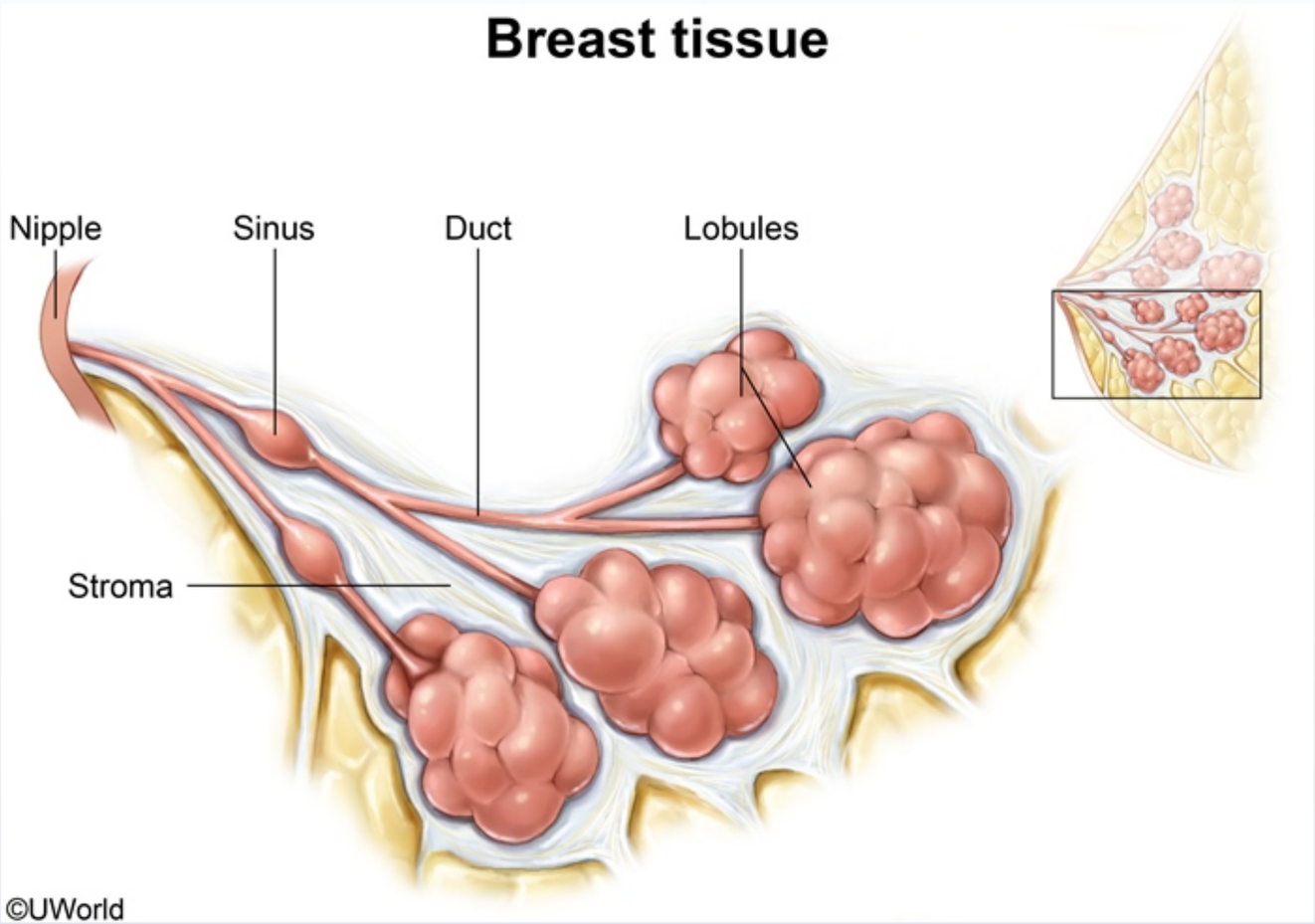

The breast is composed of subcutaneous tissue and breast tissue, the latter of which includes stromal and epithelial elements. Stroma constitutes the majority of breast volume in nonlactating women and consists of fibrous connective tissue. The epithelial elements of breast tissue proliferate during lactation and include branching ducts, which connect the lobules to sinuses that drain to the nipple.

As the name suggests, **ductal carcinoma in situ** (DCIS) arises from the breast ducts. It is a precursor to the most common type of breast cancer, invasive ductal carcinoma. Age and nulliparity are risk factors for breast cancer, and breastfeeding has a protective effect. DCIS is typically

©UWorld

The breast is composed of subcutaneous tissue and breast tissue, the latter of which includes stromal and epithelial elements. Stroma constitutes the majority of breast volume in nonlactating women and consists of fibrous connective tissue. The epithelial elements of breast tissue proliferate during lactation and include branching ducts, which connect the lobules to sinuses that drain to the nipple.

As the name suggests, **ductal carcinoma in situ** (DCIS) arises from the breast ducts. It is a precursor to the most common type of breast cancer, invasive ductal carcinoma. Age and nulliparity are risk factors for breast cancer, and breastfeeding has a protective effect. DCIS is typically identified by biopsy after mammography screening shows **microcalcifications** in asymptomatic patients with normal breast examinations. Histopathology demonstrates ducts (black arrows) distended by pleomorphic cells with prominent **central necrosis** without extension beyond the ductal basement membrane. Spread of these malignant cells to the nipple through the duct system results in eczematous nipple changes and indicates Paget disease **(Choice A)**.

(Choice B) The sinuses serve as collecting reservoirs for milk during lactation. A blockage of this area can cause a galactocele and eventually lead to a breast abscess.

(Choice D) Lobular breast tissue can give rise to lobular breast carcinoma that typically presents as palpable breast masses with orderly rows of cells organized in single file.

(Choice E) Phyllodes tumors arise from the breast stroma and can progress to malignancy. Histology shows disorderly, diffusely hypercellular connective tissue with cellular atypia and leaf-like projections (black arrow).

Educational objective:
Ductal carcinoma in situ is characterized by ducts distended by pleomorphic cells with prominent central necrosis that do not penetrate the basement membrane. It is the precursor to invasive ductal carcinoma, the most common type of breast cancer.

References

- Progression from ductal carcinoma in situ to invasive breast cancer: revisited.

Pathology	Female Reproductive System & Breast	Breast cancer
Subject	System	Topic

Settings

1 2 3 4 5 6 7 8 9 10 11 12 13 14 15 16 17 18 19 20 21 22 23 24 25 26 27 28 29 30

Item 10 of 32
Question Id: 1057

Mark | Previous | Next | Full Screen | Tutorial | Lab Values | Notes | Calculator | Reverse Color | Text Zoom | Settings

©UWorld

Exhibit Display

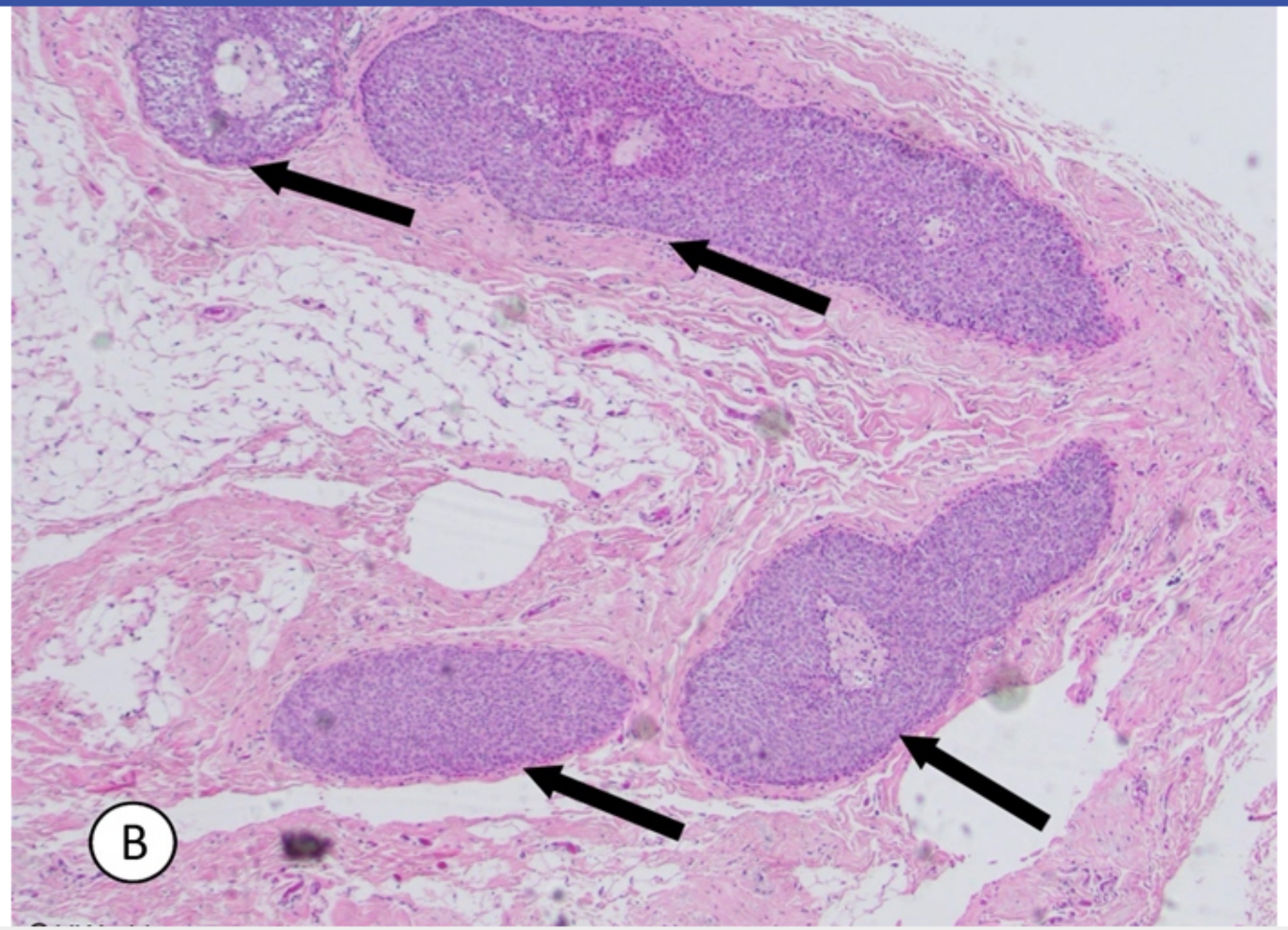

Zoom In | Zoom Out | Reset | Add To New Card | Existing Card

Subject System Topic

Block Time Remaining: 00:01:05
TUTOR

6 | Feedback | Suspend | End Block

Settings

1 2 3 4 5 6 7 8 9 10 11 12 13 14 15 16 17 18 19 20 21 22 23 24 25 26 27 28 29 30

Item 10 of 32
Question Id: 1057

Mark | Previous | Next | Full Screen | Tutorial | Lab Values | Notes | Calculator | Reverse Color | Text Zoom | Settings

©UWorld

Exhibit Display

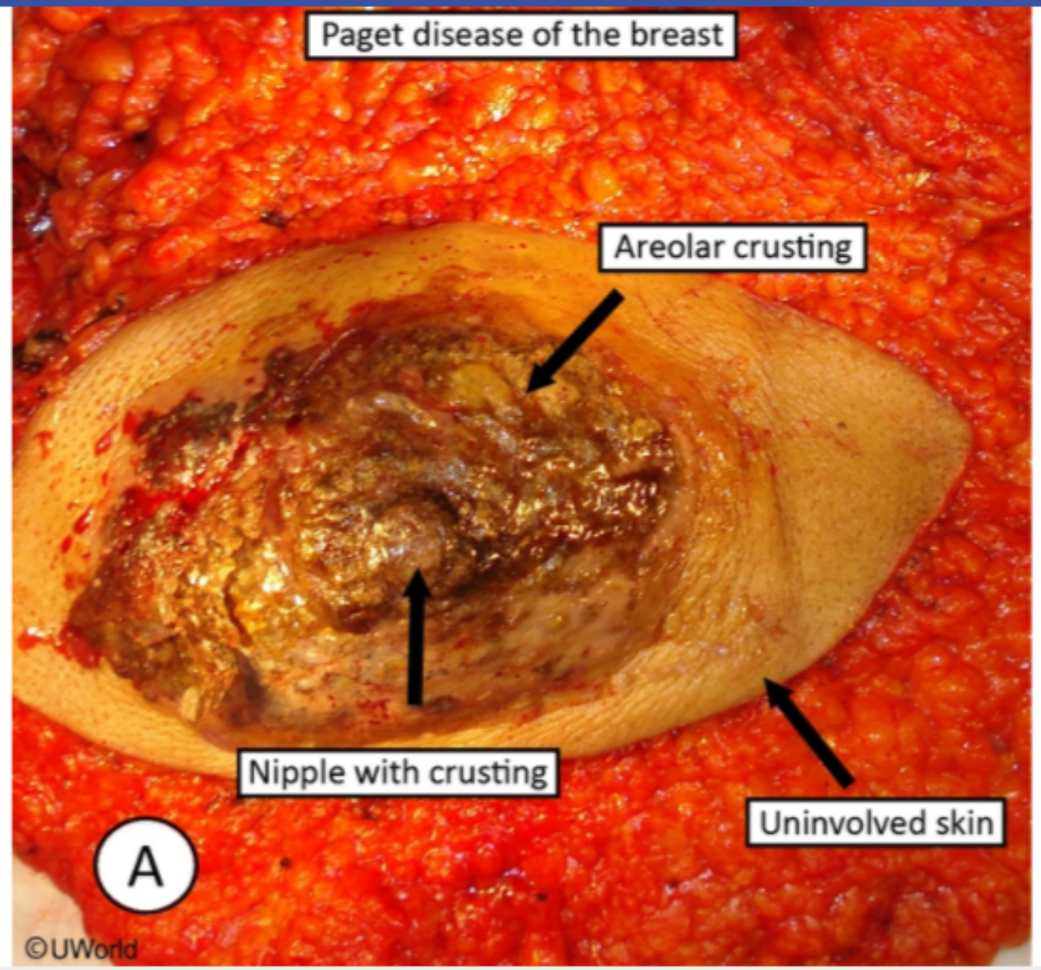

Zoom In | Zoom Out | Reset | Add To New Card | Existing Card

Subject System Topic

Block Time Remaining: 00:01:05
TUTOR

6 | Feedback | Suspend | End Block

Settings

1 2 3 4 5 6 7 8 9 10 11 12 13 14 15 16 17 18 19 20 21 22 23 24 25 26 27 28 29 30

Item 10 of 32
Question Id: 1057

Mark | Previous | Next | Full Screen | Tutorial | Lab Values | Notes | Calculator | Reverse Color | Text Zoom | Settings

©UWorld

Exhibit Display

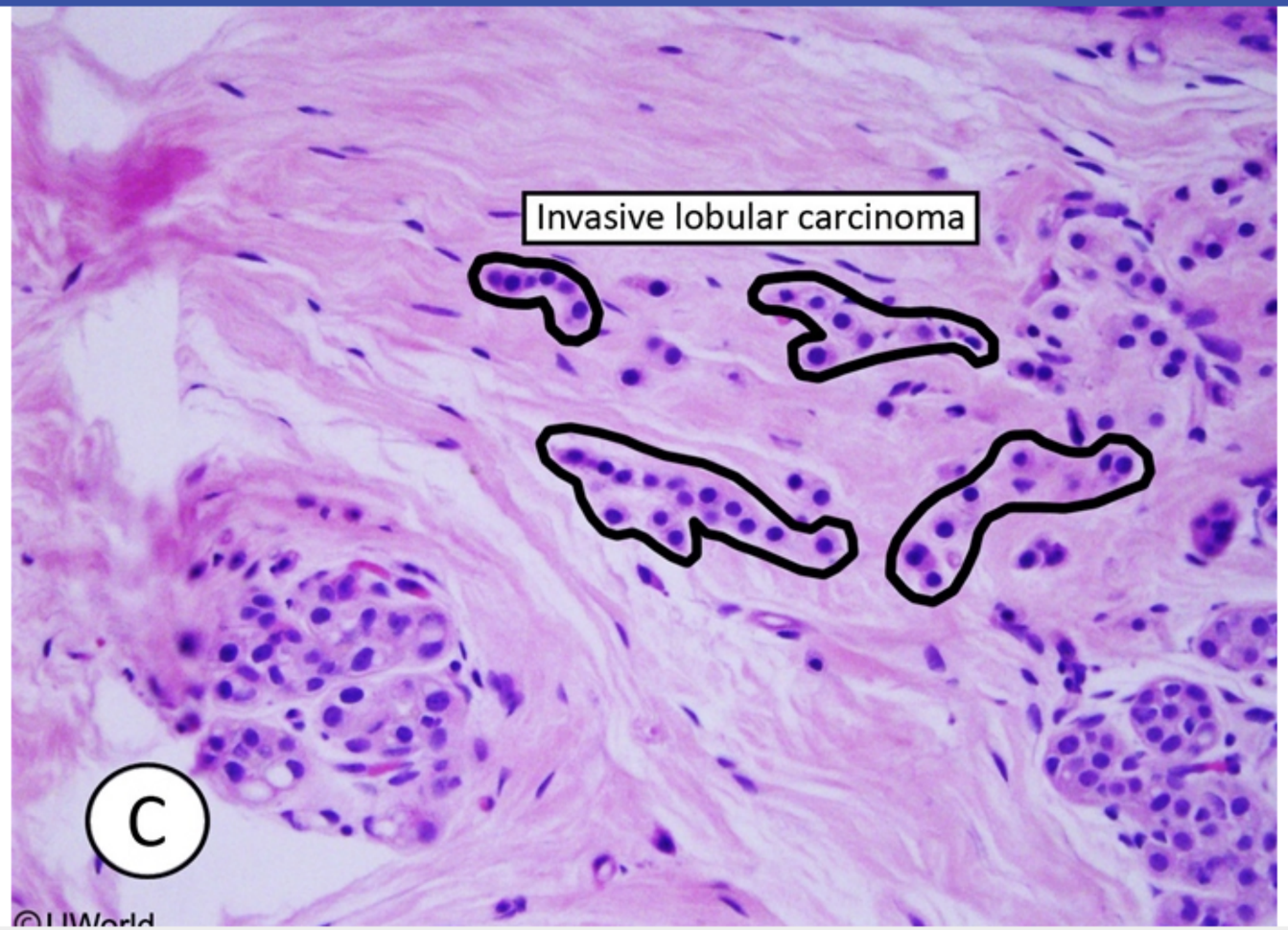

Zoom In | Zoom Out | Reset | Add To New Card | Existing Card

Subject System Topic

Block Time Remaining: 00:01:05
TUTOR

6 | Feedback | Suspend | End Block

Settings

1 2 3 4 5 6 7 8 9 10 11 12 13 14 15 16 17 18 19 20 21 22 23 24 25 26 27 28 29 30

Item 10 of 32
Question Id: 1057

Mark | Previous | Next | Full Screen | Tutorial | Lab Values | Notes | Calculator | Reverse Color | Text Zoom | Settings

©UWorld

Exhibit Display

Zoom In | Zoom Out | Reset | Add To New Card | Existing Card

Subject System Topic

Block Time Remaining: 00:01:05
TUTOR

6 | Feedback | Suspend | End Block

A 27-year-old Caucasian man comes to the physician with his wife for an infertility evaluation. They have been trying to conceive for the last 14 months without success. A semen analysis shows a normal sperm count but completely immobile sperm due to abnormal tail function. Which of the following additional findings is most likely associated with this patient's condition?

- A. Cleft lip
- B. Coarctation of the aorta
- C. Fat malabsorption
- D. Hypertrophic cardiomyopathy
- E. Liver cirrhosis
- F. Persistent bronchial dilation

Submit

A 27-year-old Caucasian man comes to the physician with his wife for an infertility evaluation. They have been trying to conceive for the last 14 months without success. A semen analysis shows a normal sperm count but completely immobile sperm due to abnormal tail function. Which of the following additional findings is most likely associated with this patient's condition?

A. Cleft lip (2%)
B. Coarctation of the aorta (3%)
C. Fat malabsorption (17%)
D. Hypertrophic cardiomyopathy (3%)
E. Liver cirrhosis (1%)
✓ F. Persistent bronchial dilation (72%)

Omitted
Correct answer
F

72%
Answered correctly

02 secs
Time Spent

02/24/2020
Last Updated

Explanation

The finding of **impaired sperm motility** raises concern for **primary ciliary dyskinesia** (PCD), an autosomal recessive condition caused by a variety of mutations in genes responsible for normal flagellar and ciliary function. The clinical manifestations of PCD include:

1. Predisposition to upper and lower respiratory tract infections due to impaired mucociliary clearance. Patients develop chronic cough, **chronic sinusitis**, recurrent otitis media, and bronchiectasis (permanent abnormal airway enlargement).

The finding of **impaired sperm motility** raises concern for **primary ciliary dyskinesia** (PCD), an autosomal recessive condition caused by a variety of mutations in genes responsible for normal flagellar and ciliary function. The clinical manifestations of PCD include:

1. Predisposition to upper and lower respiratory tract infections due to impaired mucociliary clearance. Patients develop chronic cough, **chronic sinusitis**, recurrent otitis media, and bronchiectasis (permanent abnormal airway enlargement).
2. Randomization of left-right body asymmetry; half of all patients have **situs inversus** (reversed right/left positioning of internal organs)
3. **Infertility** due to impaired function of sperm flagella (men) and immobility of fallopian tube cilia (women).

Patients with the triad of situs inversus, chronic sinusitis, and bronchiectasis are said to have **Kartagener syndrome**.

(Choice A) A cleft lip results from failure of the maxillary and medial nasal processes to fuse during development. It is not associated with defects in ciliary structure or function.

(Choice B) Coarctation of the aorta may be seen in Turner (XO) syndrome.

(Choice C) Fat malabsorption can occur in cystic fibrosis due to pancreatic insufficiency. Although male patients with cystic fibrosis are typically infertile, this results from bilateral absence of the vas deferens (azoospermia) as opposed to the impaired sperm motility seen in Kartagener syndrome.

(Choice D) Most cases of hypertrophic cardiomyopathy are due to mutations in the genes encoding cardiac sarcomere proteins.

(Choice E) Cirrhosis of the liver is not associated with PCD.

Educational objective:
Primary ciliary dyskinesia results from an autosomal recessive mutation in the proteins responsible for normal flagellar and ciliary structure and function (eg, dynein, assembly proteins). Clinical manifestations include situs inversus, chronic sinusitis, bronchiectasis, and infertility.

Pathology	Male Reproductive System	Bronchiectasis
Subject	System	Topic

Settings

1 2 3 4 5 6 7 8 9 10 11 12 13 14 15 16 17 18 19 20 21 22 23 24 25 26 27 28 29 30

Item 11 of 32
Question Id: 664

Mark | Previous | Next | Full Screen | Tutorial | Lab Values | Notes | Calculator | Reverse Color | Text Zoom | Settings

Exhibit Display

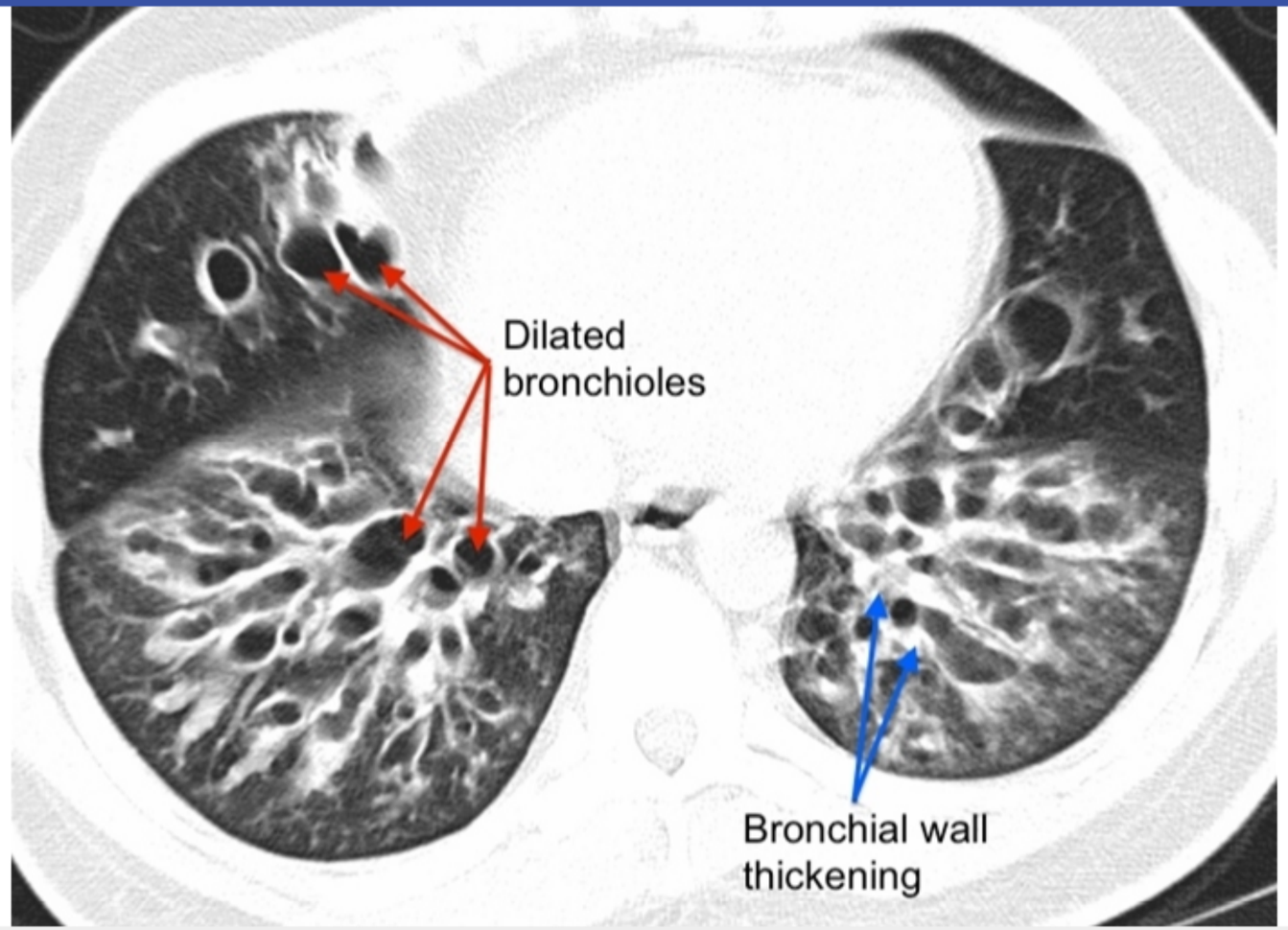

Zoom In | Zoom Out | Reset | Add To New Card | Existing Card

Block Time Remaining: 00:01:07
TUTOR

Feedback | Suspend | End Block

variety of mutations in genes responsible for normal flagellar and ciliary function. The clinical manifestations of PCD include:

1. Predisposition to upper and lower respiratory tract infections due to impaired mucociliary clearance. Patients develop chronic cough, **chronic sinusitis**, recurrent otitis media, and bronchiectasis (permanent abnormal airway enlargement).
2. Randomization of left-right body asymmetry; half of all patients have **situs inversus** (reversed right/left positioning of internal organs)
3. **Infertility** due to impaired function of sperm flagella (men) and immobility of fallopian tube cilia (women).

Patients with the triad of situs inversus, chronic sinusitis, and bronchiectasis are said to have **Kartagener syndrome**.

(Choice A) A cleft lip results from failure of the maxillary and medial nasal processes to fuse during development. It is not associated with defects in ciliary structure or function.

(Choice B) Coarctation of the aorta may be seen in Turner (XO) syndrome.

(Choice C) Fat malabsorption can occur in cystic fibrosis due to pancreatic insufficiency. Although male patients with cystic fibrosis are typically infertile, this results from bilateral absence of the vas deferens (azoospermia) as opposed to the impaired sperm motility seen in Kartagener syndrome.

(Choice D) Most cases of hypertrophic cardiomyopathy are due to mutations in the genes encoding cardiac sarcomere proteins.

(Choice E) Cirrhosis of the liver is not associated with PCD.

Educational objective:
Primary ciliary dyskinesia results from an autosomal recessive mutation in the proteins responsible for normal flagellar and ciliary structure and function (eg, dynein, assembly proteins). Clinical manifestations include situs inversus, chronic sinusitis, bronchiectasis, and infertility.

Pathology	Male Reproductive System	Bronchiectasis
Subject	System	Topic

Copyright © UWorld. All rights reserved.

A 28-year-old nulliparous woman comes to the clinic to be evaluated for infertility. She has been having unprotected intercourse with her husband for the past 12 months and experiences pain with deep vaginal penetration. Menarche was at age 11 and her period occurs every 26 days and lasts 5-7 days. Her menstrual cycles are accompanied by moderate to severe lower abdominal pain. Pelvic examination shows a normal-sized, retroverted uterus. The posterior vaginal fornix is very tender to palpation. This patient's condition most likely involves which of the following?

A. Ectopic endometrial tissue

B. Glycogen deficient vaginal epithelium

C. Increased endometrial gland to stroma ratio

D. Multiple ovarian cysts with cortical fibrosis

E. Proliferation of endometrial glands within the myometrium

Submit

A 28-year-old nulliparous woman comes to the clinic to be evaluated for infertility. She has been having unprotected intercourse with her husband for the past 12 months and experiences pain with deep vaginal penetration. Menarche was at age 11 and her period occurs every 26 days and lasts 5-7 days. Her menstrual cycles are accompanied by moderate to severe lower abdominal pain. Pelvic examination shows a normal-sized, retroverted uterus. The posterior vaginal fornix is very tender to palpation. This patient's condition most likely involves which of the following?

- ✓ A. Ectopic endometrial tissue (66%)
- B. Glycogen deficient vaginal epithelium (5%)
- C. Increased endometrial gland to stroma ratio (5%)
- D. Multiple ovarian cysts with cortical fibrosis (4%)
- E. Proliferation of endometrial glands within the myometrium (18%)

Omitted
Correct answer
A

66%
Answered correctly

02 secs
Time Spent

06/15/2020
Last Updated

Explanation

Causes of abnormal menstrual bleeding	
Diagnosis	Clinical features

Causes of abnormal menstrual bleeding	
Diagnosis	**Clinical features**
Fibroids	• Heavy menses • Constipation, urinary frequency, pelvic pain/heaviness • Enlarged uterus
Adenomyosis	• Dysmenorrhea, pelvic pain • Heavy menses • Bulky, globular & tender uterus
Endometrial cancer/hyperplasia	• History of obesity, nulliparity, or chronic anovulation • Irregular, intermenstrual, or postmenopausal bleeding • Nontender uterus

©UWorld

Endometriosis (or ectopic endometrium) refers to the presence of endometrial tissue outside the uterus. Nulliparity, early menarche, and prolonged menses are risk factors for endometriosis. In contrast, multiparity, extended lactation, and late menarche decrease the risk due to less frequent menstrual cycles and opportunity for endometrial cells to be disseminated outside the uterus.

Ectopic endometrium responds to hormonal influences of the menstrual cycle in the same way as uterine endometrium. Bleeding and shedding of extrauterine endometrium leads to formation of blood collections in the ectopic locations. Over time, the blood undergoes hemolysis and induces inflammation. Local inflammation is followed by adhesion formation, which in turn distorts organ structure and function.

Adhesions may interfere with ovulation and fallopian tube function, resulting in **infertility**. Implants and adhesions involving the uterosacral ligament can result in a **fixed, retroverted uterus**. Infiltration of the posterior cul-de-sac can result in **painful intercourse** and tenderness with

©UWorld

Endometriosis (or ectopic endometrium) refers to the presence of endometrial tissue outside the uterus. Nulliparity, early menarche, and prolonged menses are risk factors for endometriosis. In contrast, multiparity, extended lactation, and late menarche decrease the risk due to less frequent menstrual cycles and opportunity for endometrial cells to be disseminated outside the uterus.

Ectopic endometrium responds to hormonal influences of the menstrual cycle in the same way as uterine endometrium. Bleeding and shedding of extrauterine endometrium leads to formation of blood collections in the ectopic locations. Over time, the blood undergoes hemolysis and induces inflammation. Local inflammation is followed by adhesion formation, which in turn distorts organ structure and function.

Adhesions may interfere with ovulation and fallopian tube function, resulting in **infertility**. Implants and adhesions involving the uterosacral ligament can result in a **fixed, retroverted uterus**. Infiltration of the posterior cul-de-sac can result in **painful intercourse** and tenderness with palpation of the posterior vaginal fornix. Shedding of the ectopic tissue causes **dysmenorrhea** (painful menses).

(Choice B) Estrogen deficiency from premature ovarian failure or menopause can result in glycogen deficiency in the vaginal epithelium. The resulting flattening of the labial folds and vaginal rugae can cause dyspareunia. However, this patient's regular menstrual periods reflect normal estrogen levels.

(Choice C) Endometrial hyperplasia is characterized by an increased endometrial gland to stroma ratio due to excess estrogen stimulation. Affected patients often present with irregular menses (eg, intermenstrual bleeding). In contrast, this patient has painful but regular menstrual cycles.

(Choice D) Multiple small follicular cysts in the ovaries and cortical fibrosis occur in polycystic ovary syndrome (PCOS). PCOS is associated with obesity, hirsutism, oligomenorrhea, and infertility. This patient's regular menses and absence of hyperandrogenism makes PCOS an unlikely etiology.

(Choice E) Adenomyosis is the presence of endometrial glands within the uterine myometrium. Abnormal uterine bleeding and painful menses are common, but the uterus is generally enlarged.

Educational objective:
Endometriosis refers to the presence of endometrial glands and stroma outside the uterus. It may be asymptomatic or present with dysmenorrhea, dyspareunia, and/or infertility.

©UWorld

Exhibit Display

Pelvic endometriosis

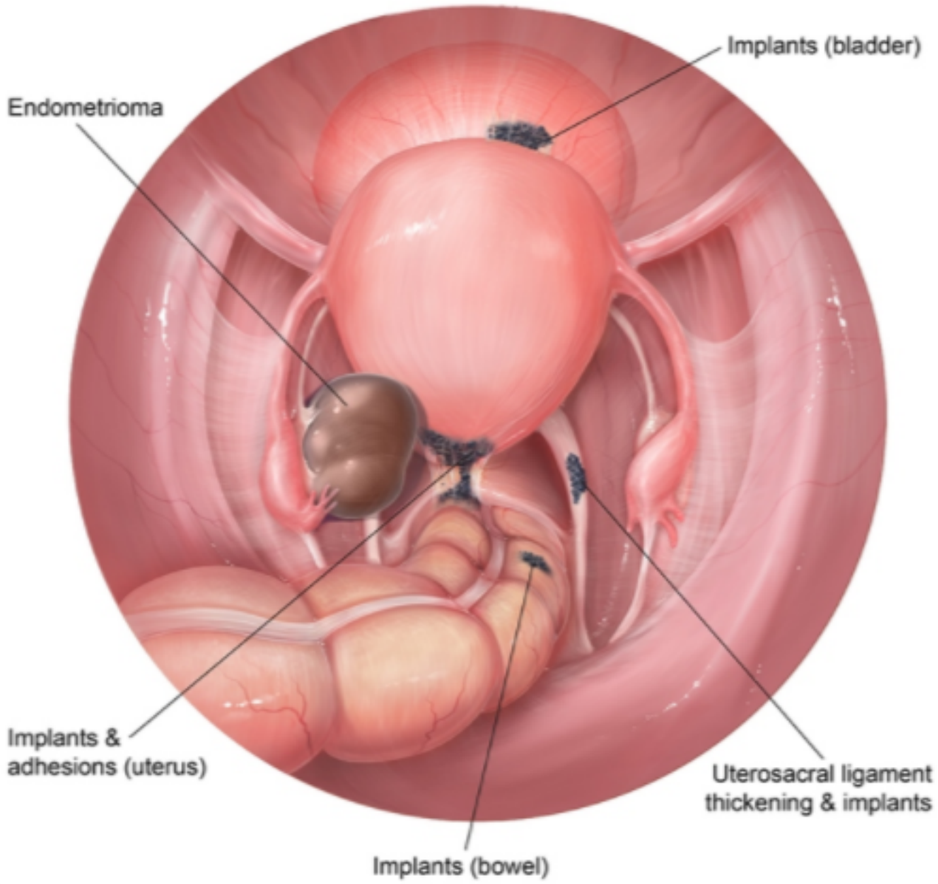

©UWorld

Zoom In | Zoom Out | Reset | Add To New Card | Existing Card

dysmenorrhea, dyspareunia, and/or infertility.

©UWorld

Exhibit Display

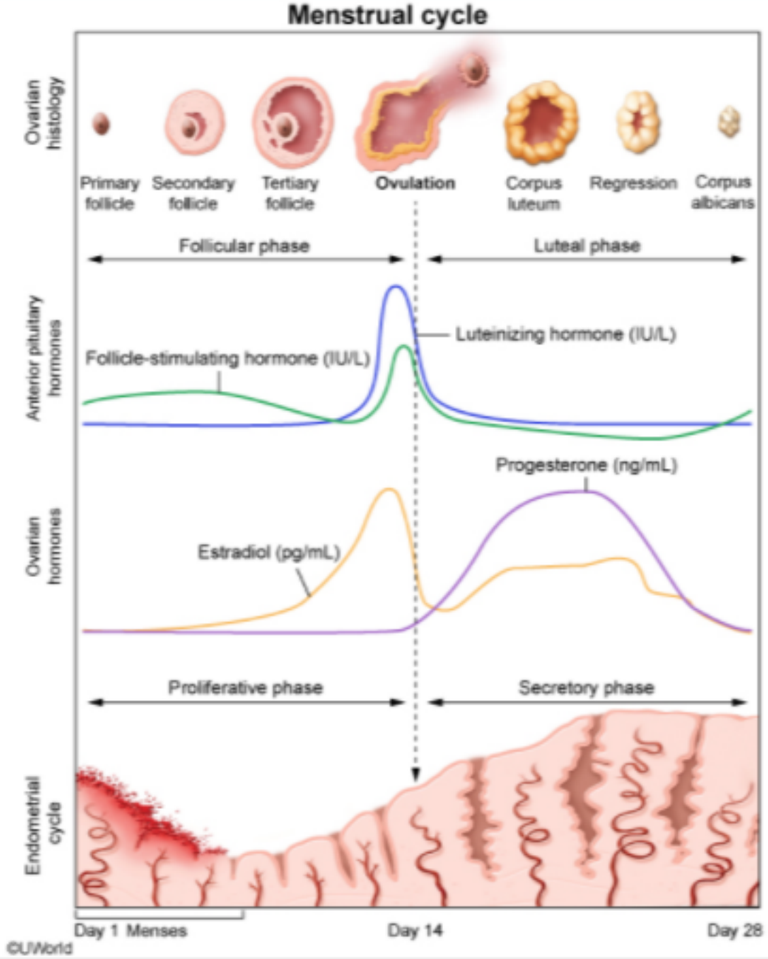

Zoom In | Zoom Out | Reset | Add To New Card | Existing Card

dysmenorrhea, dyspareunia, and/or infertility.

1 2 3 4 5 6 7 8 9 10 11 12 13 14 15 16 17 18 19 20 21 22 23 24 25 26 27 28 29 30

inflammation. Local inflammation is followed by adhesion formation, which in turn distorts organ structure and function.

Adhesions may interfere with ovulation and fallopian tube function, resulting in **infertility**. Implants and adhesions involving the uterosacral ligament can result in a **fixed, retroverted uterus**. Infiltration of the posterior cul-de-sac can result in **painful intercourse** and tenderness with palpation of the posterior vaginal fornix. Shedding of the ectopic tissue causes **dysmenorrhea** (painful menses).

(Choice B) Estrogen deficiency from premature ovarian failure or menopause can result in glycogen deficiency in the vaginal epithelium. The resulting flattening of the labial folds and vaginal rugae can cause dyspareunia. However, this patient's regular menstrual periods reflect normal estrogen levels.

(Choice C) Endometrial hyperplasia is characterized by an increased endometrial gland to stroma ratio due to excess estrogen stimulation. Affected patients often present with irregular menses (eg, intermenstrual bleeding). In contrast, this patient has painful but regular menstrual cycles.

(Choice D) Multiple small follicular cysts in the ovaries and cortical fibrosis occur in polycystic ovary syndrome (PCOS). PCOS is associated with obesity, hirsutism, oligomenorrhea, and infertility. This patient's regular menses and absence of hyperandrogenism makes PCOS an unlikely etiology.

(Choice E) Adenomyosis is the presence of endometrial glands within the uterine myometrium. Abnormal uterine bleeding and painful menses are common, but the uterus is generally enlarged.

Educational objective:
Endometriosis refers to the presence of endometrial glands and stroma outside the uterus. It may be asymptomatic or present with dysmenorrhea, dyspareunia, and/or infertility.

References

- Practice Bulletin No. 114: Management of Endometriosis.
- Evaluation and Treatment of Endometriosis

Pathology	Female Reproductive System & Breast	Endometriosis
Subject	System	Topic

inflammation. Local inflammation is followed by adhesion formation, which in turn distorts organ structure and function.

Exhibit Display

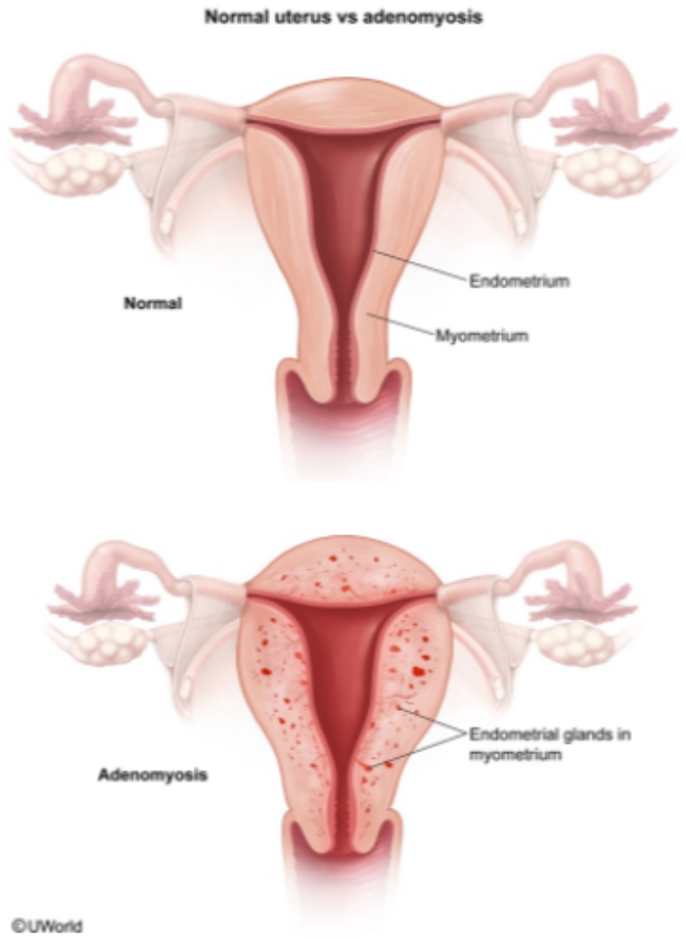

Zoom In | Zoom Out | Reset | Add To New Card | Existing Card

Subject System Topic

A 77-year-old man is brought to the emergency department due to acute-onset chest pain, shortness of breath, and syncope. Medical history is significant for coronary artery disease, which was treated with right coronary artery stenting 5 years ago. The patient develops cardiac arrest and resuscitation is unsuccessful. Autopsy shows a large bilateral pulmonary embolism occluding the pulmonary trunk. Further history obtained from the patient's wife indicates that he has had constant back pain over the past few months. Autopsy of the vertebrae is shown in the image below:

Histologic examination of the bone lesions in this patient would most likely show which of the following?

A. Aggregates of pleomorphic neoplastic cells containing coarse, brown pigment

A 77-year-old man is brought to the emergency department due to acute-onset chest pain, shortness of breath, and syncope. Medical history is significant for coronary artery disease, which was treated with right coronary artery stenting 5 years ago. The patient develops cardiac arrest and resuscitation is unsuccessful. Autopsy shows a large bilateral pulmonary embolism occluding the pulmonary trunk. Further history obtained from the patient's wife indicates that he has had constant back pain over the past few months. Autopsy of the vertebrae is shown in the image below:

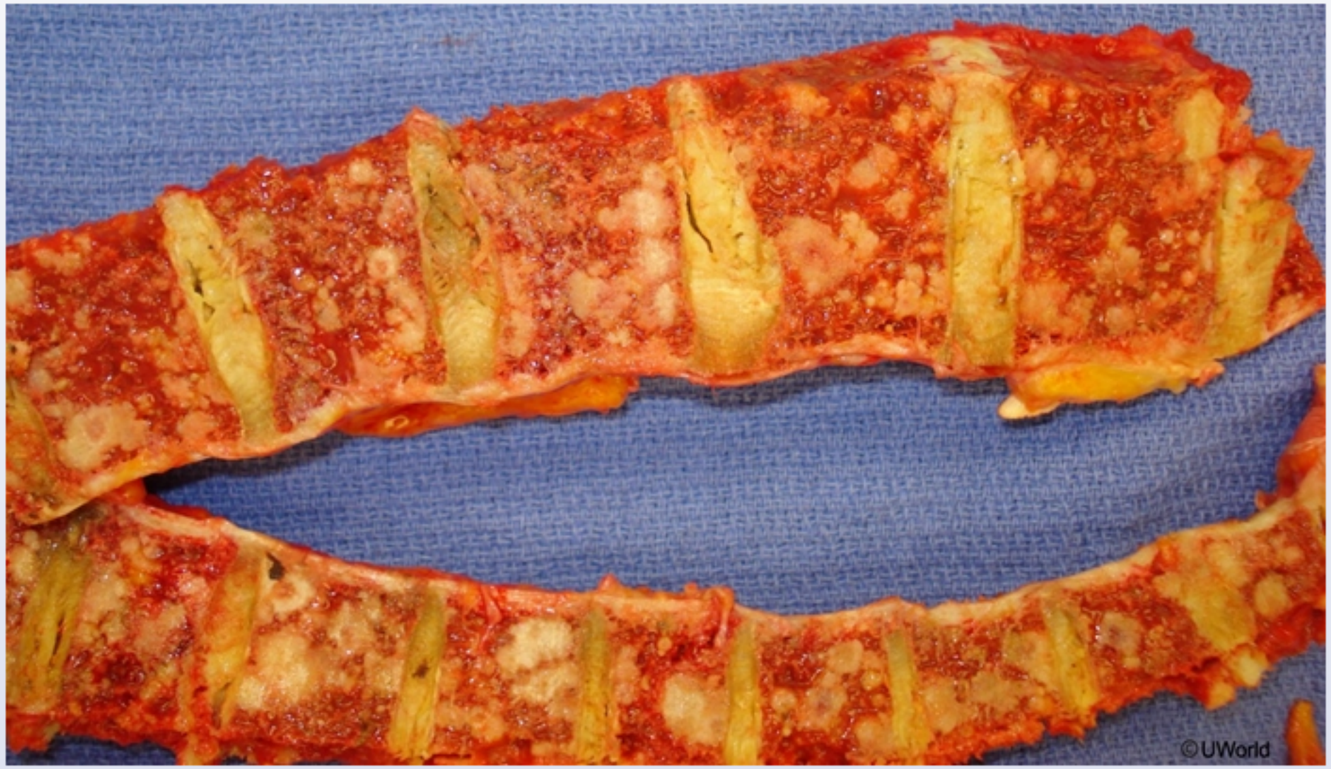

Histologic examination of the bone lesions in this patient would most likely show which of the following?

A. Aggregates of pleomorphic neoplastic cells containing coarse, brown pigment

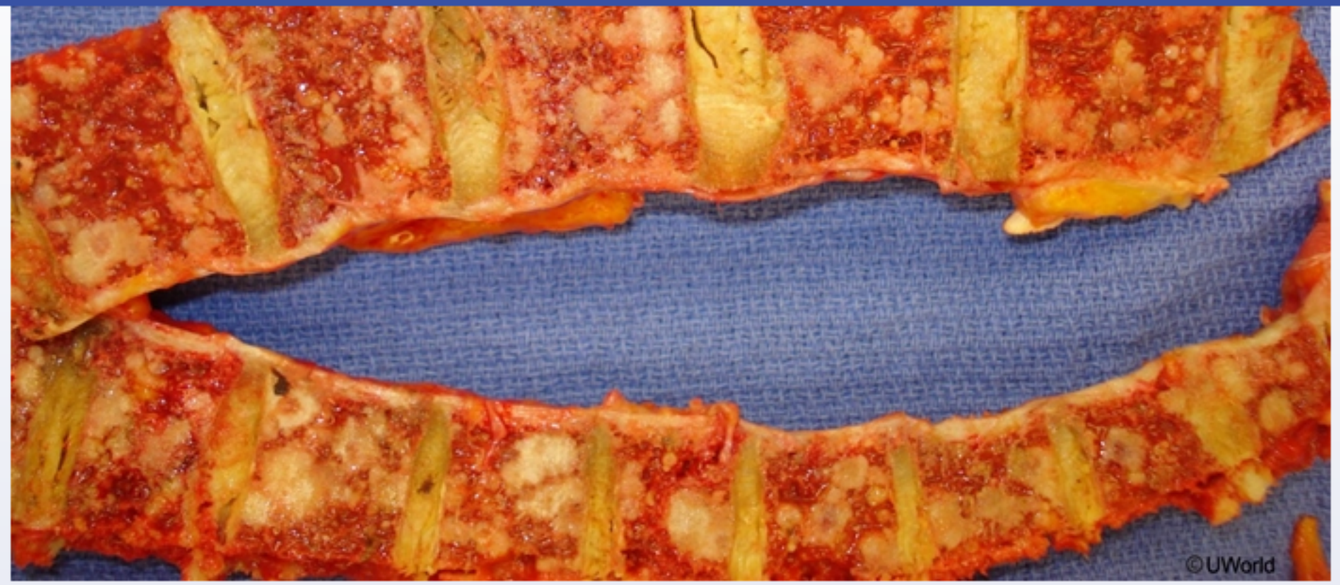

Histologic examination of the bone lesions in this patient would most likely show which of the following?

- A. Aggregates of pleomorphic neoplastic cells containing coarse, brown pigment
- B. Cells with enlarged nuclei and prominent nucleoli forming irregular glands
- C. Effacement of bone marrow with clusters of plasmablasts and plasma cells
- D. Sheets of neoplastic cells with abundant clear cytoplasm
- E. Tumor cells showing a complex papillary pattern and psammoma bodies

Submit

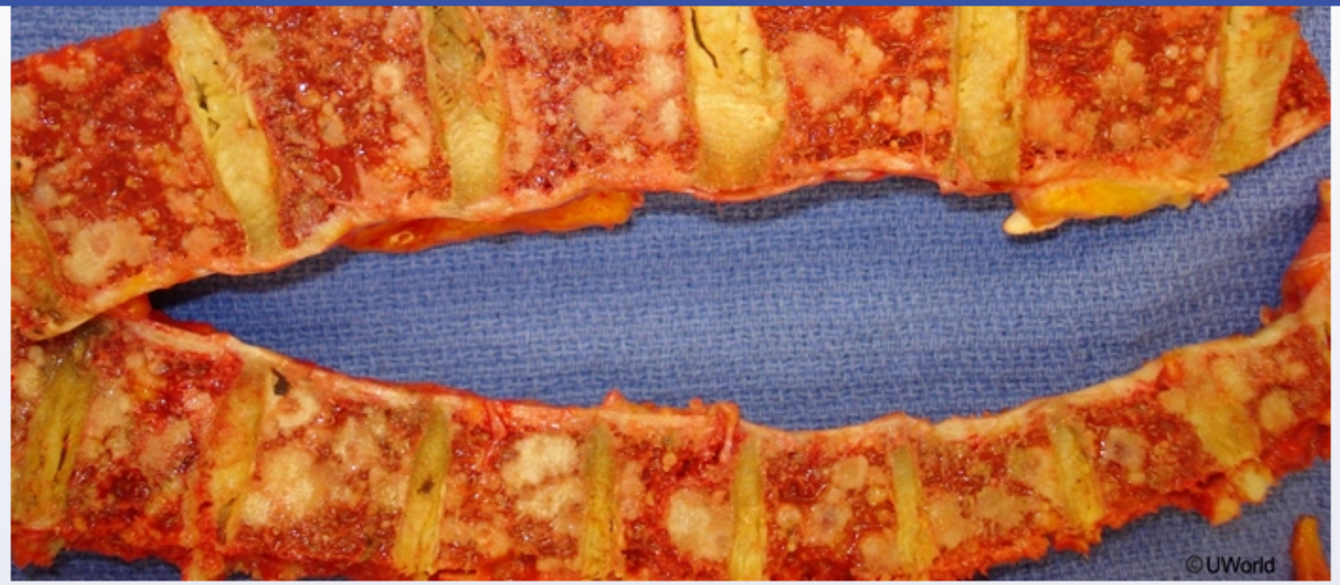

Histologic examination of the bone lesions in this patient would most likely show which of the following?

- A. Aggregates of pleomorphic neoplastic cells containing coarse, brown pigment (7%)
- ✓ B. Cells with enlarged nuclei and prominent nucleoli forming irregular glands (50%)
- C. Effacement of bone marrow with clusters of plasmablasts and plasma cells (26%)
- D. Sheets of neoplastic cells with abundant clear cytoplasm (11%)
- E. Tumor cells showing a complex papillary pattern and psammoma bodies (4%)

Omitted
Correct answer

50%
Answered correctly

05 secs
Time Spent

04/30/2020
Last Updated

Metastatic prostatic adenocarcinoma to spine

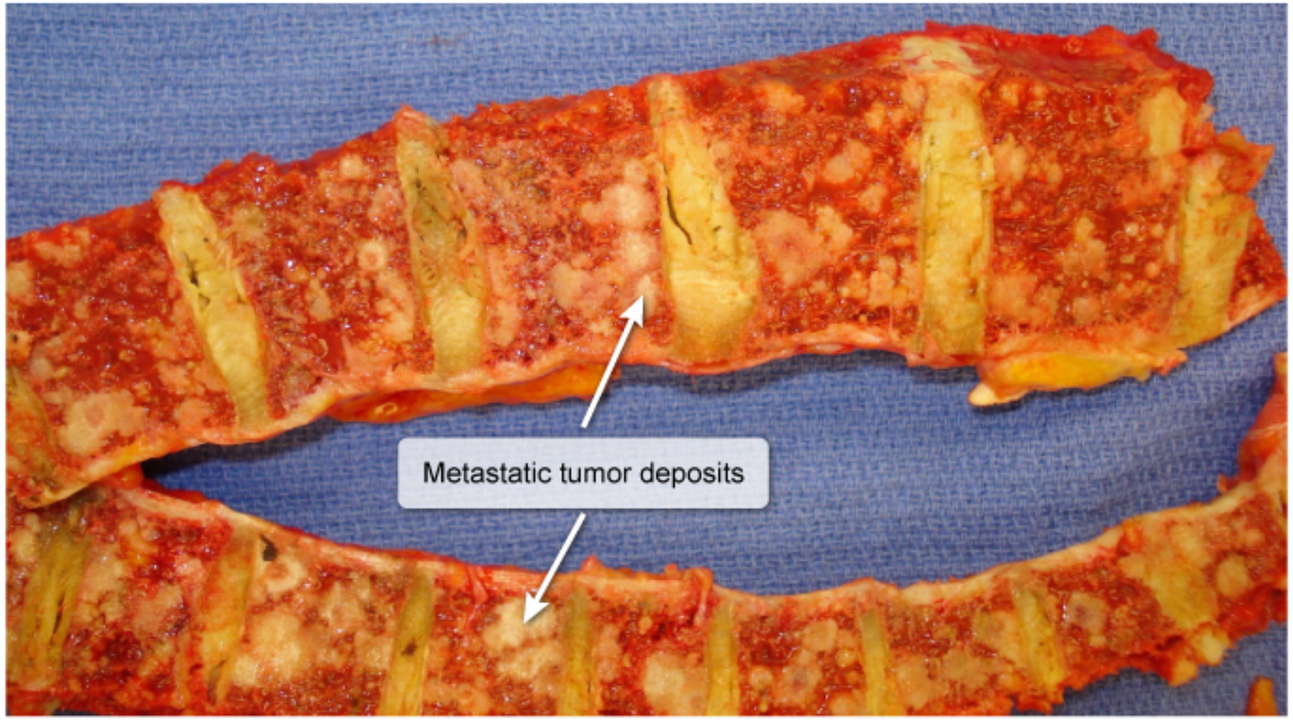

©UWorld

This patient's vertebral body **bony lesions** raise strong suspicion for osteoblastic metastases due to **prostate adenocarcinoma**; his massive pulmonary embolism was likely precipitated by an underlying **hypercoagulable state** of malignancy. Prostate cancer is the most common non-skin cancer in men, and risk is strongly linked to **advancing age**. Because most cases develop in the periphery of the prostate gland, urinary symptoms are uncommon until late in the disease course; therefore, the diagnosis is usually prompted by elevated prostate-specific antigen level, abnormal digital rectal examination, or symptoms related to advanced disease (eg, **bone pain**).

Prostate cancer preferentially metastasizes to **bone** due to specific adhesion molecules (eg, CXCR4) and receptor ligands (eg, RANK) on the

©UWorld

This patient's vertebral body **bony lesions** raise strong suspicion for osteoblastic metastases due to **prostate adenocarcinoma**; his massive pulmonary embolism was likely precipitated by an underlying **hypercoagulable state** of malignancy. Prostate cancer is the most common non-skin cancer in men, and risk is strongly linked to **advancing age**. Because most cases develop in the periphery of the prostate gland, urinary symptoms are uncommon until late in the disease course; therefore, the diagnosis is usually prompted by elevated prostate-specific antigen level, abnormal digital rectal examination, or symptoms related to advanced disease (eg, **bone pain**).

Prostate cancer preferentially metastasizes to **bone** due to specific adhesion molecules (eg, CXCR4) and receptor ligands (eg, RANK) on the cancer cell surface that adhere to pericytes and bone marrow stromal cells. After it establishes a nidus, the tumor secretes **osteoblast differentiation factors** (eg, endothelin 1, insulin-like growth factors, platelet-derived growth factors, bone morphogenic proteins) that promote new bone growth. Biopsy of a bone lesion would most likely show disordered trabecular growth and evidence of prostate cancer cells such as irregular glands with enlarged nuclei and prominent nucleoli.

(Choices A, C, D, and E) *Osteolytic* bone metastases appear on gross pathology as *moth-eaten* bone, not areas of bony growth. These bone lesions are typically seen with metastatic melanoma (pleomorphic cells with coarse, brown melanin pigment), multiple myeloma (effacement of marrow with plasmablasts and plasma cells), renal cell carcinoma (sheets of neoplastic cells with abundant clear cytoplasm), and thyroid papillary carcinoma (complex papillary pattern and psammoma bodies).

Educational objective:
Prostate cancer is common in older men and metastasizes primarily to bone due to bone-specific tumor adhesion molecules and receptor ligands on the cellular surface. Prostate cancer causes osteoblastic lesions that result in new bone growth. Biopsy would show disordered trabeculae and signs of prostate cancer such as irregular glands with enlarged nuclei and prominent nucleoli.

Pathology	Male Reproductive System	Prostate cancer
Subject	System	Topic

Copyright © UWorld. All rights reserved.

1 2 3 4 5 6 7 8 9 10 11 12 13 14 15 16 17 18 19 20 21 22 23 24 25 26 27 28 29 30

Exhibit Display

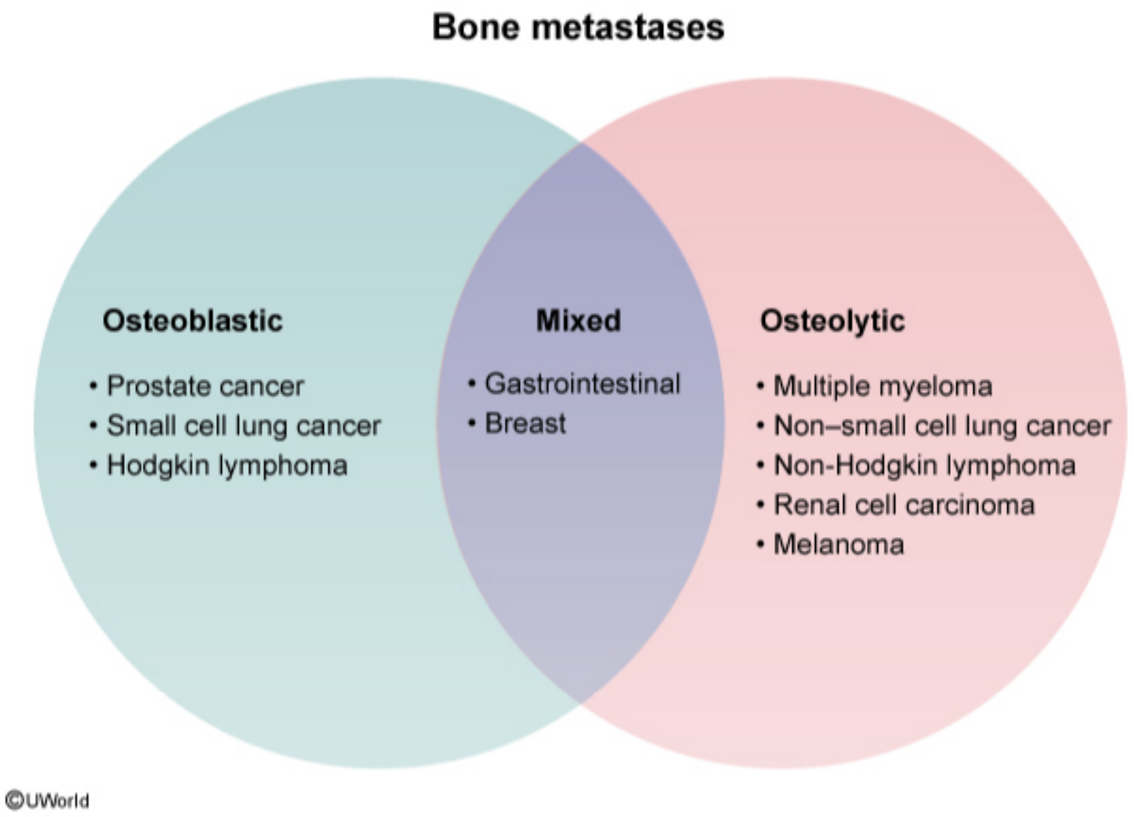

Zoom In | Zoom Out | Reset | Add To Flash Card

Settings

1
2
3
4
5
6
7
8
9
10
11
12
13
14
15
16
17
18
19
20
21
22
23
24
25
26
27
28
29
30

Item 13 of 32
Question Id: 16002

Mark | Previous | Next | Full Screen | Tutorial | Lab Values | Notes | Calculator | Reverse Color | Text Zoom | Settings

Exhibit Display

Zoom In | Zoom Out | Reset | Add To Flash Card

Block Time Remaining: 00:01:14
TUTOR

0 | Feedback | Suspend | End Block

Settings

1
2
3
4
5
6
7
8
9
10
11
12
13
14
15
16
17
18
19
20
21
22
23
24
25
26
27
28
29
30

Item 13 of 32
Question Id: 16002

Mark | Previous | Next | Full Screen | Tutorial | Lab Values | Notes | Calculator | Reverse Color | Text Zoom | Settings

Exhibit Display

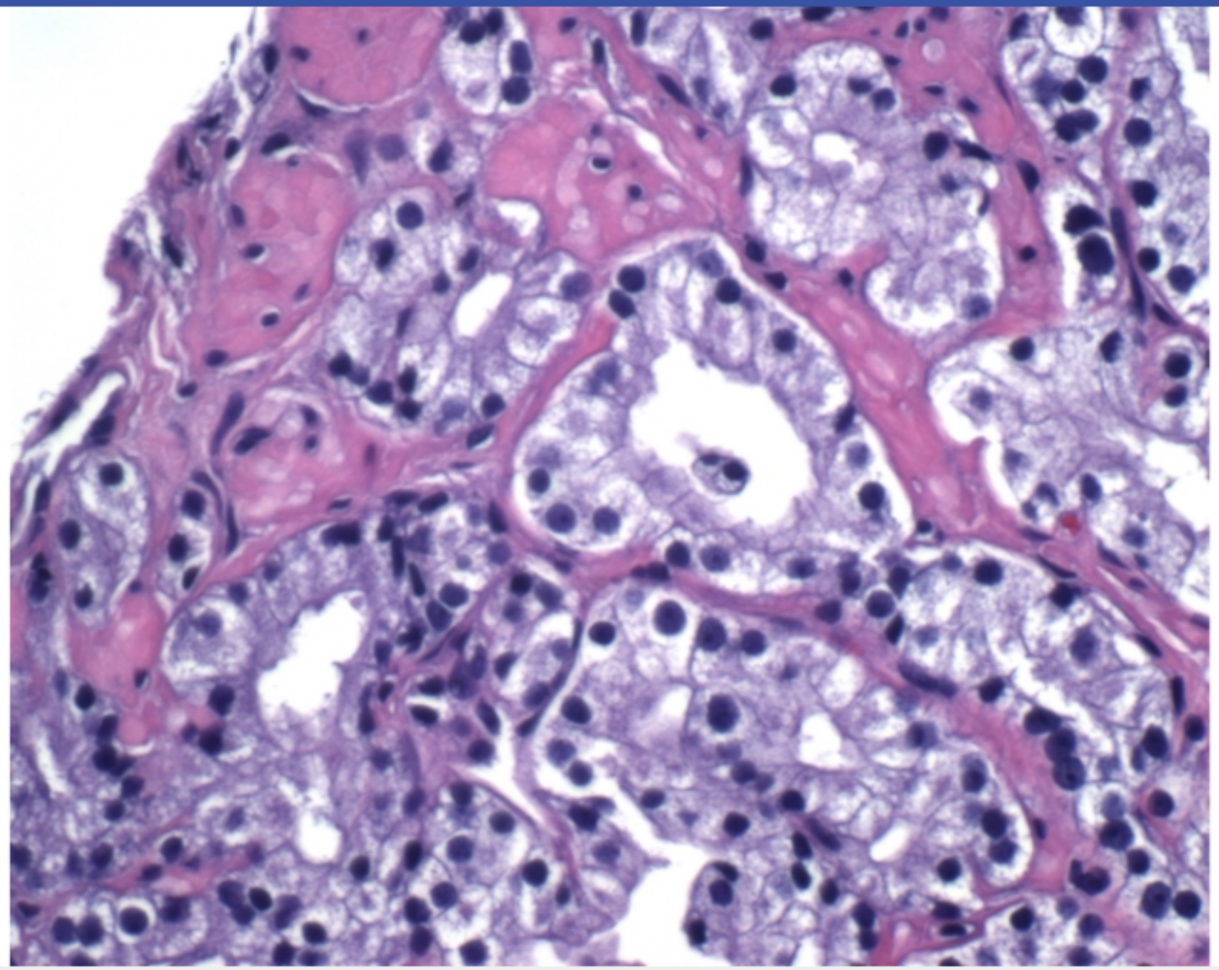

Zoom In | Zoom Out | Reset | Add To Flash Card

Block Time Remaining: 00:01:14
TUTOR

0 | Feedback | Suspend | End Block

Settings

1 2 3 4 5 6 7 8 9 10 11 12 13 14 15 16 17 18 19 20 21 22 23 24 25 26 27 28 29 30

Item 13 of 32
Question Id: 16002

Mark | Previous | Next | Full Screen | Tutorial | Lab Values | Notes | Calculator | Reverse Color | Text Zoom | Settings

Exhibit Display

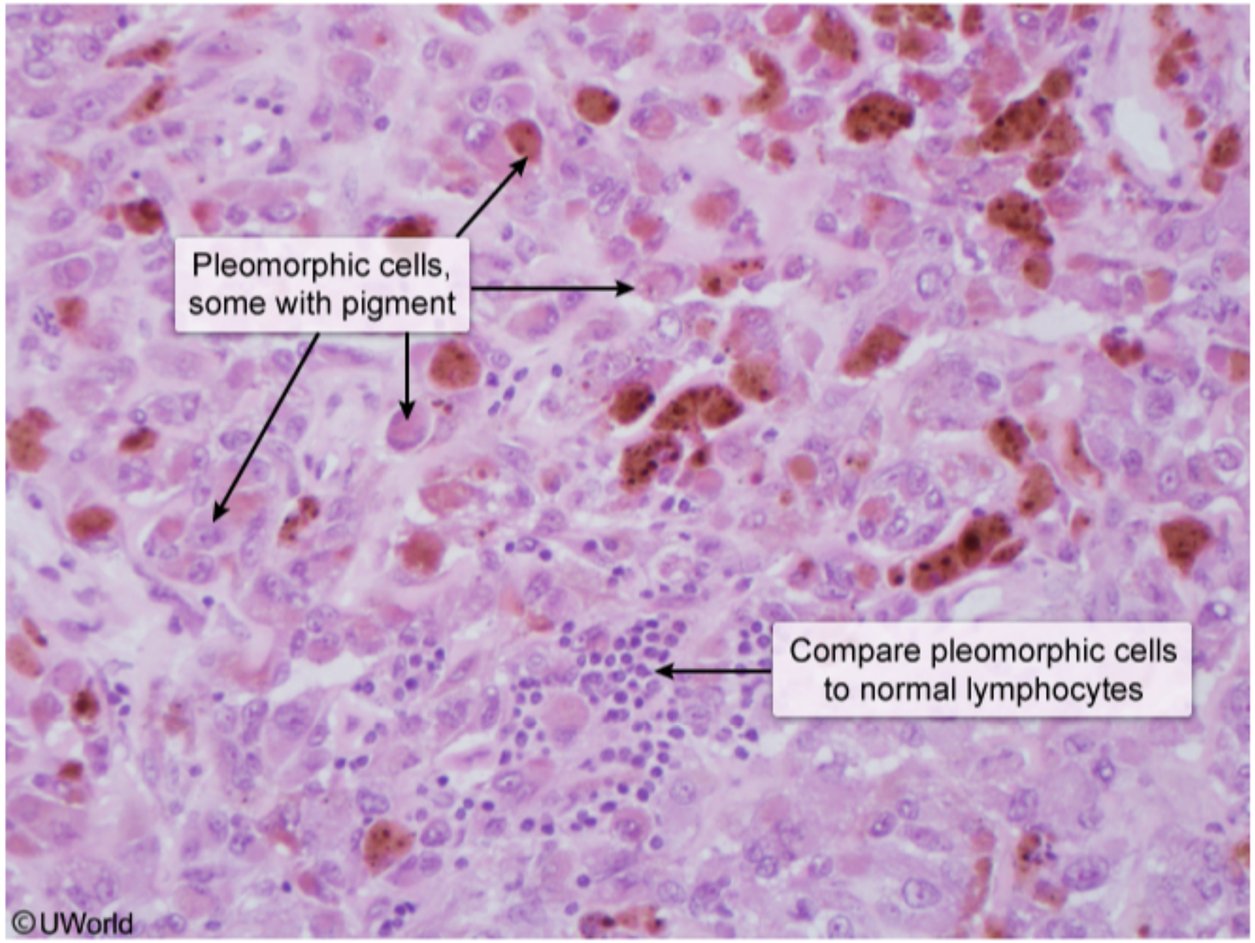

Zoom In | Zoom Out | Reset | Add To Flash Card

Block Time Remaining: 00:01:14
TUTOR

0 | Feedback | Suspend | End Block

Settings

1 2 3 4 5 6 7 8 9 10 11 12 13 14 15 16 17 18 19 20 21 22 23 24 25 26 27 28 29 30

Item 13 of 32
Question Id: 16002

Mark | Previous | Next | Full Screen | Tutorial | Lab Values | Notes | Calculator | Reverse Color | Text Zoom | Settings

Exhibit Display

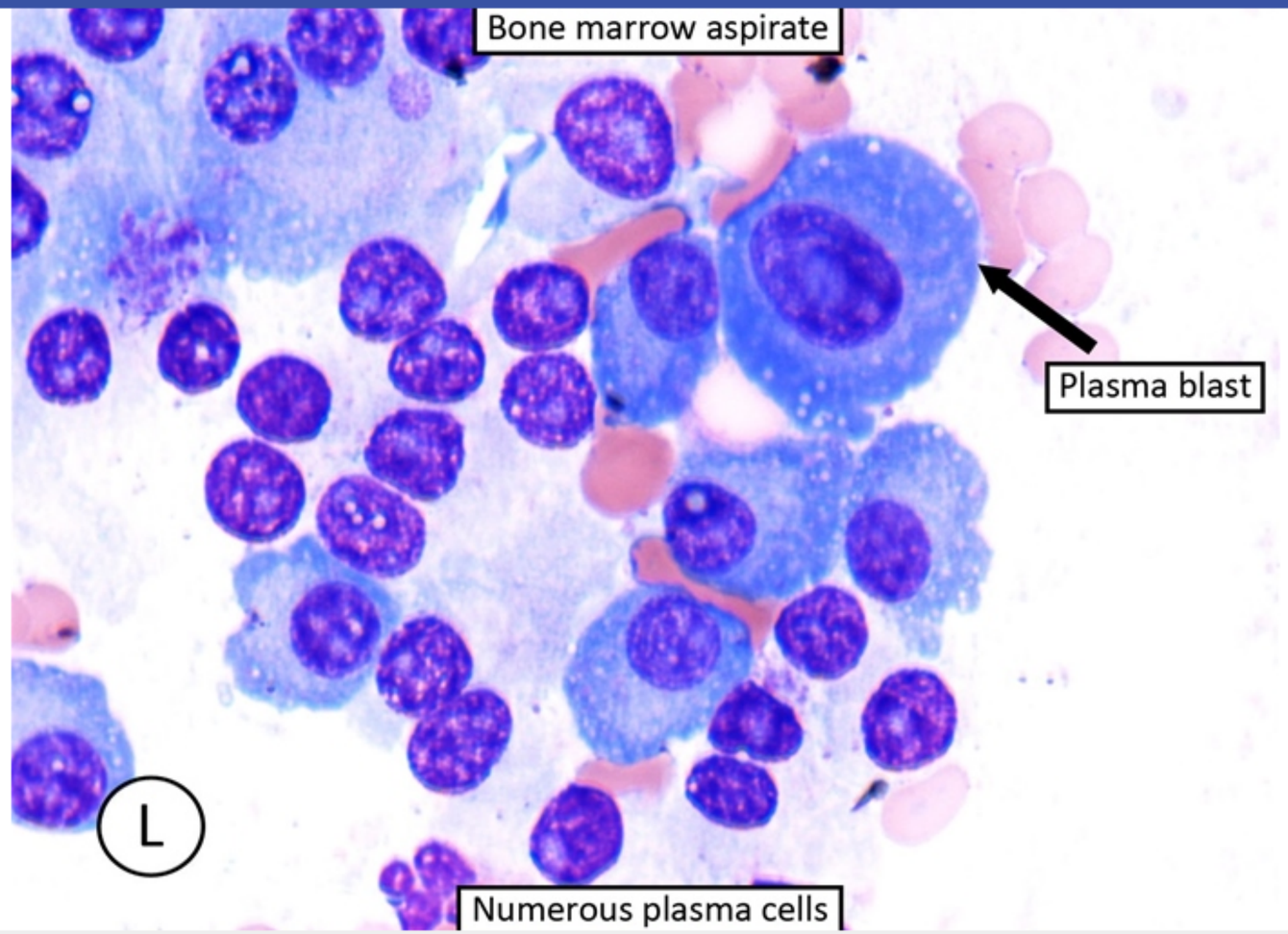

Zoom In | Zoom Out | Reset | Add To Flash Card

Block Time Remaining: 00:01:14
TUTOR

0 | Feedback | Suspend | End Block

Settings

1 2 3 4 5 6 7 8 9 10 11 12 13 14 15 16 17 18 19 20 21 22 23 24 25 26 27 28 29 30

Item 13 of 32
Question Id: 16002

Mark | Previous | Next | Full Screen | Tutorial | Lab Values | Notes | Calculator | Reverse Color | Text Zoom | Settings

Exhibit Display

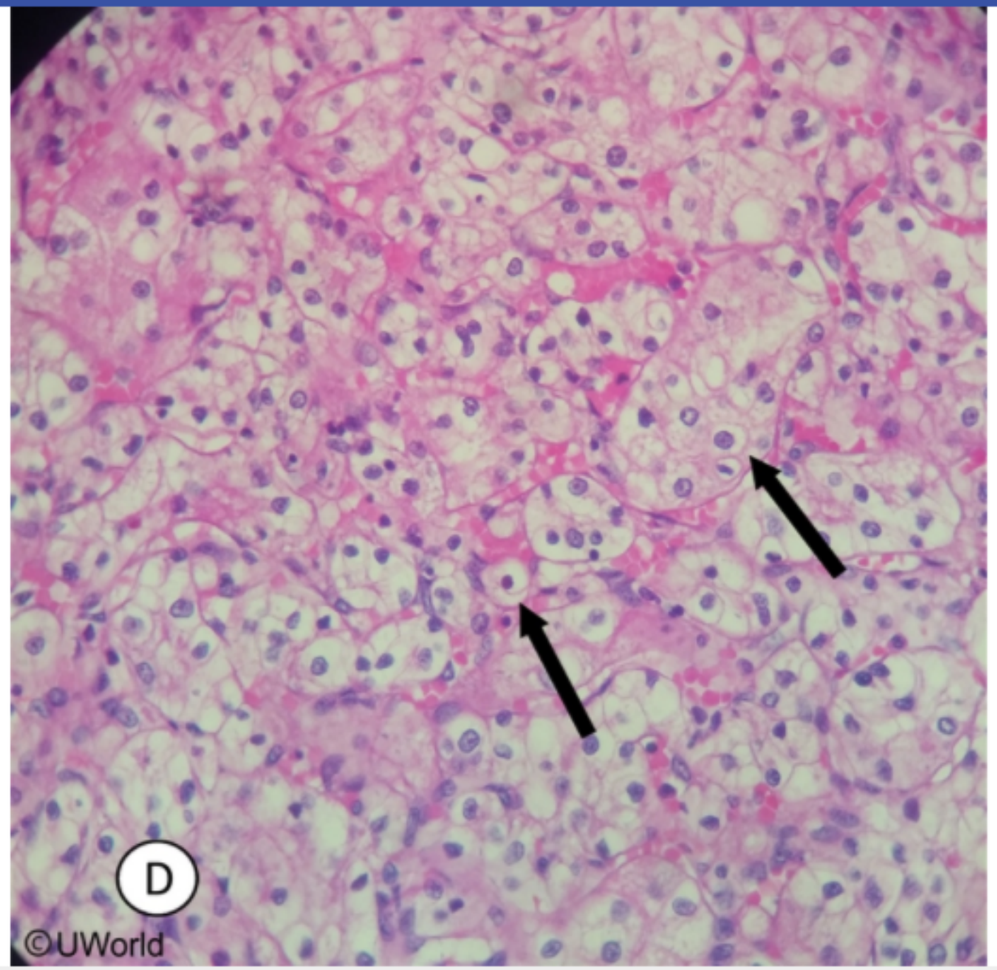

Zoom In | Zoom Out | Reset | Add To Flash Card

Block Time Remaining: 00:01:14
TUTOR

0 | Feedback | Suspend | End Block

Settings

1 2 3 4 5 6 7 8 9 10 11 12 13 14 15 16 17 18 19 20 21 22 23 24 25 26 27 28 29 30

Item 13 of 32
Question Id: 16002

Mark | Previous | Next | Full Screen | Tutorial | Lab Values | Notes | Calculator | Reverse Color | Text Zoom | Settings

Exhibit Display

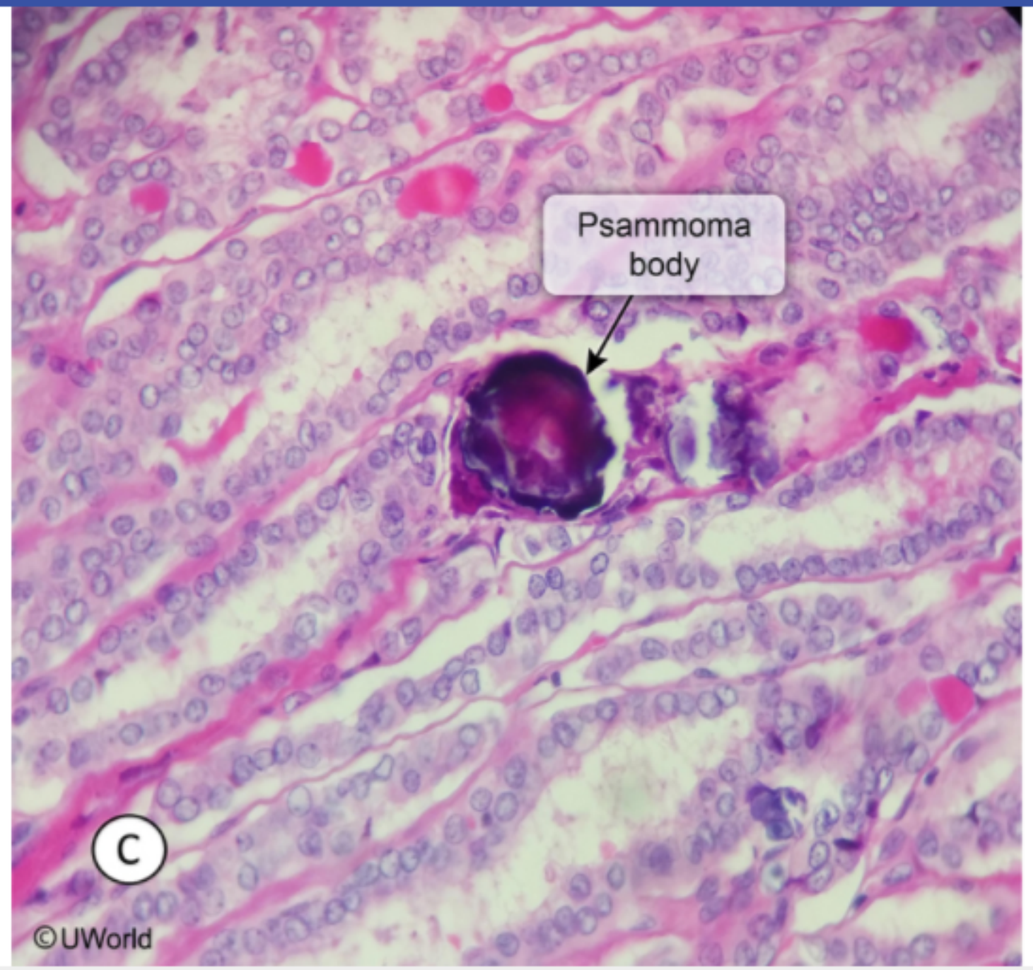

Zoom In | Zoom Out | Reset | Add To Flash Card

Block Time Remaining: 00:01:14
TUTOR

0 | Feedback | Suspend | End Block

A 73-year-old woman, gravida 0 para 0, comes to the office due to breathing difficulty and increasing abdominal girth. She also has decreased appetite and constipation that has worsened progressively for the last 6 months. The patient has no other medical conditions and has not seen a health care provider in several years. On physical examination, the abdomen is distended and nontender with right adnexal fullness. She undergoes laparoscopic surgical evaluation for a right adnexal mass. Microscopic examination of the surgical biopsy specimen reveals anaplasia of epithelial cells with invasion into the stroma and multiple papillary formations with cellular atypia, as shown in the exhibit. Which of the following is most likely to be elevated in this patient?

A. α-fetoprotein
B. β-hCG
C. CA-125
D. Estrogen
E. Inhibin
F. LDH
G. Testosterone

Submit

A 73-year-old woman, gravida 0 para 0, comes to the office due to breathing difficulty and increasing abdominal girth. She also has decreased appetite and constipation that has worsened progressively for the last 6 months. The patient has no other medical conditions and has not seen a health care provider in several years. On physical examination, the abdomen is distended and nontender with right adnexal fullness. She undergoes laparoscopic surgical evaluation for a right adnexal mass. Microscopic examination of the surgical biopsy specimen reveals anaplasia of epithelial cells with invasion into the stroma and multiple papillary formations with cellular atypia, as shown in the exhibit. Which of the following is most likely to be elevated in this patient?

- A. α-fetoprotein (5%)
- B. β-hCG (6%)
- ✓ C. CA-125 (76%)
- D. Estrogen (6%)
- E. Inhibin (1%)
- F. LDH (2%)
- G. Testosterone (0%)

Omitted
Correct answer
C

76%
Answered correctly

03 secs
Time Spent

06/03/2020
Last Updated

Explanation

Malignant ovarian neoplasms		
Histologic type	**Diagnosis**	**Key features**
Epithelial	**Serous cystadenocarcinoma**	• Most common ovarian cancer • Often bilateral • Histology: Psammoma bodies
	Mucinous cystadenocarcinoma	• Pseudomyxoma peritonei • Mucin-producing epithelial cells
Germ cell	**Dysgerminoma**	• Adolescents • ↑ β-hCG, ↑ LDH • Histology: "Fried egg cells"
	Endodermal sinus (yolk sac)	• ↑ AFP • Aggressive • Schiller-Duval bodies resemble glomeruli
Stroma (sex cord)	**Granulosa cell**	• ↑ Estrogen (eg, endometrial hyperplasia, postmenopausal bleeding) • ↑ Inhibin • Histology: Call-Exner bodies, coffee bean nuclei
	Sertoli-Leydig	• ↑ Androgens (eg, hirsutism, clitoromegaly)

AFP = alpha-fetoprotein; **LDH** = lactate dehydrogenase.

This patient has **ovarian cancer**, which has 3 histologic types: epithelial, germ cell, and sex cord stroma. **Epithelial** ovarian cancer is the most common subtype and is associated with increased levels of cancer antigen 125 **(CA-125)**.

CA-125 is a protein expressed by epithelial cells lining the reproductive tract (eg, ovary, fallopian tubes) and the peritoneum. Epithelial ovarian

This patient has **ovarian cancer**, which has 3 histologic types: epithelial, germ cell, and sex cord stroma. **Epithelial** ovarian cancer is the most common subtype and is associated with increased levels of cancer antigen 125 **(CA-125)**.

CA-125 is a protein expressed by epithelial cells lining the reproductive tract (eg, ovary, fallopian tubes) and the peritoneum. Epithelial ovarian cancers can secrete CA-125, allowing it to be used as a **tumor marker**. However, numerous benign conditions that disrupt the epithelial cell membrane (eg, endometriosis) can also cause increased release of CA-125 into the bloodstream, making it unsuitable for cancer screening but useful for diagnosis and treatment follow-up.

Patients with ovarian cancer typically present with a pelvic mass, ascites, and peritoneal metastasis that result in decreased appetite, abdominal distension, and bowel or bladder changes (eg, constipation, urinary frequency). Nulliparous women are at increased risk for ovarian cancer due to frequent ovulation, resulting in continued disruption and repair of the ovarian epithelium. Histologic findings of epithelial ovarian cancer include anaplasia of epithelial cells with invasion into the stroma, multiple papillary formations with cellular atypia (arrow), and occasional Psammoma bodies.

(Choice A) Serum α-fetoprotein levels may be increased in patients with hepatocellular carcinoma and ovarian germ cell tumors (eg, endodermal sinus [yolk sac] tumor). Endodermal sinus tumors of the ovary demonstrate Schiller-Duval bodies, which resemble glomeruli (arrow).

(Choices B and F) β-hCG is elevated in normal pregnancy, gestational trophoblastic disease (eg, molar pregnancy, gestational choriocarcinoma), and germ cell tumors (eg, non-gestational choriocarcinoma, dysgerminomas). Dysgerminomas may also secrete LDH and have distinctive "fried egg cells" with a large round nucleus surrounded by clear cytoplasm.

(Choices D and E) Granulosa cell tumors of the ovary are sex cord stromal neoplasms that secrete estrogen, along with inhibin. Pathology findings include Call-Exner bodies with atypical granulosa cells containing coffee bean nuclei (arrows).

(Choice G) Testosterone is secreted by Sertoli-Leydig cell tumors of the ovary. These rare sex cord stromal neoplasms typically appear as tubules composed of Sertoli cells (green arrow) with interspersed eosinophilic Leydig cells and surrounding fibrous stroma (black arrow).

Educational objective:
Epithelial ovarian cancer is the most common ovarian malignancy. Histologic findings include anaplasia of epithelial cells with invasion into the stroma, along with multiple papillary formations with cellular atypia. Epithelial ovarian tumors produce CA-125, which can be used as a serum

Settings

1 2 3 4 5 6 7 8 9 10 11 12 13 14 15 16 17 18 19 20 21 22 23 24 25 26 27 28 29 30

Item 14 of 32
Question Id: 1837

Mark | Previous | Next | Full Screen | Tutorial | Lab Values | Notes | Calculator | Reverse Color | Text Zoom | Settings

common subtype and is associated with increased levels of cancer antigen 125 **(CA-125)**

Exhibit Display

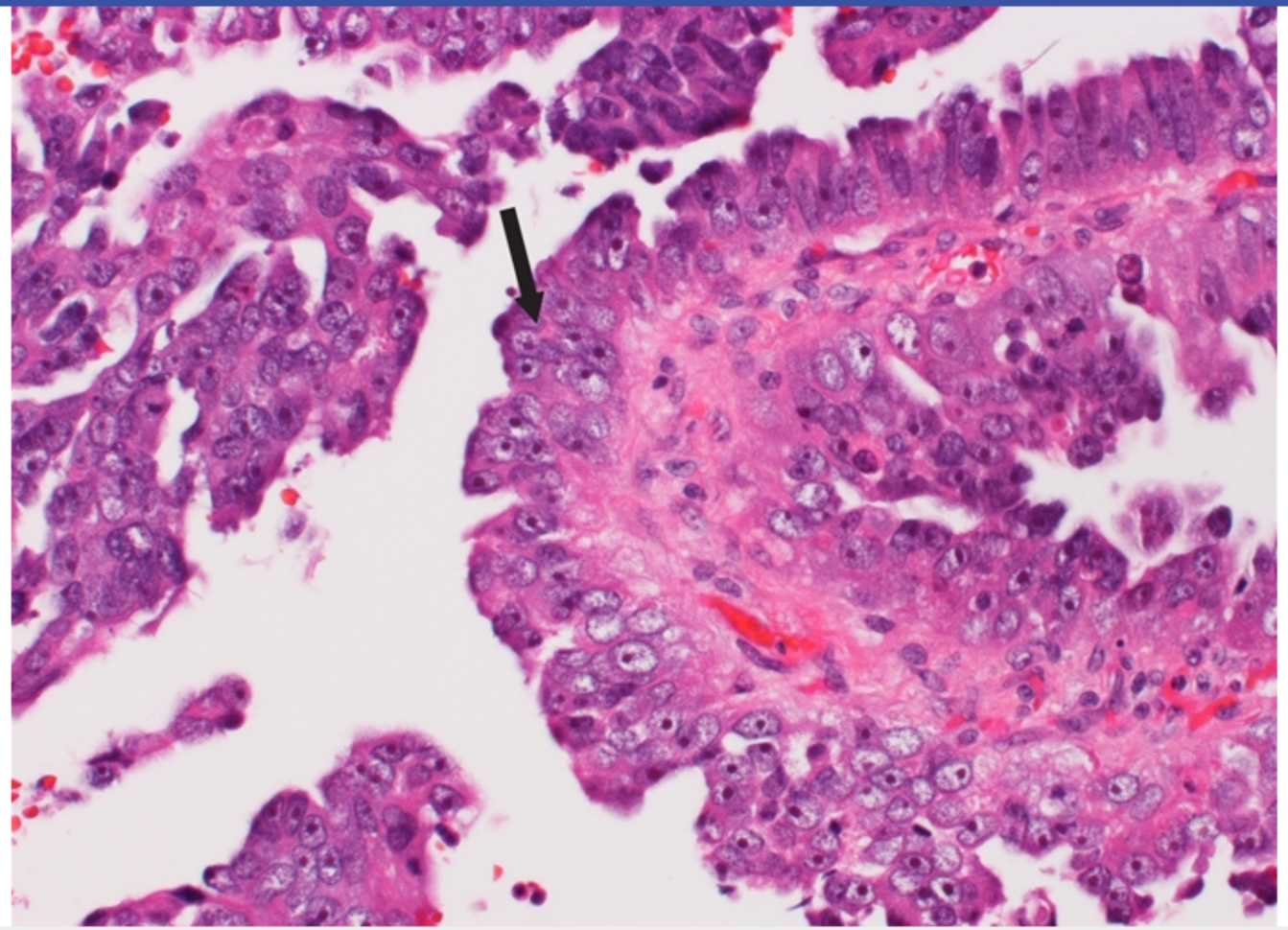

Zoom In | Zoom Out | Reset | Add To New Card | Existing Card

Block Time Remaining: 00:01:17
TUTOR

5 | Feedback | Suspend | End Block

Settings

1 2 3 4 5 6 7 8 9 10 11 12 13 14 15 16 17 18 19 20 21 22 23 24 25 26 27 28 29 30

Item 14 of 32
Question Id: 1837

Mark | Previous | Next | Full Screen | Tutorial | Lab Values | Notes | Calculator | Reverse Color | Text Zoom | Settings

common subtype and is associated with increased levels of cancer antigen 125 **(CA-125)**

Exhibit Display

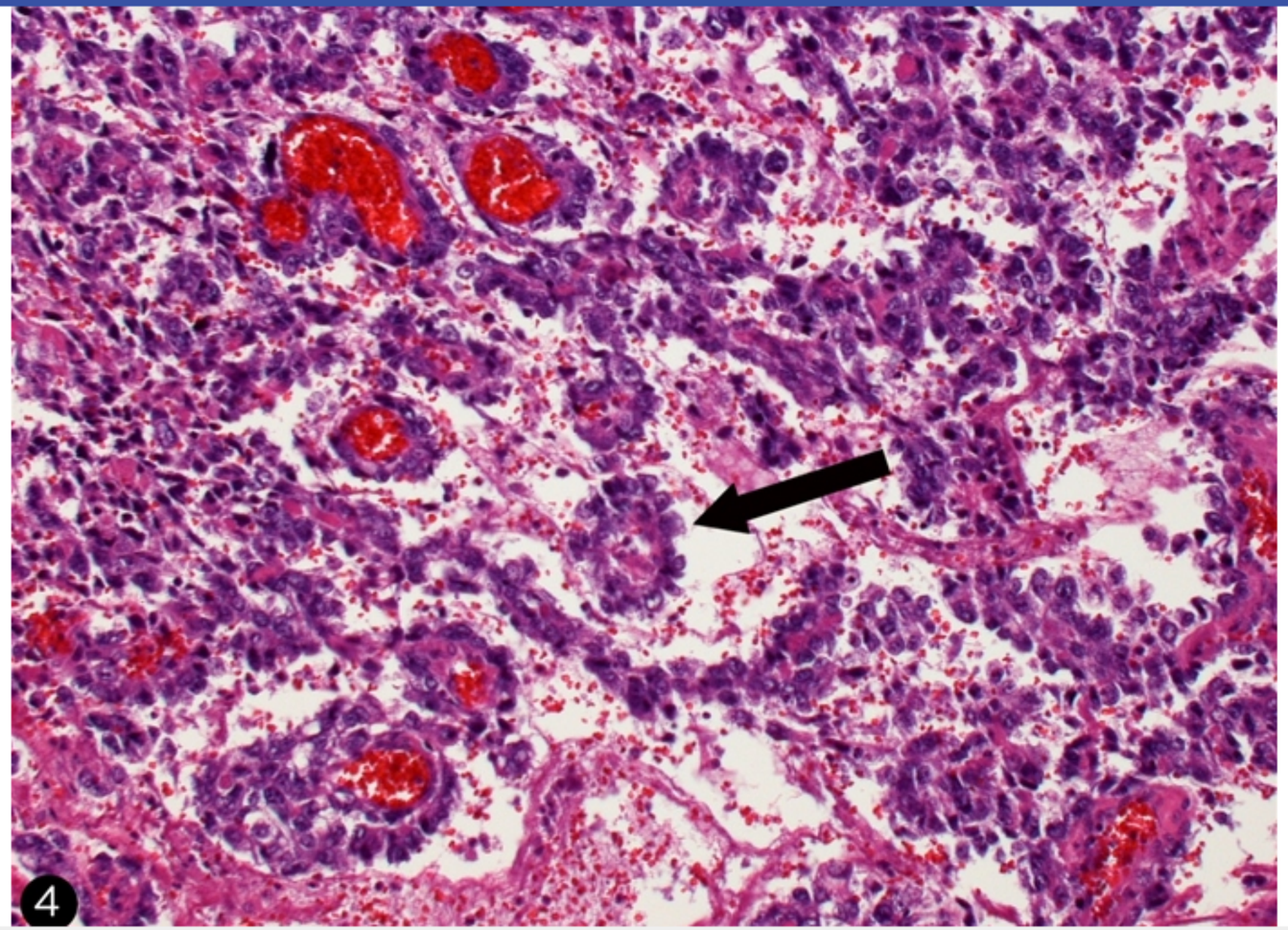

Zoom In | Zoom Out | Reset | Add To New Card | Existing Card

Block Time Remaining: 00:01:17
TUTOR

5 | Feedback | Suspend | End Block

Settings

1 2 3 4 5 6 7 8 9 10 11 12 13 14 15 16 17 18 19 20 21 22 23 24 25 26 27 28 29 30

Item 14 of 32
Question Id: 1837

Mark | Previous | Next | Full Screen | Tutorial | Lab Values | Notes | Calculator | Reverse Color | Text Zoom | Settings

common subtype and is associated with increased levels of cancer antigen 125 **(CA-125)**

Exhibit Display

Zoom In | Zoom Out | Reset | Add To New Card | Existing Card

Block Time Remaining: 00:01:17
TUTOR

5 | Feedback | Suspend | End Block

Settings

1 2 3 4 5 6 7 8 9 10 11 12 13 14 15 16 17 18 19 20 21 22 23 24 25 26 27 28 29 30

Item 14 of 32
Question Id: 1837

Mark | Previous | Next | Full Screen | Tutorial | Lab Values | Notes | Calculator | Reverse Color | Text Zoom | Settings

common subtype and is associated with increased levels of cancer antigen 125 **(CA-125)**

Exhibit Display

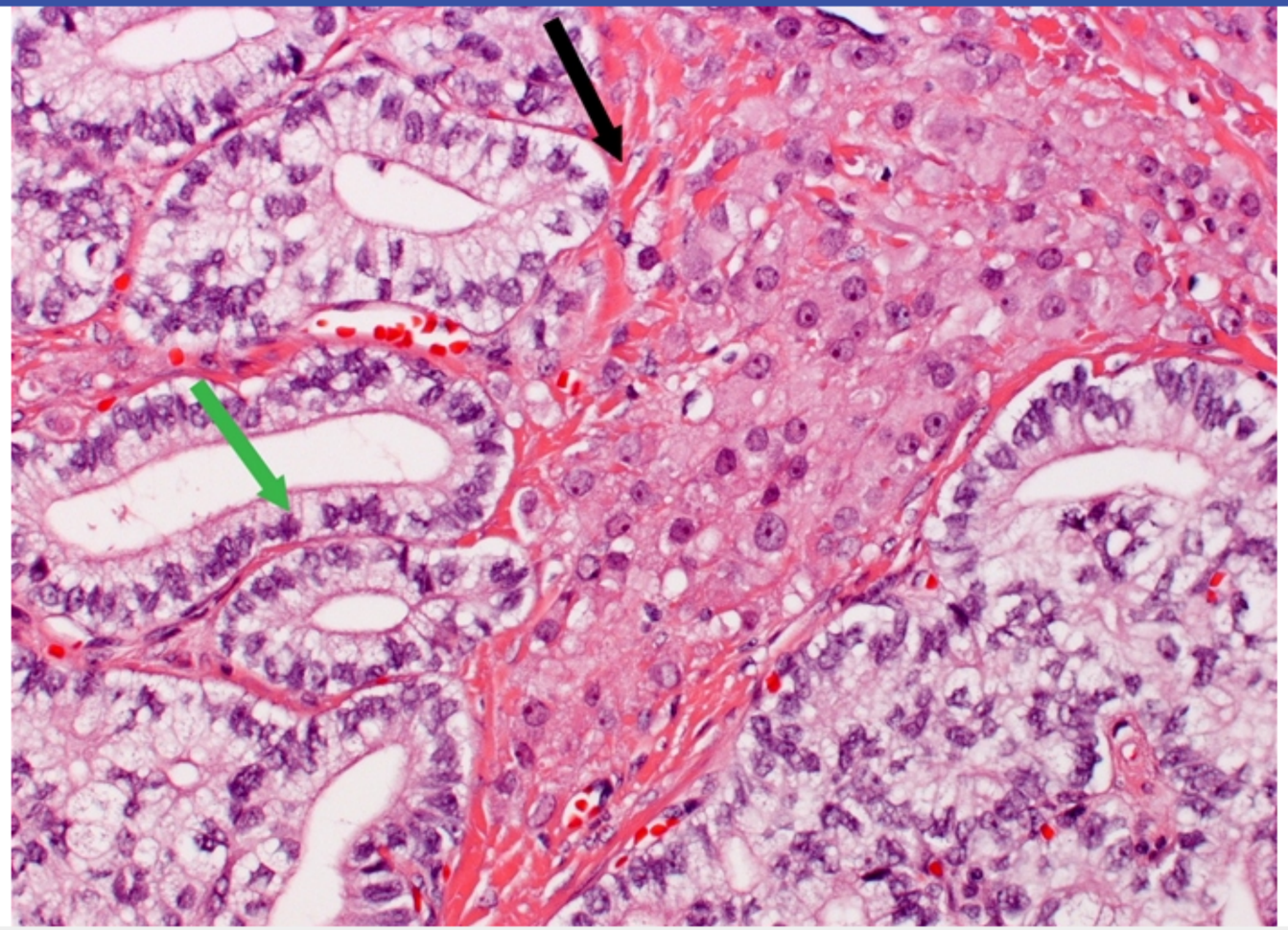

Zoom In | Zoom Out | Reset | Add To New Card | Existing Card

Block Time Remaining: 00:01:17
TUTOR

5 | Feedback | Suspend | End Block

bodies.

(Choice A) Serum α-fetoprotein levels may be increased in patients with hepatocellular carcinoma and ovarian germ cell tumors (eg, endodermal sinus [yolk sac] tumor). Endodermal sinus tumors of the ovary demonstrate Schiller-Duval bodies, which resemble glomeruli (arrow).

(Choices B and F) β-hCG is elevated in normal pregnancy, gestational trophoblastic disease (eg, molar pregnancy, gestational choriocarcinoma), and germ cell tumors (eg, non-gestational choriocarcinoma, dysgerminomas). Dysgerminomas may also secrete LDH and have distinctive "fried egg cells" with a large round nucleus surrounded by clear cytoplasm.

(Choices D and E) Granulosa cell tumors of the ovary are sex cord stromal neoplasms that secrete estrogen, along with inhibin. Pathology findings include Call-Exner bodies with atypical granulosa cells containing coffee bean nuclei (arrows).

(Choice G) Testosterone is secreted by Sertoli-Leydig cell tumors of the ovary. These rare sex cord stromal neoplasms typically appear as tubules composed of Sertoli cells (green arrow) with interspersed eosinophilic Leydig cells and surrounding fibrous stroma (black arrow).

Educational objective:
Epithelial ovarian cancer is the most common ovarian malignancy. Histologic findings include anaplasia of epithelial cells with invasion into the stroma, along with multiple papillary formations with cellular atypia. Epithelial ovarian tumors produce CA-125, which can be used as a serum marker for this condition.

References

- Committee opinion no. 477: the role of the obstetrician-gynecologist in the early detection of epithelial ovarian cancer.
- Symptoms associated with ovarian cancer.
- Pathology of the adnexal mass.

Pathology	Female Reproductive System & Breast	Ovarian cancer
Subject	System	Topic

Copyright © UWorld. All rights reserved.

A 67-year-old man comes to the office for a routine health maintenance evaluation. He feels well and has no specific symptoms. Vital signs are within normal limits. Digital rectal examination reveals a firm prostatic nodule. The patient undergoes transrectal prostate biopsy, and microscopy reveals sheets of tumor cells infiltrating the stroma with no glandular differentiation; the tumor cells have large vesicular nuclei and prominent nucleoli. Imaging shows enlargement of several iliac lymph nodes. Which of the following is the best description of this patient's tumor?

A. Higher-Gleason score and higher stage

B. Higher-Gleason score and lower-stage

C. Lower-Gleason score and higher-stage

D. Lower-Gleason score and lower-stage

Submit

A 67-year-old man comes to the office for a routine health maintenance evaluation. He feels well and has no specific symptoms. Vital signs are within normal limits. Digital rectal examination reveals a firm prostatic nodule. The patient undergoes transrectal prostate biopsy, and microscopy reveals sheets of tumor cells infiltrating the stroma with no glandular differentiation; the tumor cells have large vesicular nuclei and prominent nucleoli. Imaging shows enlargement of several iliac lymph nodes. Which of the following is the best description of this patient's tumor?

- ✓ A. Higher-Gleason score and higher stage (68%)
- B. Higher-Gleason score and lower-stage (8%)
- C. Lower-Gleason score and higher-stage (21%)
- D. Lower-Gleason score and lower-stage (1%)

Omitted
Correct answer
A

68%
Answered correctly

01 sec
Time Spent

04/20/2020
Last Updated

Explanation

Prostate cancer is typically diagnosed by transrectal ultrasound–guided biopsy, which uses ultrasound guidance to take multiple core biopsy samples from random locations within the peripheral zone of the prostate. Subsequent histopathologic examination confirms the presence of cancer and determines the **degree of glandular architecture abnormality**, which is summarized by the **Gleason grade**.

The lowest Gleason grade of 1 is assigned to well-differentiated tumors; these tumors resemble normal prostatic tissue and are generally arranged into small, well-formed, closely packed glands. In contrast, the **highest Gleason grade of 5** is assigned to **poorly differentiated** tumors; these tumors do not resemble normal prostatic tissue and are generally arranged into **sheets of invasive cells** with **no glandular elements**. The 2 predominant Gleason grades in the core biopsies are added together to generate the Gleason score (eg, a tumor that is mostly Gleason grade 2

Explanation

Prostate cancer is typically diagnosed by transrectal ultrasound–guided biopsy, which uses ultrasound guidance to take multiple core biopsy samples from random locations within the peripheral zone of the prostate. Subsequent histopathologic examination confirms the presence of cancer and determines the **degree of glandular architecture abnormality**, which is summarized by the **Gleason grade**.

The lowest Gleason grade of 1 is assigned to well-differentiated tumors; these tumors resemble normal prostatic tissue and are generally arranged into small, well-formed, closely packed glands. In contrast, the **highest Gleason grade of 5** is assigned to **poorly differentiated** tumors; these tumors do not resemble normal prostatic tissue and are generally arranged into **sheets of invasive cells** with **no glandular elements**. The 2 predominant Gleason grades in the core biopsies are added together to generate the Gleason score (eg, a tumor that is mostly Gleason grade 3 and 4 would have a Gleason score of 7). The higher the Gleason score, the higher the risk of spread outside of the prostate.

Staging is a marker of **degree of spread** from the site of cancer origin. Low stage is seen in those with disease confined to the prostate; a higher stage is seen in those with regional (eg, lymph node) or metastatic (eg, bone) lesions. In this case, the presence of **enlarged iliac nodes** likely indicates metastases to the regional lymph nodes; therefore, he would have a **higher stage** of disease.

Educational objective:
Prostate cancer is graded by Gleason grade, which is a measure of glandular architecture disruption and risk of extra-organ spread; poorly differentiated prostate cancer (eg, no glandular structure) is assigned a high Gleason grade, whereas well-differentiated prostate cancer (eg, well-formed glandular structure) is assigned a low Gleason grade. Staging is a marker of the extent of spread from the primary cancer site; regional lymph node involvement or distant metastases indicate a higher stage of disease.

Pathology	Male Reproductive System	Prostate cancer
Subject	System	Topic

Copyright © UWorld. All rights reserved.

A 21-year-old woman, gravida 0, comes to the office due to postcoital bleeding. She has been sexually active with her male partner for 6 months. The patient has been taking birth control pills since age 15, when she first became sexually active. The patient and her partner do not use condoms and have never been diagnosed with a sexually transmitted infection. The patient smokes a pack of cigarettes per day. Bimanual examination reveals a small mobile uterus and no cervical motion tenderness. Speculum examination shows a well-estrogenized vagina without lesions. The cervix has an area of erythema surrounding the external os and scant clear discharge. She has her first Papanicolaou smear, and the cytological finding is shown in the image below.

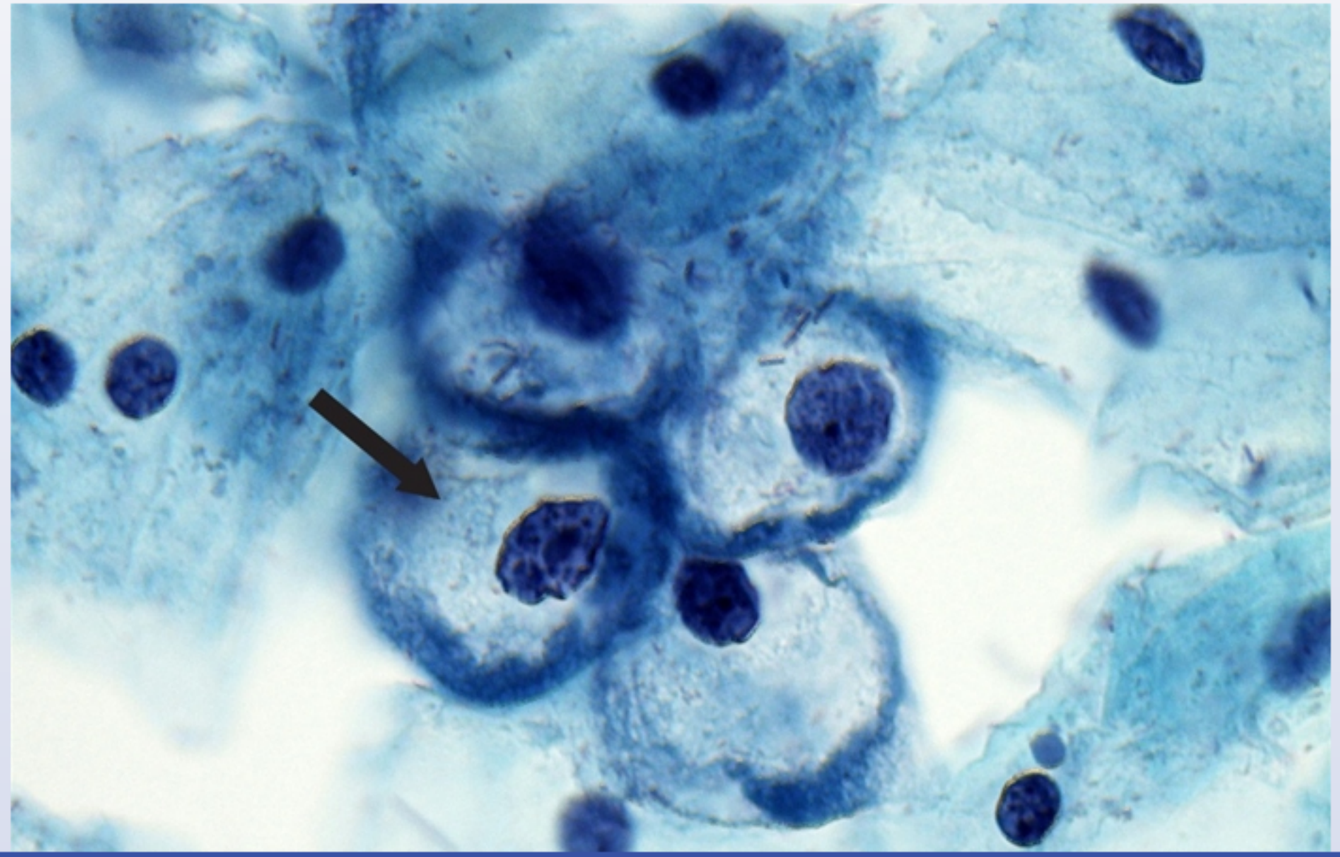

Settings

1 2 3 4 5 6 7 8 9 10 11 12 13 14 15 16 17 18 19 20 21 22 23 24 25 26 27 28 29 30

Item 16 of 32
Question Id: 1015

Mark | Previous | Next | Full Screen | Tutorial | Lab Values | Notes | Calculator | Reverse Color | Text Zoom | Settings

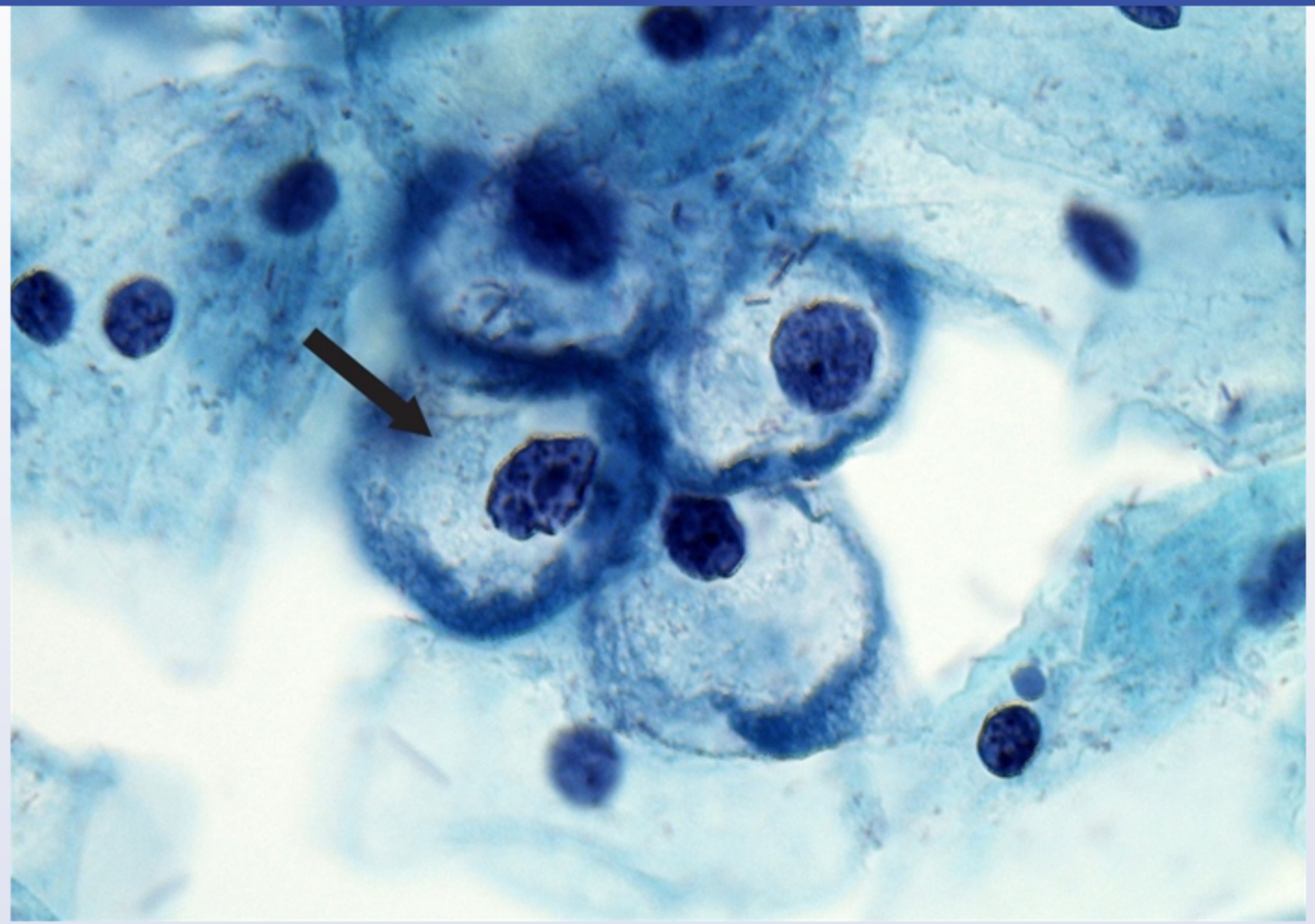

Which of the following best describes the finding shown on this patient's slide?

A. *Actinomyces*-like organisms

B. *Candida albicans*

Block Time Remaining: 00:01:22
TUTOR

8 | Feedback | Suspend | End Block

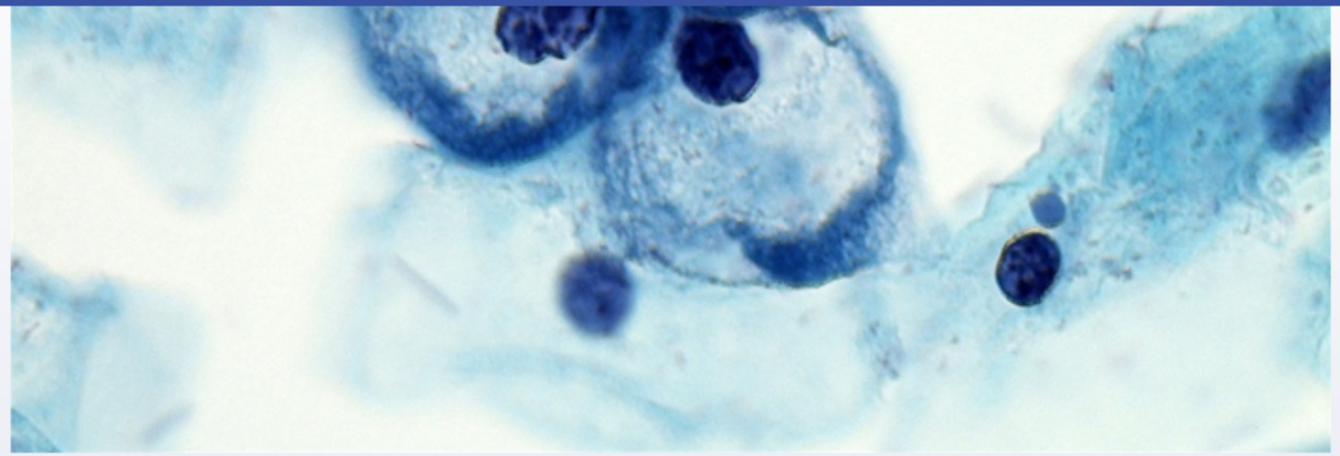

Which of the following best describes the finding shown on this patient's slide?

- A. *Actinomyces*-like organisms
- B. *Candida albicans*
- C. Clue cell
- D. Endometrial cell
- E. Glandular cell
- F. Koilocyte
- G. Parabasal cell

Submit

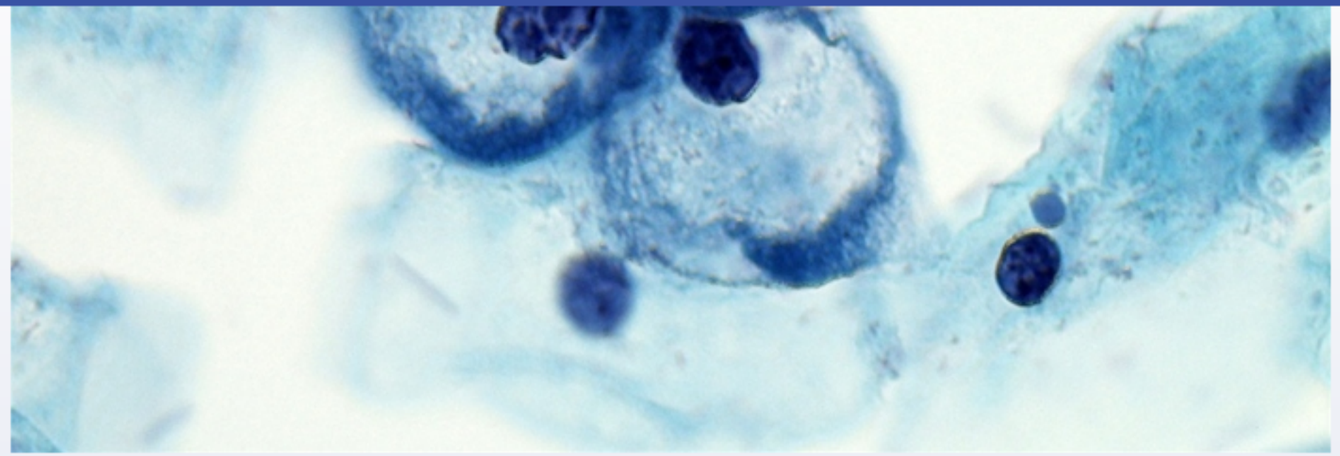

Which of the following best describes the finding shown on this patient's slide?

- A. *Actinomyces*-like organisms (1%)
- B. *Candida albicans* (0%)
- C. Clue cell (25%)
- D. Endometrial cell (2%)
- E. Glandular cell (1%)
- ✓ F. Koilocyte (67%)
- G. Parabasal cell (1%)

Omitted
Correct answer

67%
Answered correctly

07 secs
Time Spent

04/26/2020
Last Updated

Explanation

HPV strains	Presentation
1-4	Skin warts (verruca vulgaris)
6, 11	Genital warts (condylomata acuminata)
16, 18	Cervical, vaginal, vulvar & anal neoplasia

HPV= human papillomavirus.

©UWorld

This patient's Papanicolaou (Pap) smear shows a **koilocyte**, a sign of **human papillomavirus (HPV)** infection. A koilocyte is an immature squamous cell with dense, irregularly staining cytoplasm and perinuclear clearing, resulting in a halo. It also has an enlarged pyknotic nucleus where the chromatin has condensed as part of the apoptosis process, giving it a "raisinoid" appearance.

HPV is a **double-stranded, non-enveloped DNA virus** that has a predilection for squamous epithelium of the **skin** and **vagina/cervix**. Infection with HPV may present as **warts** or **intraepithelial neoplasia**, as shown in the table above. Oncogenesis from HPV strains (eg, 16, 18) is attributed to viral proteins E6 and E7. E6 degrades p53 (tumor suppressor protein regulating the cell cycle) and E7 inhibits the retinoblastoma gene product Rb. Smoking increases the likelihood of an HPV infection developing into intraepithelial neoplasia and cancer.

(Choice A) *Actinomyces*-like organisms (black arrow) appear as clusters of basophilic thin filaments that resemble "cotton candy" on a Pap smear; their presence can be an incidental finding in patients with intrauterine devices.

(Choice B) *Candida albicans* is part of normal flora in many asymptomatic women. The organism can appear as pseudohyphae of budding yeast on a Pap smear.

(Choice C) Clue cells are seen in Pap smears in the setting of bacterial vaginosis, which involves a change in vaginal flora from lactobacilli to

HPV is a **double-stranded, non-enveloped DNA virus** that has a predilection for squamous epithelium of the **skin** and **vagina/cervix**. Infection with HPV may present as **warts** or **intraepithelial neoplasia**, as shown in the table above. Oncogenesis from HPV strains (eg, 16, 18) is attributed to viral proteins E6 and E7. E6 degrades p53 (tumor suppressor protein regulating the cell cycle) and E7 inhibits the retinoblastoma gene product Rb. Smoking increases the likelihood of an HPV infection developing into intraepithelial neoplasia and cancer.

(Choice A) *Actinomyces*-like organisms (black arrow) appear as clusters of basophilic thin filaments that resemble "cotton candy" on a Pap smear; their presence can be an incidental finding in patients with intrauterine devices.

(Choice B) *Candida albicans* is part of normal flora in many asymptomatic women. The organism can appear as pseudohyphae of budding yeast on a Pap smear.

(Choice C) Clue cells are seen in Pap smears in the setting of bacterial vaginosis, which involves a change in vaginal flora from lactobacilli to anaerobic gram-negative rods (eg, *Gardnerella vaginalis*). Clue cells are squamous cells covered with rods to obscure normal epithelial margins.

(Choices D and E) The endometrium consists of simple tubular glands within stroma. These cells resemble histiocytes and have small dark nuclei and no perinuclear clearing. They may be present on a Pap smear during menses. Glandular endocervical cells (black arrow) are columnar cells with a vacuolated or granular cytoplasm and prominent cell borders that form a honeycomb pattern when in clusters. Their presence in a Pap smear indicates adequate sampling.

(Choice G) Parabasal cells are round cells with a basophilic cytoplasm, finely granular chromatin in their nuclei, no visible nucleoli, and a high nucleus-to-chromatin ratio ("fried eggs" with a large "central egg yolk"). They predominate in Pap smears from postmenopausal and postpartum women.

Educational objective:
Human papillomavirus (HPV) infection causes cutaneous and genital warts as well as benign and malignant intraepithelial neoplasia. Koilocytosis is a hallmark sign of HPV infection. Koilocytes are pyknotic, superficial or immature squamous cells with a dense, irregularly staining cytoplasm and perinuclear halo-like clearing.

References

- Clinicopathological study of Papanicolaou (Pap) smears for diagnosing of cervical infections.

Settings

1 2 3 4 5 6 7 8 9 10 11 12 13 14 15 16 17 18 19 20 21 22 23 24 25 26 27 28 29 30

Item 16 of 32
Question Id: 1015

Mark | Previous | Next | Full Screen | Tutorial | Lab Values | Notes | Calculator | Reverse Color | Text Zoom | Settings

Exhibit Display

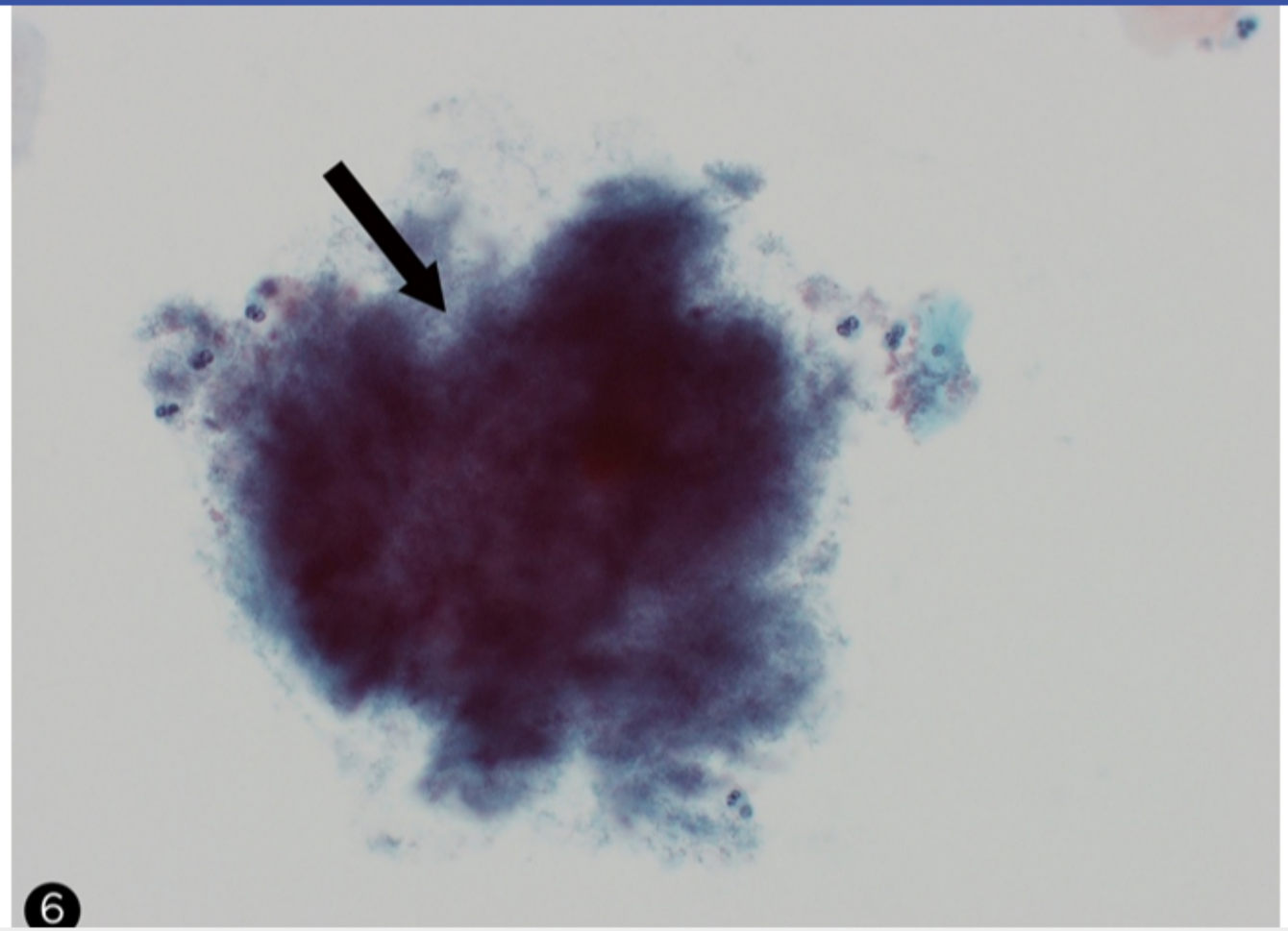

Zoom In | Zoom Out | Reset | Add To New Card | Existing Card

- Clinicopathological study of Papanicolaou (Pap) smears for diagnosing of cervical infections.

Block Time Remaining: 00:01:25
TUTOR

8 | Feedback | Suspend | End Block

Settings

1
2
3
4
5
6
7
8
9
10
11
12
13
14
15
16
17
18
19
20
21
22
23
24
25
26
27
28
29
30

Item 16 of 32
Question Id: 1015

Mark | Previous | Next | Full Screen | Tutorial | Lab Values | Notes | Calculator | Reverse Color | Text Zoom | Settings

Exhibit Display

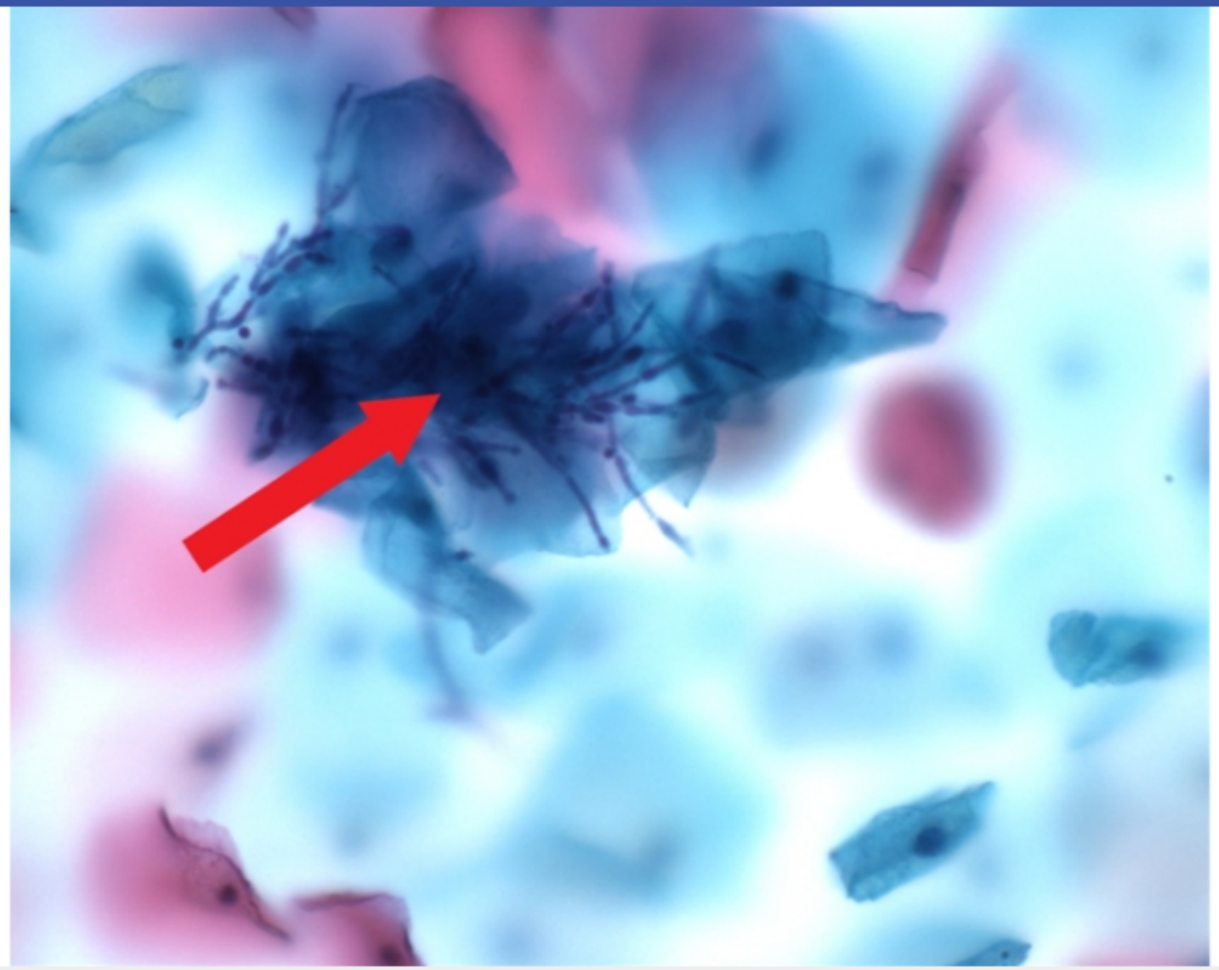

Zoom In | Zoom Out | Reset | Add To New Card | Existing Card

- Clinicopathological study of Papanicolaou (Pap) smears for diagnosing of cervical infections.

Block Time Remaining: 00:01:25
TUTOR

8 | Feedback | Suspend | End Block

1 2 3 4 5 6 7 8 9 10 11 12 13 14 15 16 17 18 19 20 21 22 23 24 25 26 27 28 29 30

Exhibit Display

Bacterial vaginosis

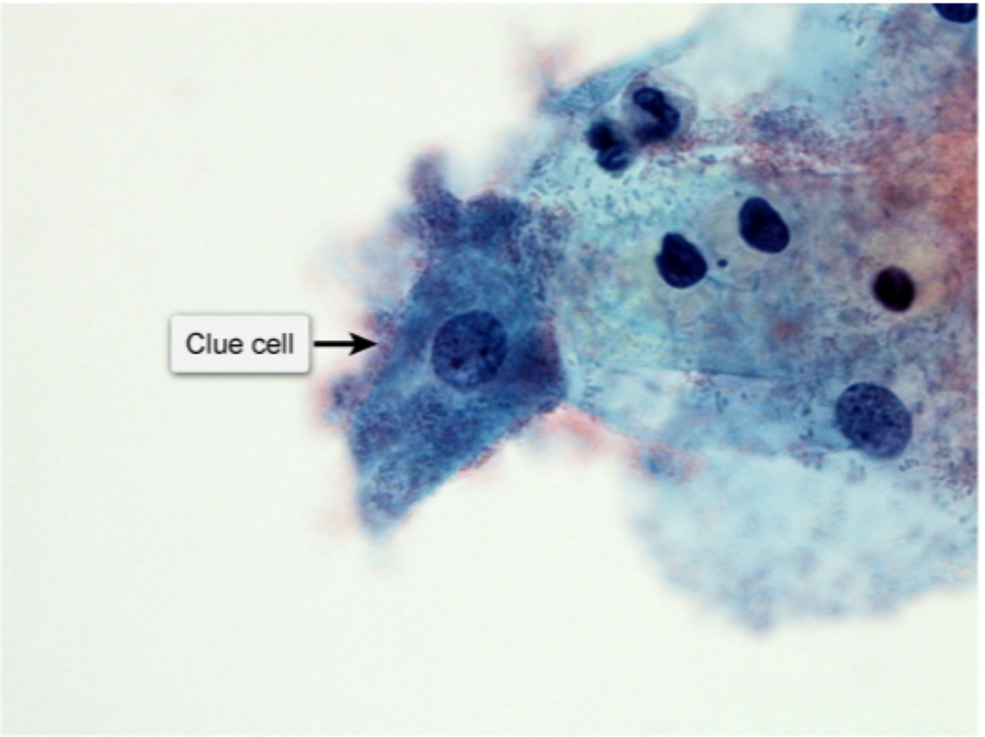

©UWorld

Zoom In | Zoom Out | Reset | Add To New Card | Existing Card

- Clinicopathological study of Papanicolaou (Pap) smears for diagnosing of cervical infections.

Settings

1
2
3
4
5
6
7
8
9
10
11
12
13
14
15
16
17
18
19
20
21
22
23
24
25
26
27
28
29
30

Item 16 of 32
Question Id: 1015

Mark | Previous | Next | Full Screen | Tutorial | Lab Values | Notes | Calculator | Reverse Color | Text Zoom | Settings

Exhibit Display

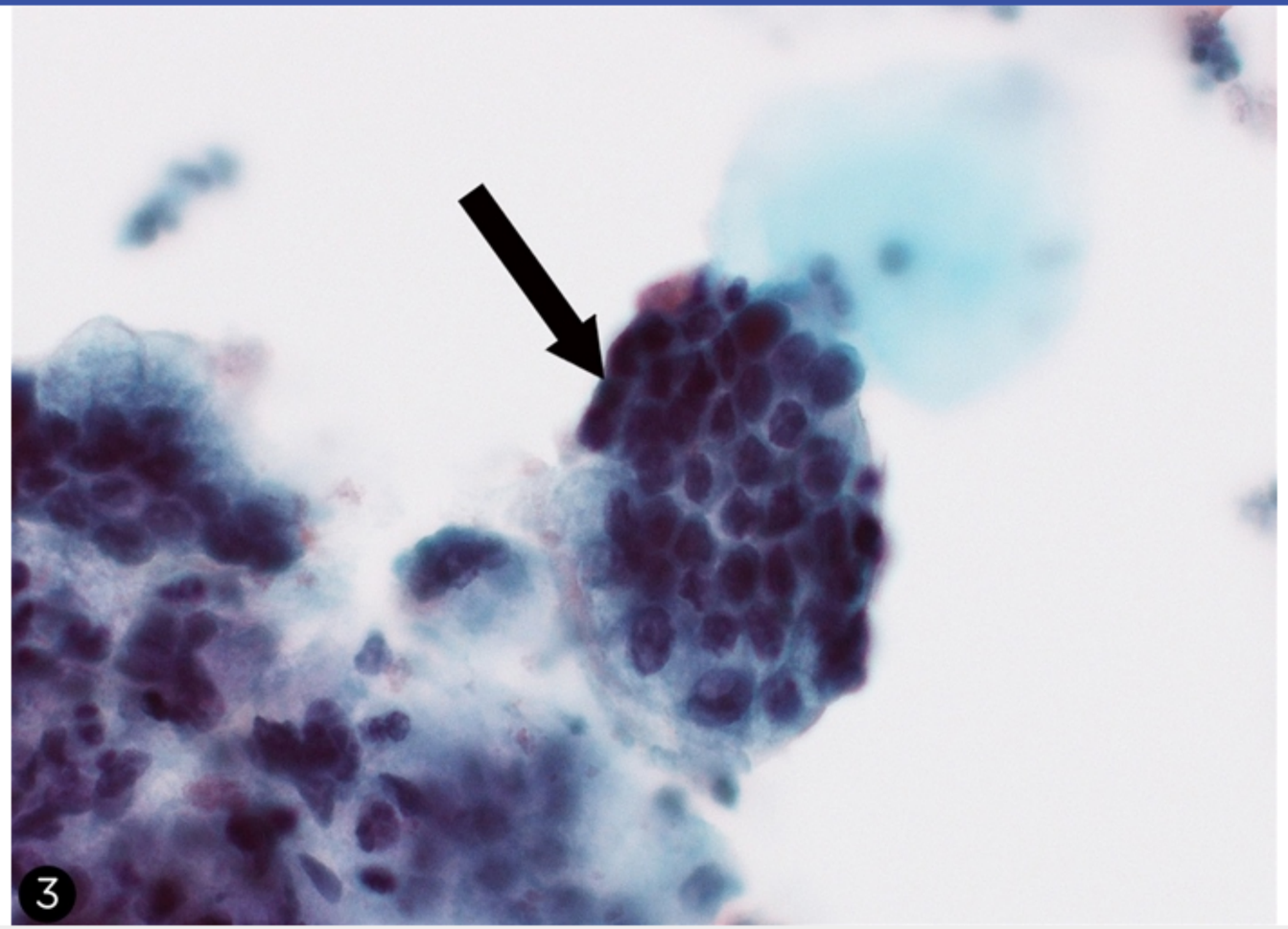

Zoom In | Zoom Out | Reset | Add To New Card | Existing Card

- Clinicopathological study of Papanicolaou (Pap) smears for diagnosing of cervical infections.

Block Time Remaining: 00:01:25
TUTOR

8 | Feedback | Suspend | End Block

(Choice A) *Actinomyces*-like organisms (black arrow) appear as clusters of basophilic thin filaments that resemble "cotton candy" on a Pap smear; their presence can be an incidental finding in patients with intrauterine devices.

(Choice B) *Candida albicans* is part of normal flora in many asymptomatic women. The organism can appear as pseudohyphae of budding yeast on a Pap smear.

(Choice C) Clue cells are seen in Pap smears in the setting of bacterial vaginosis, which involves a change in vaginal flora from lactobacilli to anaerobic gram-negative rods (eg, *Gardnerella vaginalis*). Clue cells are squamous cells covered with rods to obscure normal epithelial margins.

(Choices D and E) The endometrium consists of simple tubular glands within stroma. These cells resemble histiocytes and have small dark nuclei and no perinuclear clearing. They may be present on a Pap smear during menses. Glandular endocervical cells (black arrow) are columnar cells with a vacuolated or granular cytoplasm and prominent cell borders that form a honeycomb pattern when in clusters. Their presence in a Pap smear indicates adequate sampling.

(Choice G) Parabasal cells are round cells with a basophilic cytoplasm, finely granular chromatin in their nuclei, no visible nucleoli, and a high nucleus-to-chromatin ratio ("fried eggs" with a large "central egg yolk"). They predominate in Pap smears from postmenopausal and postpartum women.

Educational objective:
Human papillomavirus (HPV) infection causes cutaneous and genital warts as well as benign and malignant intraepithelial neoplasia. Koilocytosis is a hallmark sign of HPV infection. Koilocytes are pyknotic, superficial or immature squamous cells with a dense, irregularly staining cytoplasm and perinuclear halo-like clearing.

References

- Clinicopathological study of Papanicolaou (Pap) smears for diagnosing of cervical infections.

Pathology	Female Reproductive System & Breast	Human papilloma virus
Subject	System	Topic

Copyright © UWorld. All rights reserved.

Settings

1
2
3
4
5
6
7
8
9
10
11
12
13
14
15
16
17
18
19
20
21
22
23
24
25
26
27
28
29
30

Item 17 of 32
Question Id: 16001

Mark | Previous | Next | Full Screen | Tutorial | Lab Values | Notes | Calculator | Reverse Color | Text Zoom | Settings

Exhibit Display

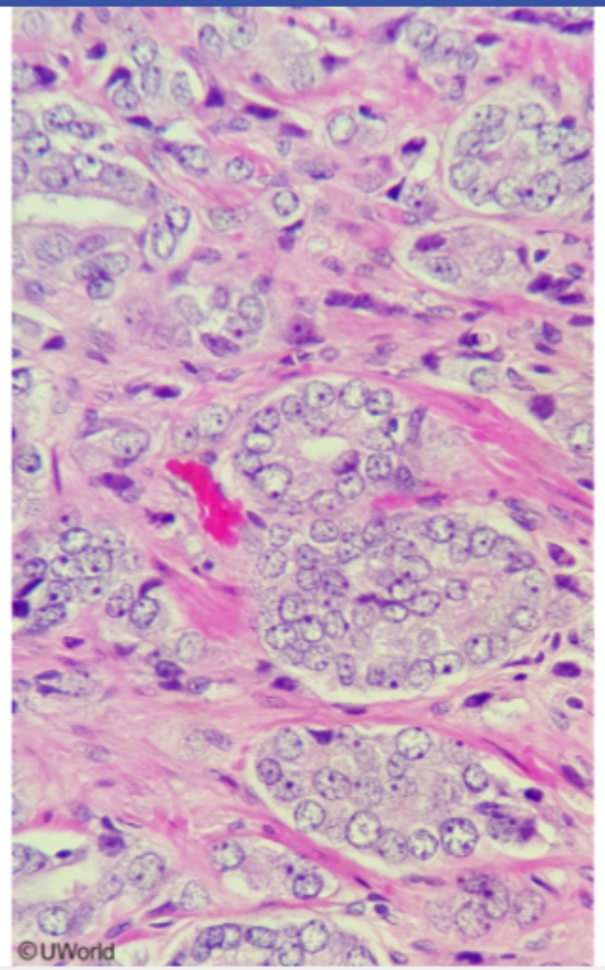

Zoom In | Zoom Out | Reset | Add To Flash Card

Block Time Remaining: 00:02:17
TUTOR

0 | Feedback | Suspend | End Block

A 66-year-old man comes to the office due to 2 episodes of hematuria over the past month. Digital rectal examination reveals an indurated prostate with no palpable nodules. An image from a transrectal prostate biopsy is shown in the exhibit. Which of the following is the most likely underlying cause of this patient's symptoms?

A. Acute bacterial infection of the prostate (4%)

B. Benign hyperplasia of the prostatic stroma (21%)

C. Chronic bacterial inflammation of the prostate (13%)

D. Invasive carcinoma arising from the urethra (9%)

✓ E. Neoplastic proliferation of prostate gland cells (51%)

Omitted
Correct answer
E

51%
Answered correctly

55 secs
Time Spent

05/01/2020
Last Updated

Explanation

Normal prostate | **Prostate adenocarcinoma**

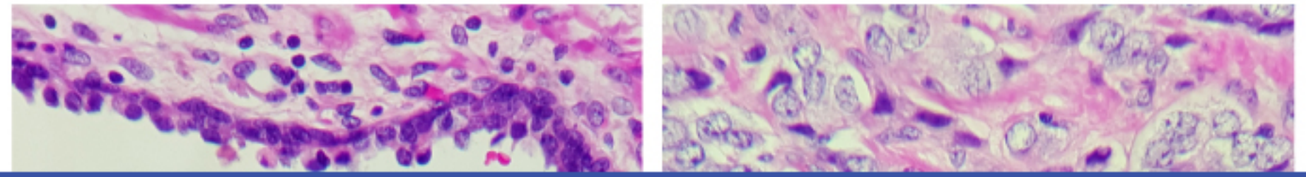

Normal prostate | **Prostate adenocarcinoma**

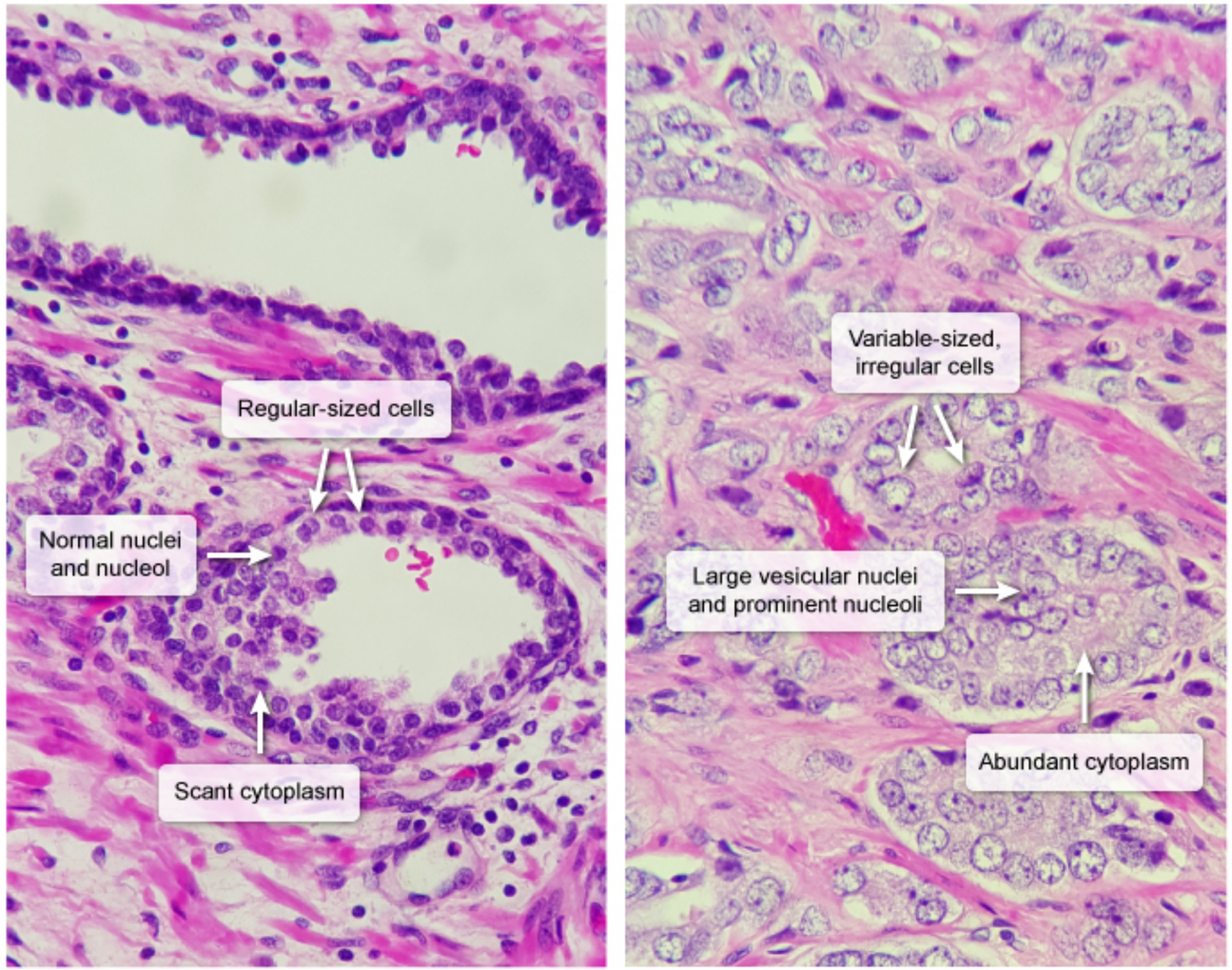

©UWorld

This older man with an indurated prostate has histopathologic evidence of atypical glandular cells with large nuclei and prominent nucleoli, raising strong suspicion for **prostate adenocarcinoma**. Because most cases of prostate cancer arise in the periphery of the gland (peripheral zone) far from the prostatic portion of the urethra, patients do not typically present with urinary symptoms. However, a minority of cases occur in the portion of the gland (transition zone) that abuts the urethra, which can lead to **hematuria** and/or obstructive voiding manifestations.

Diagnostic evaluation begins with **digital rectal examination**; patients with prostate cancer often have an **indurated** (ie, abnormally firm), nontender gland with or without a nodule. An elevated prostate-specific antigen level adds supporting evidence. Confirmation is typically made by transrectal prostate biopsy, in which 10-12 random core biopsies of the gland are obtained. In contrast to normal prostatic cells, which are small, organized, and glandular, cancer cells typically display varying degrees of cellular atypia, including disorganized or no glandular structure, enlarged nuclei, and prominent nucleoli.

(Choices A and C) Acute prostatitis typically causes systemic symptoms (eg, fever, malaise), dysuria, and a tender, boggy prostate on digital rectal examination. Chronic prostatitis is generally marked by perineal pain and recurrent symptoms of urinary tract infection. Although patients can have hematuria with these conditions, biopsy would show inflammatory, not atypical glandular, cells.

(Choice B) Benign prostatic hyperplasia is common in older men. Hyperplasia of prostatic stroma in the area of the prostate that surrounds the urethra generally results in voiding symptoms (eg, hesitancy, dribbling, frequency). Hematuria may occasionally occur. Digital rectal examination generally reveals a symmetrically enlarged prostate with no nodules. Biopsy would show extensive stromal hyperplasia, not atypical glands.

(Choice D) Urothelial carcinoma from the bladder or urethra can occasionally invade the prostate. Although this cancer often causes hematuria, biopsy typically shows cancerous uroepithelial cells, not atypical glands. Furthermore, prostate cancer is a far more common cause of an indurated prostate with atypical glandular cells than a urothelial tumor invading the prostate.

Educational objective:
Prostate adenocarcinoma is generally diagnosed with transrectal prostate biopsy, which usually reveals atypical glandular cells with enlarged nuclei and prominent nucleoli. In contrast, normal prostate cells are small and glandular with scant cytoplasm, small nuclei, and normal nucleoli.

Pathology	Male Reproductive System	Prostate cancer
Subject	System	Topic

Settings

1
2
3
4
5
6
7
8
9
10
11
12
13
14
15
16
17
18
19
20
21
22
23
24
25
26
27
28
29
30

Item 17 of 32
Question Id: 16001

Mark

Previous | Next | Full Screen | Tutorial | Lab Values | Notes | Calculator | Reverse Color | Text Zoom | Settings

Exhibit Display

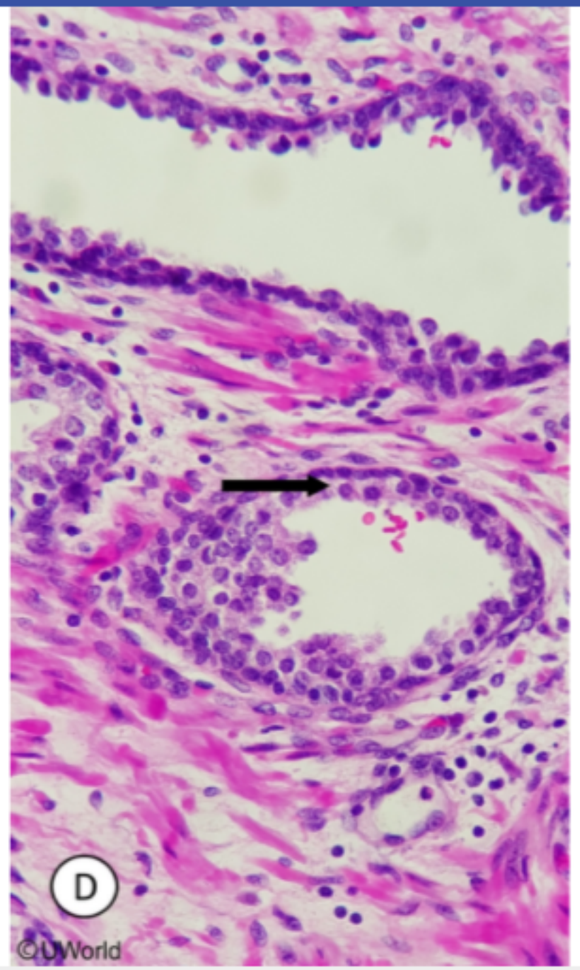

Zoom In | Zoom Out | Reset | Add To Flash Card

Subject System Topic

Block Time Remaining: 00:02:20
TUTOR

0 | Feedback | Suspend | End Block

strong suspicion for **prostate adenocarcinoma**. Because most cases of prostate cancer arise in the periphery of the gland (peripheral zone) far from the prostatic portion of the urethra, patients do not typically present with urinary symptoms. However, a minority of cases occur in the portion of the gland (transition zone) that abuts the urethra, which can lead to **hematuria** and/or obstructive voiding manifestations.

Diagnostic evaluation begins with **digital rectal examination**; patients with prostate cancer often have an **indurated** (ie, abnormally firm), nontender gland with or without a nodule. An elevated prostate-specific antigen level adds supporting evidence. Confirmation is typically made by transrectal prostate biopsy, in which 10-12 random core biopsies of the gland are obtained. In contrast to normal prostatic cells, which are small, organized, and glandular, cancer cells typically display varying degrees of cellular atypia, including disorganized or no glandular structure, enlarged nuclei, and prominent nucleoli.

(Choices A and C) Acute prostatitis typically causes systemic symptoms (eg, fever, malaise), dysuria, and a tender, boggy prostate on digital rectal examination. Chronic prostatitis is generally marked by perineal pain and recurrent symptoms of urinary tract infection. Although patients can have hematuria with these conditions, biopsy would show inflammatory, not atypical glandular, cells.

(Choice B) Benign prostatic hyperplasia is common in older men. Hyperplasia of prostatic stroma in the area of the prostate that surrounds the urethra generally results in voiding symptoms (eg, hesitancy, dribbling, frequency). Hematuria may occasionally occur. Digital rectal examination generally reveals a symmetrically enlarged prostate with no nodules. Biopsy would show extensive stromal hyperplasia, not atypical glands.

(Choice D) Urothelial carcinoma from the bladder or urethra can occasionally invade the prostate. Although this cancer often causes hematuria, biopsy typically shows cancerous uroepithelial cells, not atypical glands. Furthermore, prostate cancer is a far more common cause of an indurated prostate with atypical glandular cells than a urothelial tumor invading the prostate.

Educational objective:
Prostate adenocarcinoma is generally diagnosed with transrectal prostate biopsy, which usually reveals atypical glandular cells with enlarged nuclei and prominent nucleoli. In contrast, normal prostate cells are small and glandular with scant cytoplasm, small nuclei, and normal nucleoli.

Pathology	Male Reproductive System	Prostate cancer
Subject	System	Topic

Copyright © UWorld. All rights reserved.

A 21-day-old boy is brought to the office by his mother because of a palpable bulge in the child's neck. He continues to feed well but appears comfortable only when held with his body sideways under the breast. He is at the 50th percentile for height, weight, and head circumference. The child favors looking toward the right and cries when his head is turned to the left. There is a firm mass on the left side of his neck that does not move when the child swallows. The remainder of the examination is unremarkable. Which of the following conditions was most likely present prenatally?

- A. Folate deficiency
- B. Intrauterine malposition
- C. Defective fetal collagen synthesis
- D. Maternal alcohol consumption
- E. Upper respiratory infection in the mother

Submit

A 21-day-old boy is brought to the office by his mother because of a palpable bulge in the child's neck. He continues to feed well but appears comfortable only when held with his body sideways under the breast. He is at the 50th percentile for height, weight, and head circumference. The child favors looking toward the right and cries when his head is turned to the left. There is a firm mass on the left side of his neck that does not move when the child swallows. The remainder of the examination is unremarkable. Which of the following conditions was most likely present prenatally?

- A. Folate deficiency (12%)
- ✓ B. Intrauterine malposition (47%)
- C. Defective fetal collagen synthesis (15%)
- D. Maternal alcohol consumption (9%)
- E. Upper respiratory infection in the mother (13%)

Omitted
Correct answer
B

47%
Answered correctly

02 secs
Time Spent

04/09/2020
Last Updated

Explanation

Congenital torticollis

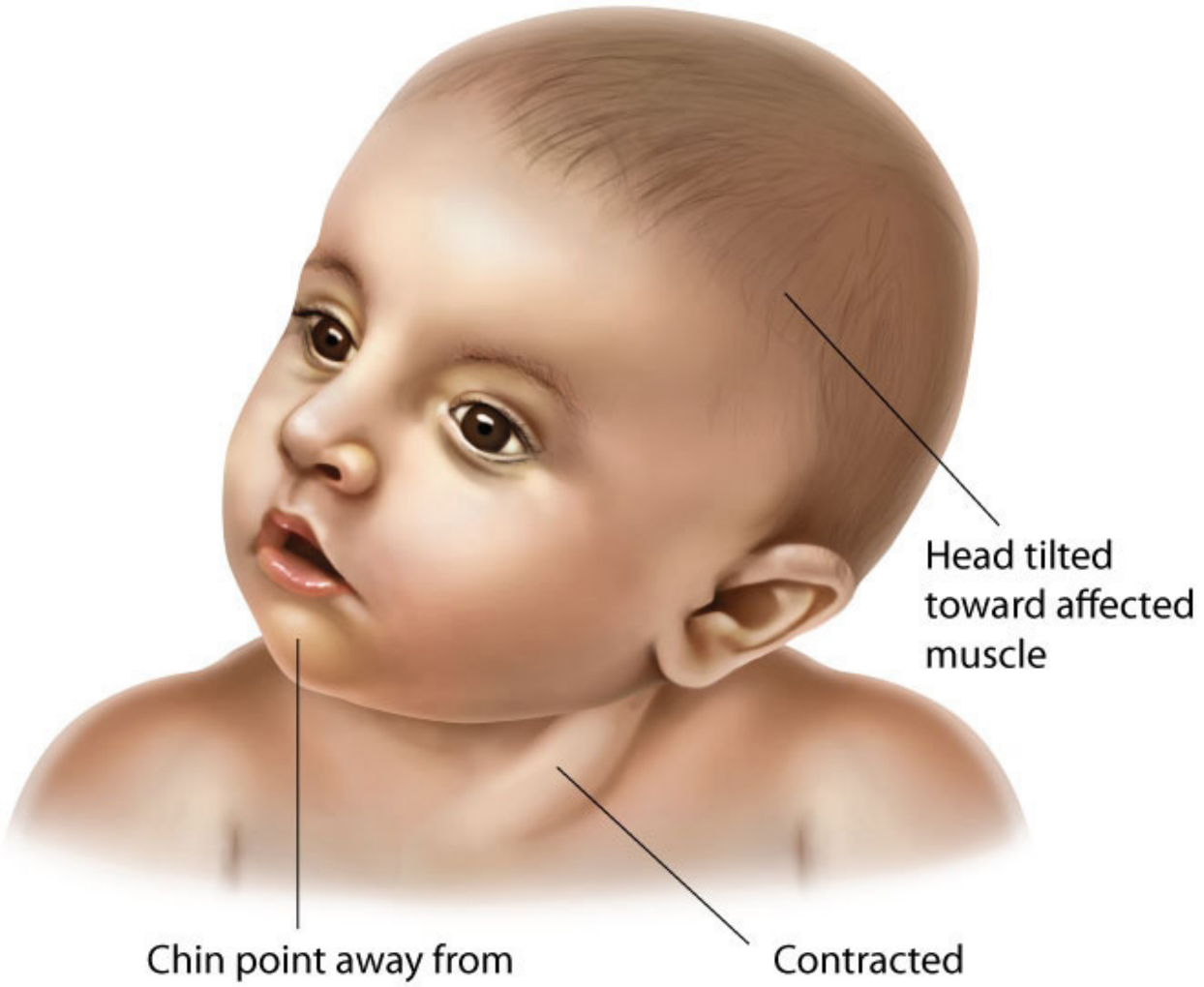

©UWorld

This infant has **congenital torticollis**, which typically develops by 2 to 4 weeks of age. It is most commonly caused by **birth trauma** (eg, breech delivery) or **malposition** of the head in utero (eg, due to fetal macrosomia or oligohydramnios), both of which can result in **sternocleidomastoid muscle (SCM) injury** and fibrosis. Children with congenital torticollis may have additional musculoskeletal anomalies, including hip dysplasia, metatarsus adductus (ie, adduction of the forefoot), and talipes equinovarus (ie, clubfoot).

The diagnosis of congenital torticollis is made clinically. On physical examination, the **head is tilted toward** the affected side with the **chin pointed away** from the contracture. A soft-tissue **mass** may be palpable in the inferior one-third of the affected SCM. Plagiocephaly and facial asymmetry may be seen in severe cases. Most cases resolve with conservative therapy and stretching exercises.

(Choice A) Folate deficiency during the first trimester of pregnancy is associated with fetal neural tube defects (eg, spina bifida).

(Choice C) Defective collagen synthesis causes osteogenesis imperfecta (brittle bone disease). Patients with the lethal variety usually die in utero or in early infancy due to severe fractures, pulmonary failure, or intracerebral hemorrhage.

(Choice D) Alcohol consumption during pregnancy can cause fetal alcohol syndrome. Affected infants have poor growth, functional developmental deficits, and characteristic facial abnormalities including a smooth philtrum, thin vermilion border, and small palpebral fissures.

(Choice E) The majority of upper respiratory infections in pregnancy are benign. However, rubella, one of the TORCH infections, is transmitted by the respiratory route and can cause severe birth defects, including hearing loss, cataracts, and congenital heart defects.

Educational objective:
Congenital torticollis is typically noted by 2 to 4 weeks of age, after which the child prefers to hold the head tilted to one side. It is most commonly the result of malposition of the head in utero or birth trauma. Most cases resolve with conservative therapy and stretching exercises.

References

- Torticollis in infants and children: common and unusual causes.

Pathology	Pregnancy, Childbirth & Puerperium	Torticollis
Subject	System	Topic

A 33-year-old nulligravid woman comes to the office for evaluation of infertility. She has never been pregnant despite years of unprotected intercourse with her husband. She also has a history of pelvic pain, which worsens with menses. The pain has persisted despite medical therapy and is suspected to be due to endometriosis. Exploratory laparoscopy is performed, and multiple flesh-colored nodules are present on the pelvic organs, along with thin, filmy adhesions. In addition to having endometrial glands with hemosiderin pigment, one of the biopsies contains simple cuboidal epithelial cells. Which of the following is the most likely site of the biopsy?

- A. Cervix
- B. Endometrium
- C. Fallopian tube
- D. Ovary
- E. Peritoneum
- F. Vagina

Submit

A 33-year-old nulligravid woman comes to the office for evaluation of infertility. She has never been pregnant despite years of unprotected intercourse with her husband. She also has a history of pelvic pain, which worsens with menses. The pain has persisted despite medical therapy and is suspected to be due to endometriosis. Exploratory laparoscopy is performed, and multiple flesh-colored nodules are present on the pelvic organs, along with thin, filmy adhesions. In addition to having endometrial glands with hemosiderin pigment, one of the biopsies contains simple cuboidal epithelial cells. Which of the following is the most likely site of the biopsy?

- A. Cervix (12%)
- B. Endometrium (6%)
- C. Fallopian tube (14%)
- ✓ D. Ovary (58%)
- E. Peritoneum (5%)
- F. Vagina (2%)

Omitted
Correct answer
D

58%
Answered correctly

02 secs
Time Spent

06/03/2020
Last Updated

Explanation

Epithelia of the female reproductive tract

Epithelia of the female reproductive tract

Organ	Type	Key features
Ovary	Simple cuboidal (eg, germinal)	• Rapidly proliferate to repair ovulatory surface defects
Fallopian tube	Simple columnar	• Ciliated cells transport egg/embryo • Damage can cause infertility, hydrosalpinx, ectopic pregnancy
Uterus	Simple columnar (eg, endometrium)	• Stratum functionalis sloughs off during menstruation • Prolonged estrogen exposure prevents shedding, resulting in hyperplasia/malignancy
Cervix	Ectocervix: stratified squamous non-keratinized Endocervix: simple columnar	• Cervical glands secrete mucus: ○ Thin and watery during ovulation ○ Mucus plug in pregnancy • HPV infection predisposes to cervical malignancy
Vagina	Stratified squamous non-keratinized	• Maintains acidic environment to prevent infection

The normal uterine mucosa (endometrium) is composed of simple columnar epithelium **(Choice B)**, tubular glands, and stroma (connective tissue). Endometriosis is an important cause of chronic pain and infertility and is due to endometrial cells **implanted** on various pelvic organs, most commonly the ovary, posterior cul-de-sac, broad ligaments, and uterosacral ligaments. Histopathologic findings include **hemosiderin deposits** and **endometrial glands or stroma** outside of the uterus. As the endometrial implants shed through the menstrual cycle, they can accumulate old blood which appears as "**chocolate**"-colored fluid inside an ovarian cyst (endometrioma). Implants throughout the pelvis and abdomen can also appear as flesh-colored nodules, powder burn patterns, or adhesive disease.

The **ovary** is covered by **simple cuboidal cells** that divide and proliferate rapidly to repair ovarian surface defects from ovulation. Ectopic endometrial tissue may impair fertility by disrupting folliculogenesis, oocyte release, and oocyte fertilization.

(Choices A, C, and F) Endometriosis involving the fallopian tubes is also common and can impair fertility by obstructing tubal transport. Implants on the cervix and vagina are rare.

(Choice E) The peritoneum has simple squamous epithelium (mesothelium) and is continuous with the cuboidal epithelium of the ovarian surface. These structures are frequent sites of endometriotic implants.

Educational objective:
The uterine mucosa is covered by endometrium, and abnormal implantation of endometrial glands/stroma is referred to as endometriosis. The ovary is covered by a simple cuboidal epithelium involved in surface repair of defects from ovulation. Endometriosis commonly affects the ovary and results in infertility.

References

- The developmental origin of cervical and vaginal epithelium and their clinical consequences: a systematic review.
- Human female reproductive tract epithelial cell culture.
- Endometriosis – Morphology, Clinical Presentations and Molecular Pathology

Pathology	Female Reproductive System & Breast	Endometriosis
Subject	System	Topic

Settings

1 2 3 4 5 6 7 8 9 10 11 12 13 14 15 16 17 18 19 20 21 22 23 24 25 26 27 28 29 30

Item 19 of 32
Question Id: 2056

Mark | Previous | Next | Full Screen | Tutorial | Lab Values | Notes | Calculator | Reverse Color | Text Zoom | Settings

The normal uterine mucosa (endometrium) is composed of simple columnar epithelium (**Choice B**), tubular glands, and stroma (connective

Exhibit Display

Pelvic endometriosis

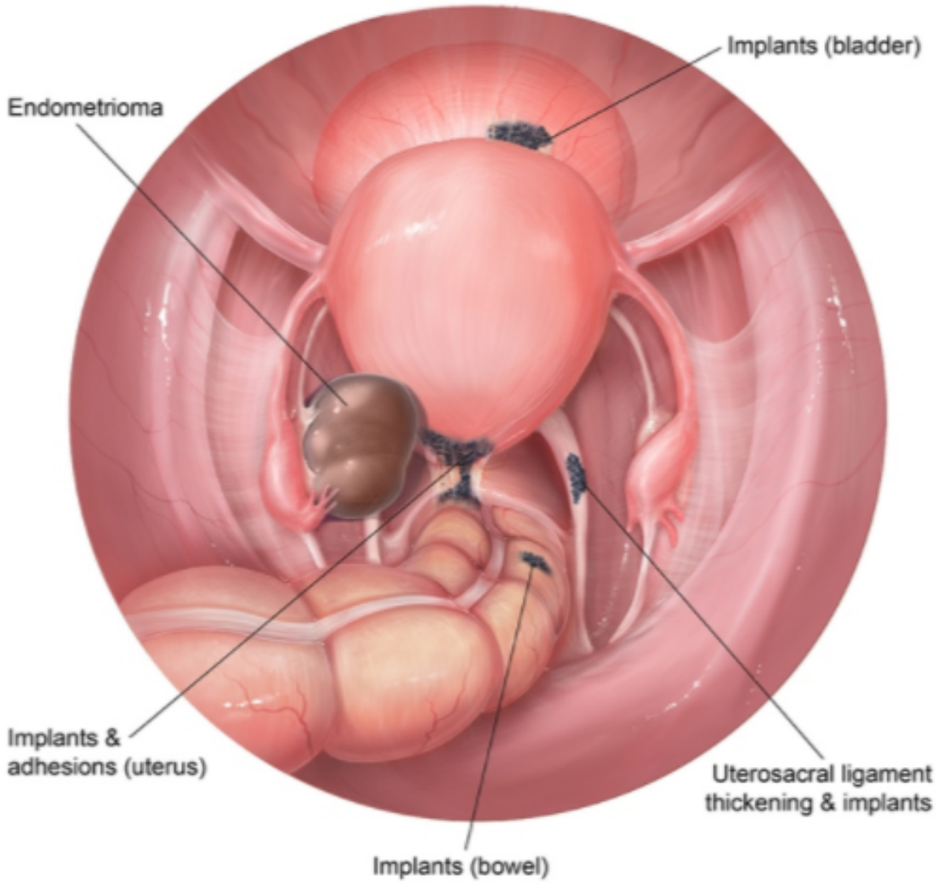

Zoom In | Zoom Out | Reset | Add To New Card | Existing Card

Block Time Remaining: 00:02:24
TUTOR

2 | Feedback | Suspend | End Block

A 34-year-old woman comes to the clinic due to a mass in her right breast. She discovered the mass after reading a magazine article recommending that women should perform breast self-examination regularly. The patient has no significant past medical history. A 2-cm nodule is noted on examination of the breast, and the patient is referred for biopsy. Histologic evaluation of the tissue specimen is shown in the image below.

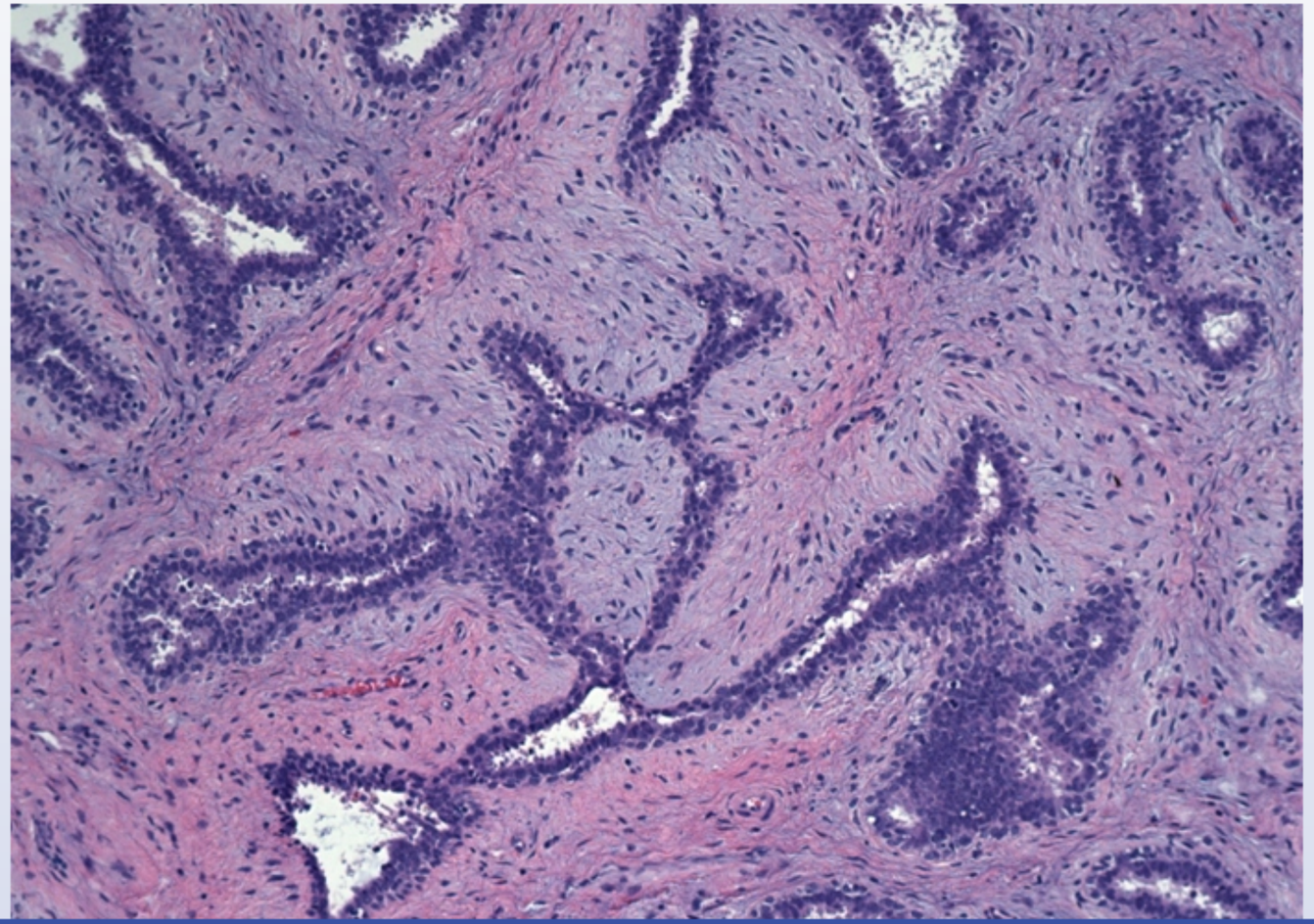

Settings

1 2 3 4 5 6 7 8 9 10 11 12 13 14 15 16 17 18 19 20 21 22 23 24 25 26 27 28 29 30

Item 20 of 32
Question Id: 1109

Mark | Previous | Next | Full Screen | Tutorial | Lab Values | Notes | Calculator | Reverse Color | Text Zoom | Settings

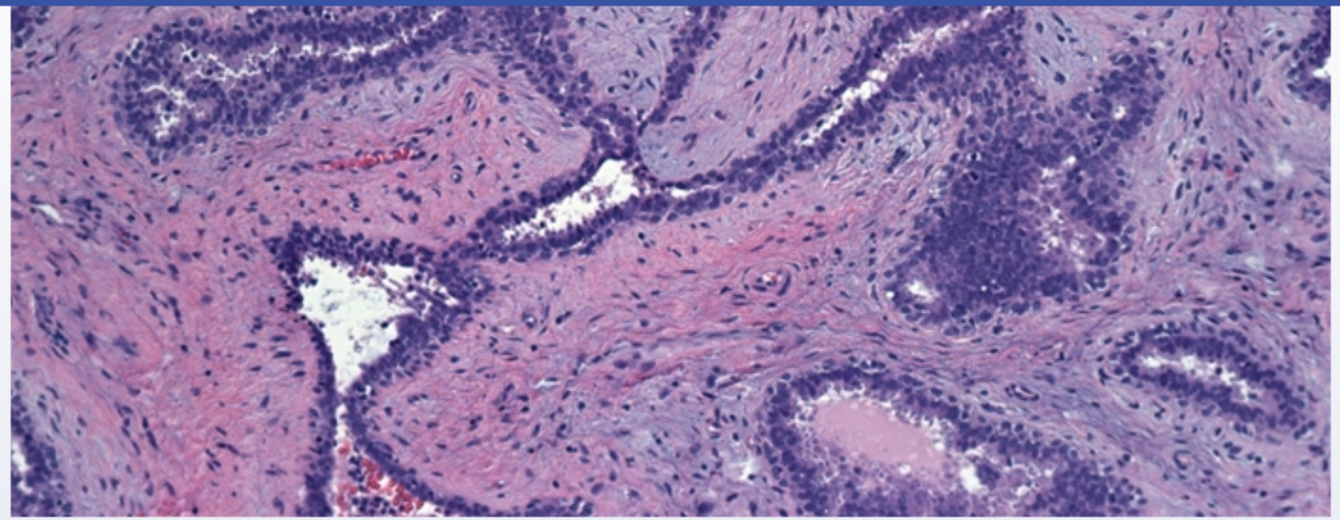

Which of the following is the most likely diagnosis?

- A. Ductal carcinoma in situ
- B. Fibroadenoma
- C. Mammary duct ectasia
- D. Medullary carcinoma
- E. Paget disease
- F. Sclerosing adenosis

Submit

Block Time Remaining: 00:02:27
TUTOR

7 | Feedback | Suspend | End Block

1 2 3 4 5 6 7 8 9 10 11 12 13 14 15 16 17 18 19 20 21 22 23 24 25 26 27 28 29 30

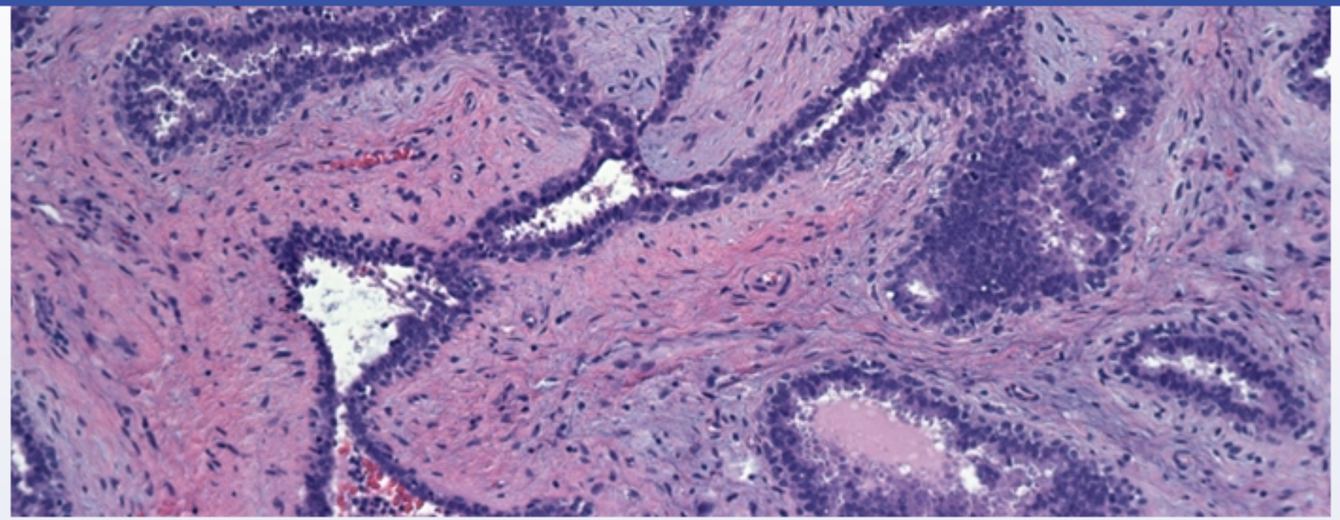

Which of the following is the most likely diagnosis?

- A. Ductal carcinoma in situ (14%)
- ✓ B. Fibroadenoma (67%)
- C. Mammary duct ectasia (3%)
- D. Medullary carcinoma (3%)
- E. Paget disease (1%)
- F. Sclerosing adenosis (9%)

Omitted
Correct answer

67%
Answered correctly

04 secs
Time Spent

02/08/2020
Last Updated

Settings

1
2
3
4
5
6
7
8
9
10
11
12
13
14
15
16
17
18
19
20
21
22
23
24
25
26
27
28
29
30

Item 20 of 32
Question Id: 1109

Mark | Previous | Next | Full Screen | Tutorial | Lab Values | Notes | Calculator | Reverse Color | Text Zoom | Settings

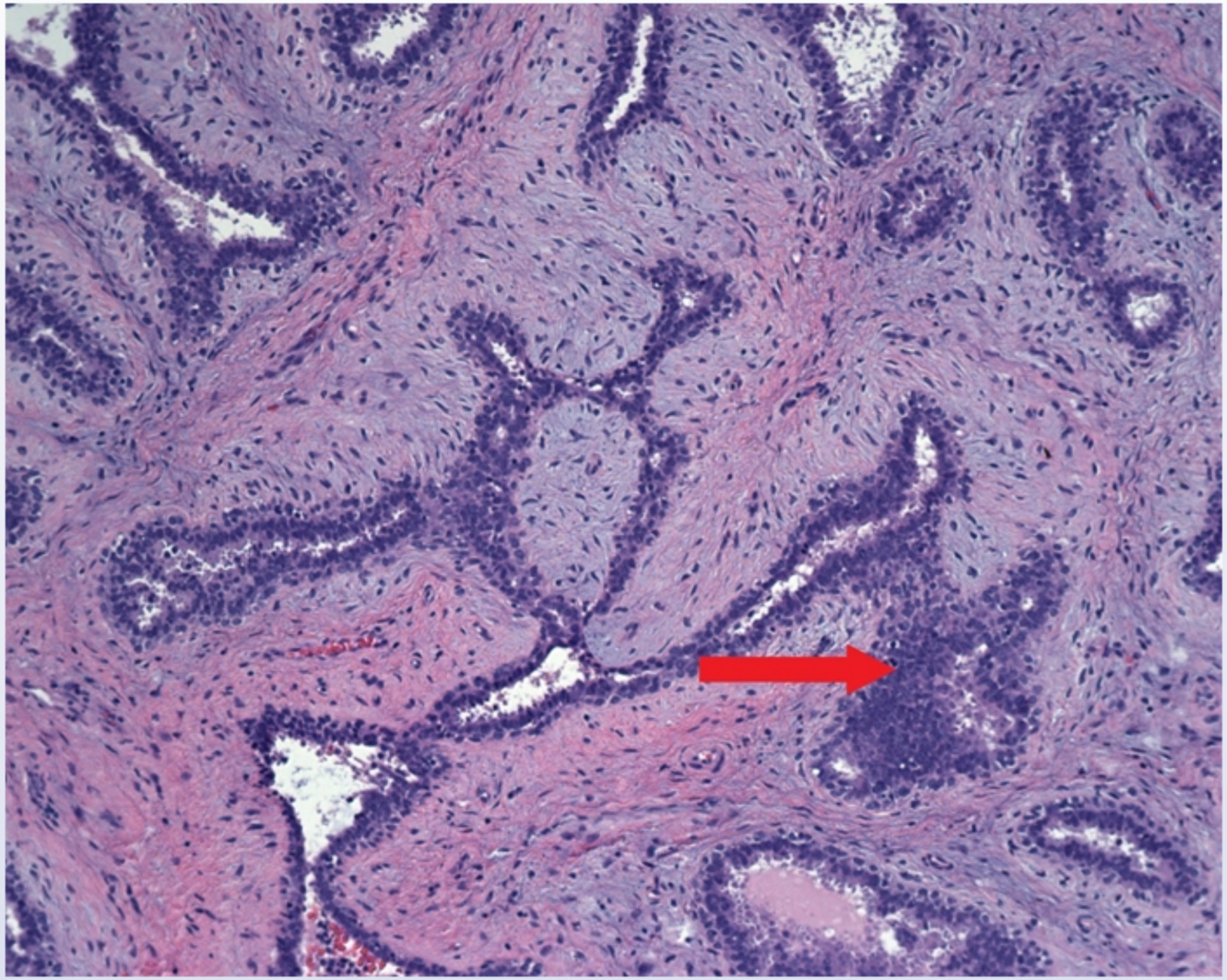

Fibroadenoma is the most common benign tumor of the breast, typically arising in young women age 15-35. Fibroadenomas are characterized by nodules that are well-demarcated, painless, mobile, and spherical and can be 1-10 cm in size. They can also occur as multiple and/or bilateral

Block Time Remaining: 00:02:28
TUTOR

7 | Feedback | Suspend | End Block

Fibroadenoma is the most common benign tumor of the breast, typically arising in young women age 15-35. Fibroadenomas are characterized by nodules that are well-demarcated, painless, mobile, and spherical and can be 1-10 cm in size. They can also occur as multiple and/or bilateral lesions. In younger women, fibroadenomas are usually discovered as a palpable mass by the patient or physician; in older patients, they are more often found incidentally on mammography. They often increase in size during pregnancy, lactation, or with estrogen therapy and usually regress after menopause.

Histologically, fibroadenomas are characterized by a benign-appearing cellular or **myxoid stroma** that encircles epithelium-lined glandular and cystic spaces (arrow). The lesions have a well-defined border but may compress and distort the surrounding glandular epithelium. As women age, the epithelium atrophies and the stroma becomes more hyalinized.

(Choice A) Ductal carcinoma in situ (DCIS) is a breast lesion characterized by a malignant clonal cell proliferation contained by the surrounding ductal basement membrane. The (basal) myoepithelial layer of the duct is preserved and uninvolved.

(Choice C) Mammary duct ectasia is characterized by ductal dilation, inspissated breast secretions, and chronic granulomatous inflammation in the periductal and interstitial areas.

(Choice D) Medullary carcinoma is characterized by solid sheets of vesicular, pleomorphic, mitotically active cells with a significant lymphoplasmacytic infiltrate around and within the tumor and a pushing, noninfiltrating border.

(Choice E) Paget disease of the nipple is a rare form of breast cancer in which malignant cells spread from superficial DCIS into nipple skin without crossing the basement membrane. Physical examination shows unilateral erythema and scale crust around the nipple.

(Choice F) Sclerosing adenosis is characterized by central acinar proliferation and compression with surrounding fibrotic tissue and peripheral ductal dilation. Sclerosing adenosis is a common finding in fibrocystic change.

Educational objective:
Fibroadenomas are the most common benign tumor of the breast. They are characterized histologically by a cellular or myxoid stroma that encircles and sometimes compresses epithelium-lined glandular and cystic spaces.

References

- Fibroepithelial tumors of the breast: pathologic and immunohistochemical features and molecular mechanisms.

Settings

1
2
3
4
5
6
7
8
9
10
11
12
13
14
15
16
17
18
19
20
21
22
23
24
25
26
27
28
29
30

Item 20 of 32
Question Id: 1109

Mark | Previous | Next | Full Screen | Tutorial | Lab Values | Notes | Calculator | Reverse Color | Text Zoom | Settings

Exhibit Display

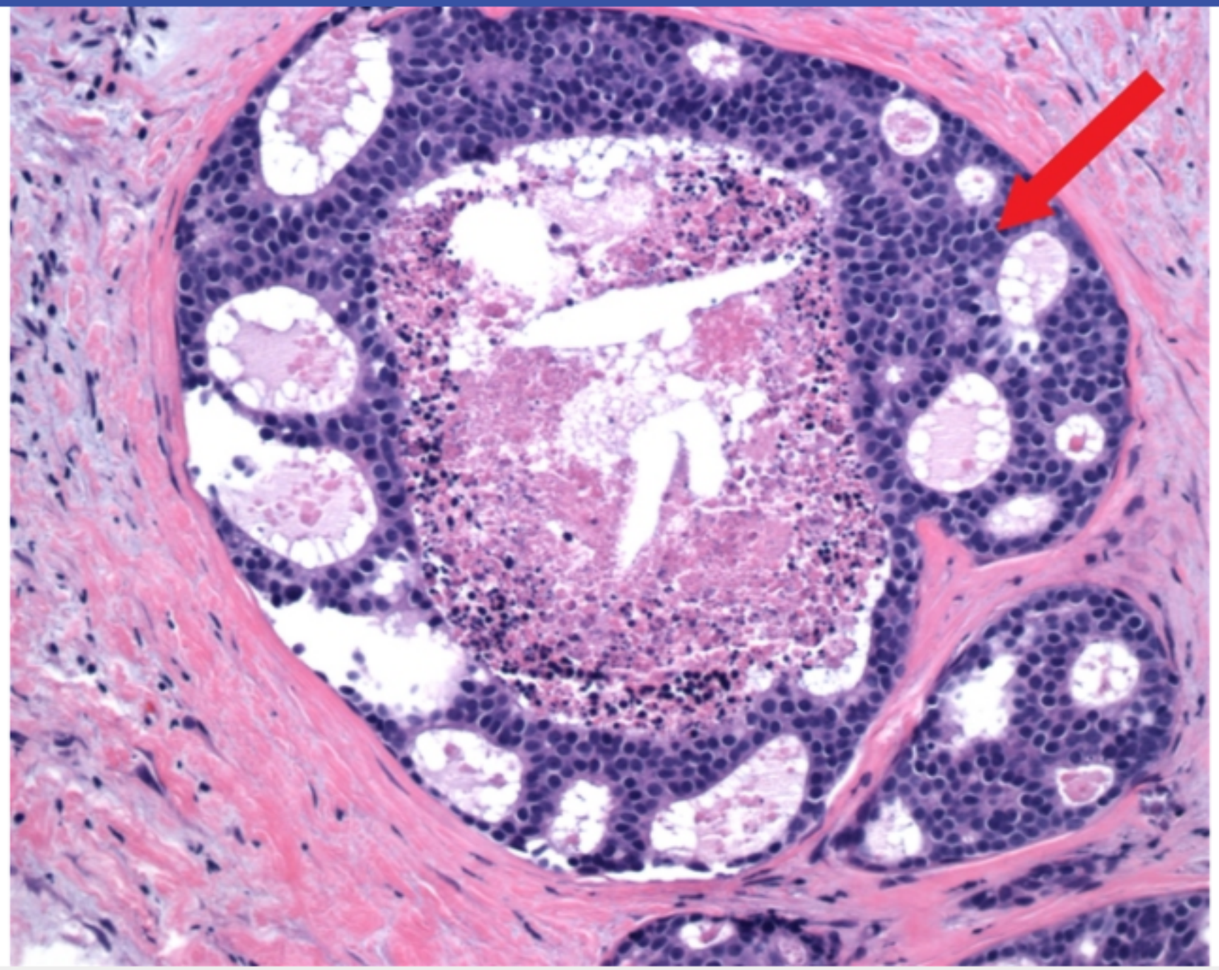

Zoom In | Zoom Out | Reset | Add To New Card | Existing Card

- Fibroepithelial tumors of the breast: pathologic and immunohistochemical features and molecular mechanisms.

Block Time Remaining: 00:02:28
TUTOR

7 | Feedback | Suspend | End Block

1 2 3 4 5 6 7 8 9 10 11 12 13 14 15 16 17 18 19 20 21 22 23 24 25 26 27 28 29 30

by nodules that are well-demarcated, painless, mobile, and spherical and can be 1-10 cm in size. They can also occur as multiple and/or bilateral

Exhibit Display

Medullary carcinoma of the breast Medullary carcinoma of the breast

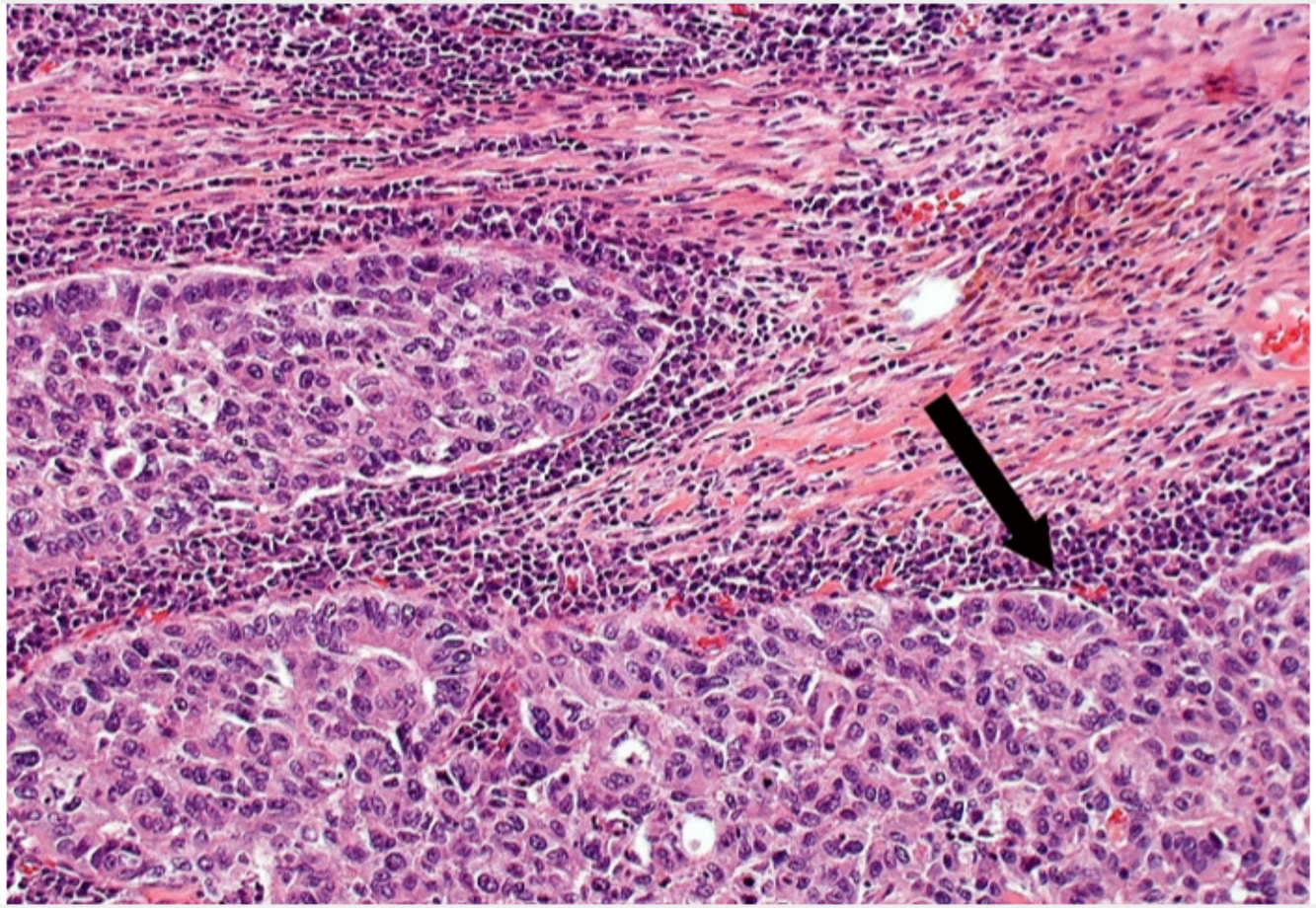

Zoom In | Zoom Out | Reset | Add To New Card | Existing Card

by nodules that are well-demarcated, painless, mobile, and spherical and can be 1-10 cm in size. They can also occur as multiple and/or bilateral

Exhibit Display

Medullary carcinoma of the breast Medullary carcinoma of the breast

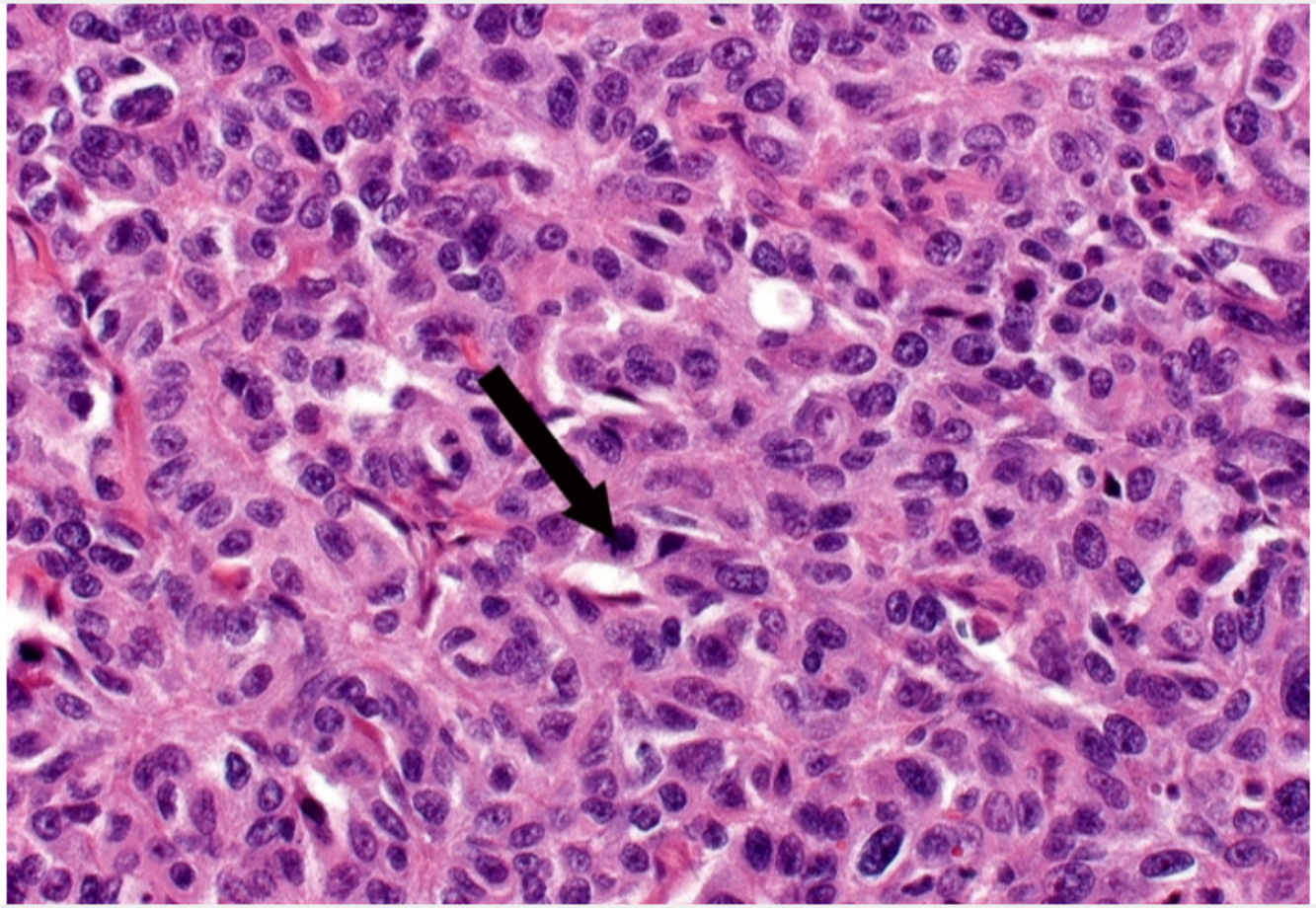

Zoom In | Zoom Out | Reset | Add To New Card | Existing Card

Settings

1 2 3 4 5 6 7 8 9 10 11 12 13 14 15 16 17 18 19 20 21 22 23 24 25 26 27 28 29 30

Item 20 of 32
Question Id: 1109

Mark | Previous | Next | Full Screen | Tutorial | Lab Values | Notes | Calculator | Reverse Color | Text Zoom | Settings

by nodules that are well-demarcated, painless, mobile, and spherical and can be 1-10 cm in size. They can also occur as multiple and/or bilateral

Exhibit Display

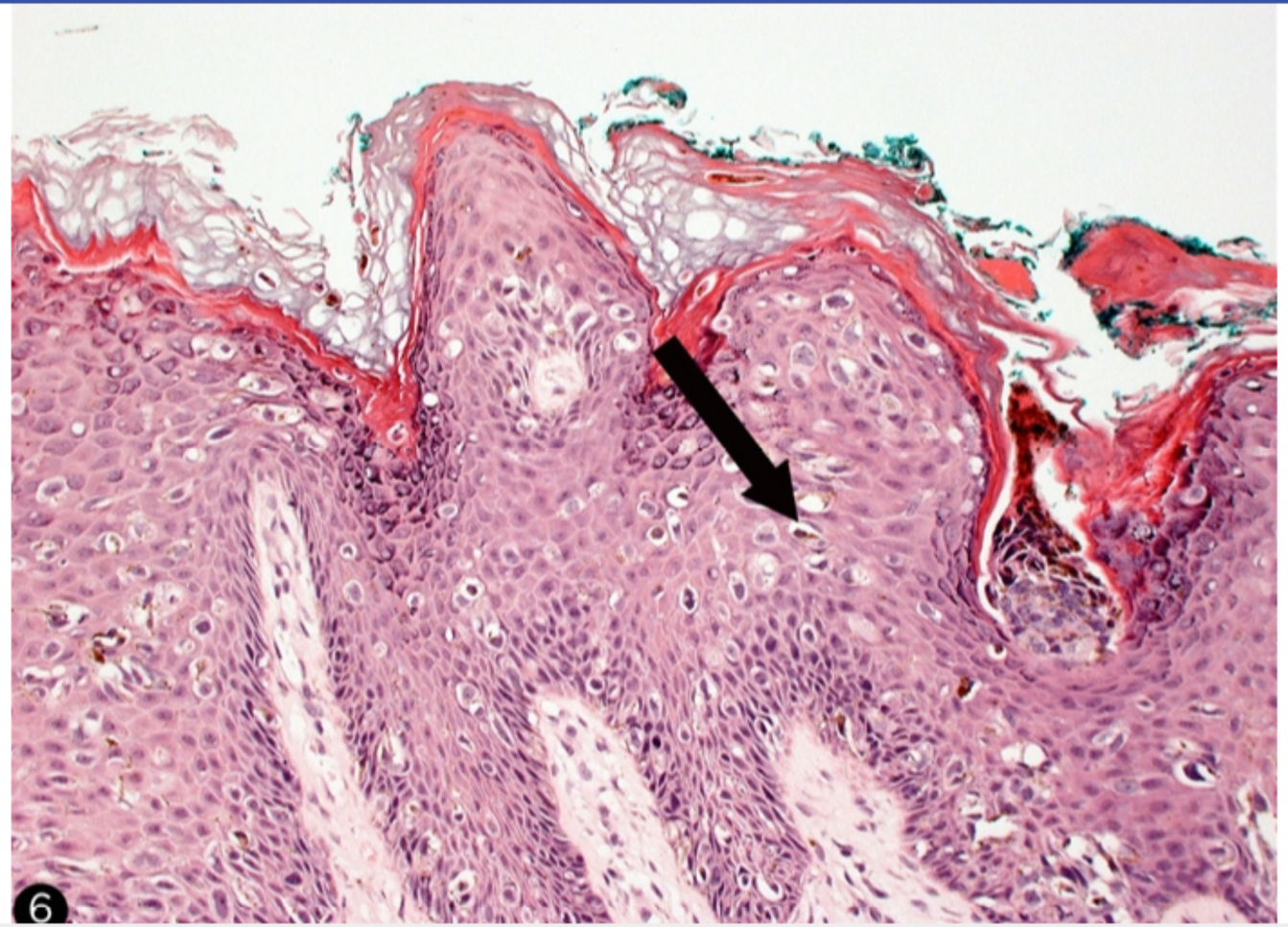

Zoom In | Zoom Out | Reset | Add To New Card | Existing Card

Block Time Remaining: 00:02:28
TUTOR

7 | Feedback | Suspend | End Block

Settings

1 2 3 4 5 6 7 8 9 10 11 12 13 14 15 16 17 18 19 20 21 22 23 24 25 26 27 28 29 30

Item 20 of 32
Question Id: 1109

Mark | Previous | Next | Full Screen | Tutorial | Lab Values | Notes | Calculator | Reverse Color | Text Zoom | Settings

by nodules that are well-demarcated, painless, mobile, and spherical and can be 1-10 cm in size. They can also occur as multiple and/or bilateral

Exhibit Display

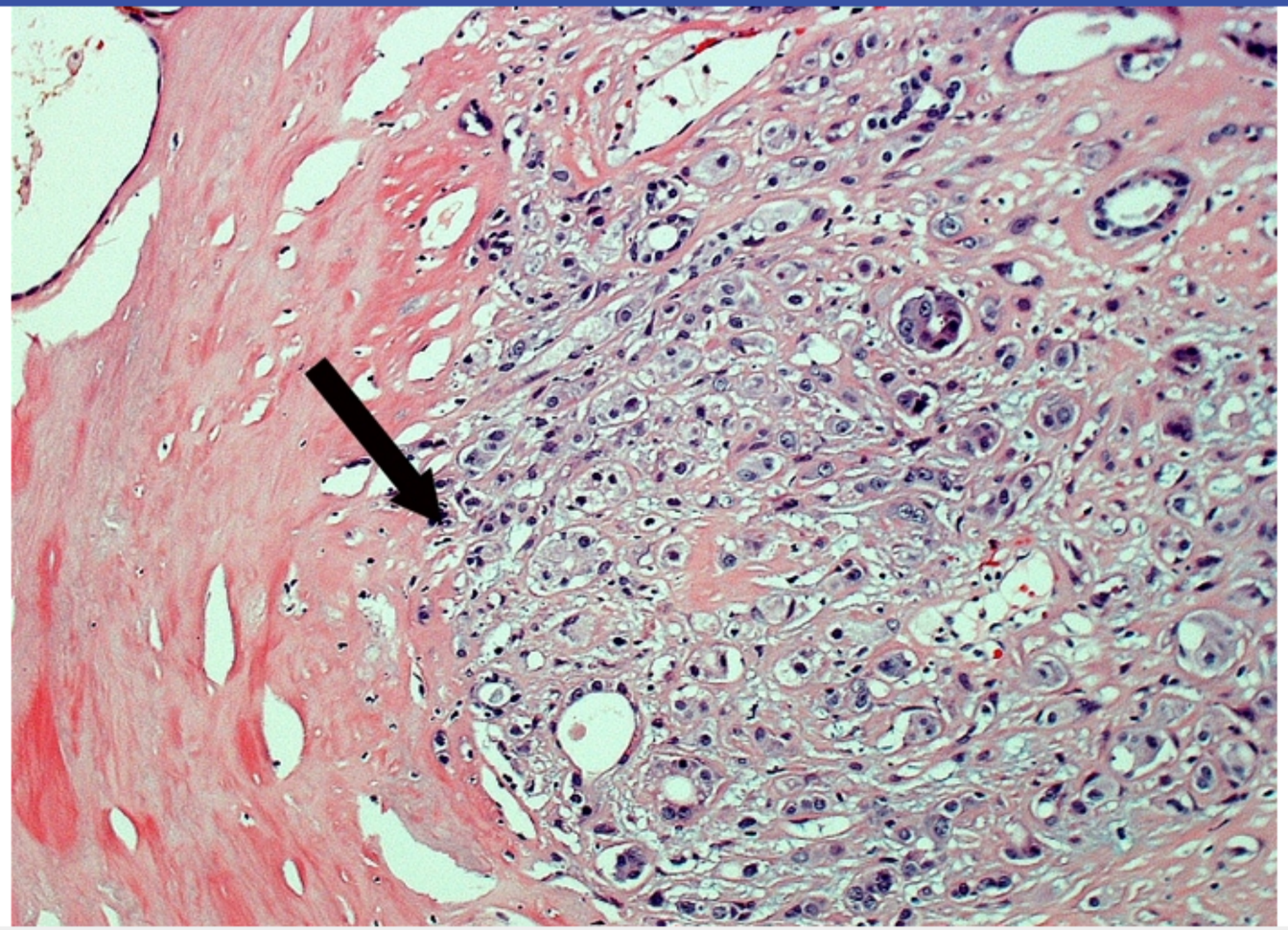

Zoom In | Zoom Out | Reset | Add To New Card | Existing Card

Block Time Remaining: 00:02:28
TUTOR

7 | Feedback | Suspend | End Block

A 36-year-old woman, gravida 2 para 1, at 37 weeks gestation comes to the hospital in labor, dilated to 10 cm. She received prenatal care at another medical center. The patient has had an uncomplicated pregnancy but had a cesarean delivery for her first pregnancy. Before her prenatal records can be obtained, she precipitously delivers a 4.15-kg (9.1-lb) infant over an intact perineum. The placenta is removed in pieces via manual extraction. After removal of the placenta, profuse vaginal bleeding occurs, and intravenous lines are placed in preparation for administration of fluids and medications. The bleeding continues despite uterine massage and administration of uterotonic medicines. Which of the following is the most likely cause of this patient's ongoing vaginal bleeding?

- A. Disseminated intravascular coagulation
- B. Placental abruption
- C. Placental accreta
- D. Uterine atony
- E. Uterine rupture

Submit

A 36-year-old woman, gravida 2 para 1, at 37 weeks gestation comes to the hospital in labor, dilated to 10 cm. She received prenatal care at another medical center. The patient has had an uncomplicated pregnancy but had a cesarean delivery for her first pregnancy. Before her prenatal records can be obtained, she precipitously delivers a 4.15-kg (9.1-lb) infant over an intact perineum. The placenta is removed in pieces via manual extraction. After removal of the placenta, profuse vaginal bleeding occurs, and intravenous lines are placed in preparation for administration of fluids and medications. The bleeding continues despite uterine massage and administration of uterotonic medicines. Which of the following is the most likely cause of this patient's ongoing vaginal bleeding?

- A. Disseminated intravascular coagulation (9%)
- B. Placental abruption (7%)
- ✓ C. Placental accreta (52%)
- D. Uterine atony (17%)
- E. Uterine rupture (12%)

Omitted
Correct answer
C

52%
Answered correctly

02 secs
Time Spent

03/11/2020
Last Updated

Explanation

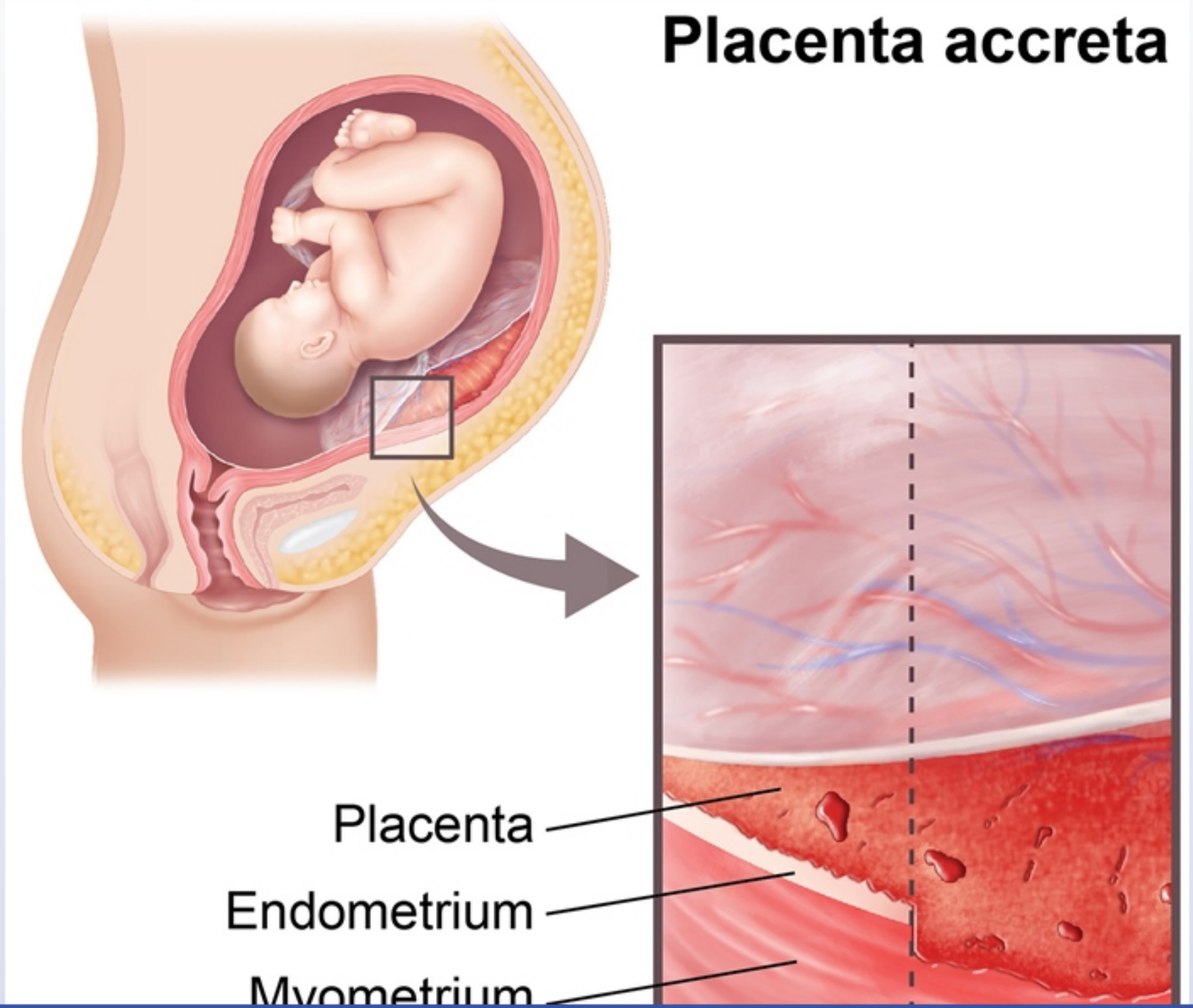
Placenta accreta
Placenta
Endometrium
Myometrium

After the placenta is delivered, hemostasis at the placental bed is usually achieved through clotting and compression of the placental site blood vessels by myometrial contraction. Disruption of either of these processes can lead to postpartum hemorrhage, a leading cause of maternal mortality.

The most common cause of postpartum hemorrhage is **uterine atony (Choice D)**, which is the failure of the uterus to contract adequately after delivery. Although atony might contribute to hemorrhage in this patient, the lack of response to uterotonic agents and the removal of the placenta in pieces suggest placenta accreta.

Placenta accreta refers to a placenta that is morbidly adherent to the myometrium. Scar tissue from prior surgery (eg, cesarean delivery) can result in a malformed or **absent decidual layer** between the placenta and the myometrium, allowing for direct **myometrial attachment** by the villous tissue and preventing normal placental separation after fetal delivery. Placental accreta is typically diagnosed during prenatal care and managed by cesarean delivery followed by hysterectomy. This patient's accreta was not recognized due to precipitous labor and unavailable records, resulting in hemorrhage with attempted placental extraction.

(Choice A) Excessive blood loss from obstetric complications can result in widespread activation of coagulation and fibrinolysis (disseminated intravascular coagulation). As systemic clotting factors are rapidly consumed and outpace their production, postpartum patients would experience petechiae, ecchymosis, and bleeding from intravenous lines in addition to severe vaginal bleeding.

(Choice B) Placental abruption is the premature detachment of the placenta from the uterine wall prior to the delivery of the fetus. Signs of placental abruption include painful prolonged uterine contractions, a tense abdomen, and vaginal bleeding prior to delivery. The manual extraction needed for this patient is not consistent with an abruption.

(Choice E) Uterine rupture is a full-thickness disruption of the uterine wall that typically presents with intense, acute abdominal pain, profuse vaginal bleeding, and fetal distress. Prior cesarean delivery is a risk factor. During a manual placental extraction, a uterine rupture can be palpated as an opening in the uterine wall, but it was not noted in this patient.

result in a malformed or **absent decidual layer** between the placenta and the myometrium, allowing for direct **myometrial attachment** by the villous tissue and preventing normal placental separation after fetal delivery. Placental accreta is typically diagnosed during prenatal care and managed by cesarean delivery followed by hysterectomy. This patient's accreta was not recognized due to precipitous labor and unavailable records, resulting in hemorrhage with attempted placental extraction.

(Choice A) Excessive blood loss from obstetric complications can result in widespread activation of coagulation and fibrinolysis (disseminated intravascular coagulation). As systemic clotting factors are rapidly consumed and outpace their production, postpartum patients would experience petechiae, ecchymosis, and bleeding from intravenous lines in addition to severe vaginal bleeding.

(Choice B) Placental abruption is the premature detachment of the placenta from the uterine wall prior to the delivery of the fetus. Signs of placental abruption include painful prolonged uterine contractions, a tense abdomen, and vaginal bleeding prior to delivery. The manual extraction needed for this patient is not consistent with an abruption.

(Choice E) Uterine rupture is a full-thickness disruption of the uterine wall that typically presents with intense, acute abdominal pain, profuse vaginal bleeding, and fetal distress. Prior cesarean delivery is a risk factor. During a manual placental extraction, a uterine rupture can be palpated as an opening in the uterine wall, but it was not noted in this patient.

Educational objective:
Postpartum hemorrhage is an obstetric emergency and can result from abnormal placentation. Prior uterine surgery can impair decidualization, resulting in myometrial invasion by villous tissue and a placenta that is abnormally adherent to the myometrium (placenta accreta).

References

- Prevention and management of postpartum hemorrhage: a comparison of 4 national guidelines.
- Morbidly adherent placenta.

Pathology	Pregnancy, Childbirth & Puerperium	Placental accreta
Subject	System	Topic

Copyright © UWorld. All rights reserved.

A 26-year-old woman, gravida 1, para 1, comes to the office for a routine examination. She noticed new facial hair over the past few months and thinks her voice is deeper. Her last menstrual period was 5 months ago. The patient's mother died from invasive lobular breast carcinoma at age 60. Physical examination is significant for coarse facial hair, and pelvic examination reveals clitoromegaly with a large adnexal mass. Urine pregnancy test is negative. Pelvic ultrasonography confirms a large ovarian cyst. Which of the following is the most likely diagnosis?

- A. Dysgerminoma
- B. Endodermal sinus tumor
- C. Granulosa cell tumor
- D. Mature cystic teratoma
- E. Serous cystadenocarcinoma
- F. Sertoli-Leydig tumor

Submit

A 26-year-old woman, gravida 1, para 1, comes to the office for a routine examination. She noticed new facial hair over the past few months and thinks her voice is deeper. Her last menstrual period was 5 months ago. The patient's mother died from invasive lobular breast carcinoma at age 60. Physical examination is significant for coarse facial hair, and pelvic examination reveals clitoromegaly with a large adnexal mass. Urine pregnancy test is negative. Pelvic ultrasonography confirms a large ovarian cyst. Which of the following is the most likely diagnosis?

- A. Dysgerminoma (6%)
- B. Endodermal sinus tumor (0%)
- C. Granulosa cell tumor (18%)
- D. Mature cystic teratoma (3%)
- E. Serous cystadenocarcinoma (6%)
- ✓ F. Sertoli-Leydig tumor (64%)

Omitted
Correct answer
F

64%
Answered correctly

02 secs
Time Spent

02/19/2020
Last Updated

Explanation

Malignant ovarian neoplasms		
Histologic type	Diagnosis	Key features

Malignant ovarian neoplasms		
Histologic type	**Diagnosis**	**Key features**
Epithelial	**Serous cystadenocarcinoma**	• Most common ovarian cancer • Often bilateral • Histology: Psammoma bodies
	Mucinous cystadenocarcinoma	• Pseudomyxoma peritonei • Mucin-producing epithelial cells
Germ cell	**Dysgerminoma**	• Adolescents • ↑ β-hCG, ↑ LDH • Histology: "Fried egg cells"
	Endodermal sinus (yolk sac)	• ↑ AFP • Aggressive • Schiller-Duval bodies resemble glomeruli
Stroma (sex cord)	**Granulosa cell**	• ↑ Estrogen (eg, endometrial hyperplasia, postmenopausal bleeding) • ↑ Inhibin • Histology: Call-Exner bodies, coffee bean nuclei
	Sertoli-Leydig	• ↑ Androgens (eg, hirsutism, clitoromegaly)

AFP = alpha-fetoprotein; **LDH** = lactate dehydrogenase.

A **Sertoli-Leydig cell ovarian tumor** typically presents as a large adnexal mass with amenorrhea and **virilization** (eg, hirsutism, clitoromegaly, deeper voice). Virilization occurs due to increased testosterone secretion by this rare **sex cord-stromal** tumor. Patients with this neoplasm are usually young women, and it is histopathologically similar to Sertoli cell testicular neoplasms. Microscopic examination of these tumors shows hollow or solid tubules lined by round Sertoli cells and surrounded by a fibrous stroma.

A **Sertoli-Leydig cell ovarian tumor** typically presents as a large adnexal mass with amenorrhea and **virilization** (eg, hirsutism, clitoromegaly, deeper voice). Virilization occurs due to increased testosterone secretion by this rare **sex cord-stromal** tumor. Patients with this neoplasm are usually young women, and it is histopathologically similar to Sertoli cell testicular neoplasms. Microscopic examination of these tumors shows hollow or solid tubules lined by round Sertoli cells and surrounded by a fibrous stroma.

(Choice A) A dysgerminoma is a malignant germ cell ovarian tumor that does not secrete testosterone and typically presents as a rapidly growing mass or a ruptured ovarian cyst. It is a common cause of ovarian cancer in pregnancy. Histology shows vesicular cells with clear cytoplasm and large central nuclei due to an increased nucleus to cytoplasm ratio (eg, "fried egg cells").

(Choice B) An endodermal sinus (eg, yolk sac) tumor is a malignant germ cell ovarian tumor that typically presents with abdominal pain due to ovarian torsion without virilization. The neoplasm is characterized by Schiller-Duval bodies, which are glomerulus-like papillary structures with a central vessel (black arrow).

(Choice C) A granulosa cell tumor is a rare sex cord-stromal tumor that produces excessive estrogen (eg, abnormal uterine bleeding due to endometrial hyperplasia, precocious puberty). These tumors are characterized by Call-Exner bodies, small follicle-like structures filled with eosinophilic secretions that are lined by granulosa cells containing coffee bean nuclei (black arrows).

(Choice D) A mature cystic teratoma, the most common benign germ cell tumor, is usually identified as a nonfunctional adnexal mass in an asymptomatic patient. Pathologic findings include keratinized epithelial tissue with sebaceous glands.

(Choice E) Serous cystadenocarcinoma is the most common epithelial ovarian cancer that classically presents in a post-menopausal patient who has an adnexal mass and ascites without excess hormonal activity. Psammoma bodies are concentrically laminated, calcified spheric deposits found on biopsy.

Educational objective:
Sertoli-Leydig cell tumors of the ovary arise from the sex cord stroma and secrete testosterone. Typical features include a large ovarian mass and signs of virilization. Tubular structures lined by round Sertoli cells and surrounded by a fibrous stroma are seen on pathology.

References

- Granulosa cell tumor of the ovary: tumor review.

Settings

1 2 3 4 5 6 7 8 9 10 11 12 13 14 15 16 17 18 19 20 21 22 23 24 25 26 27 28 29 30

Item 22 of 32
Question Id: 1928

Mark | Previous | Next | Full Screen | Tutorial | Lab Values | Notes | Calculator | Reverse Color | Text Zoom | Settings

Exhibit Display

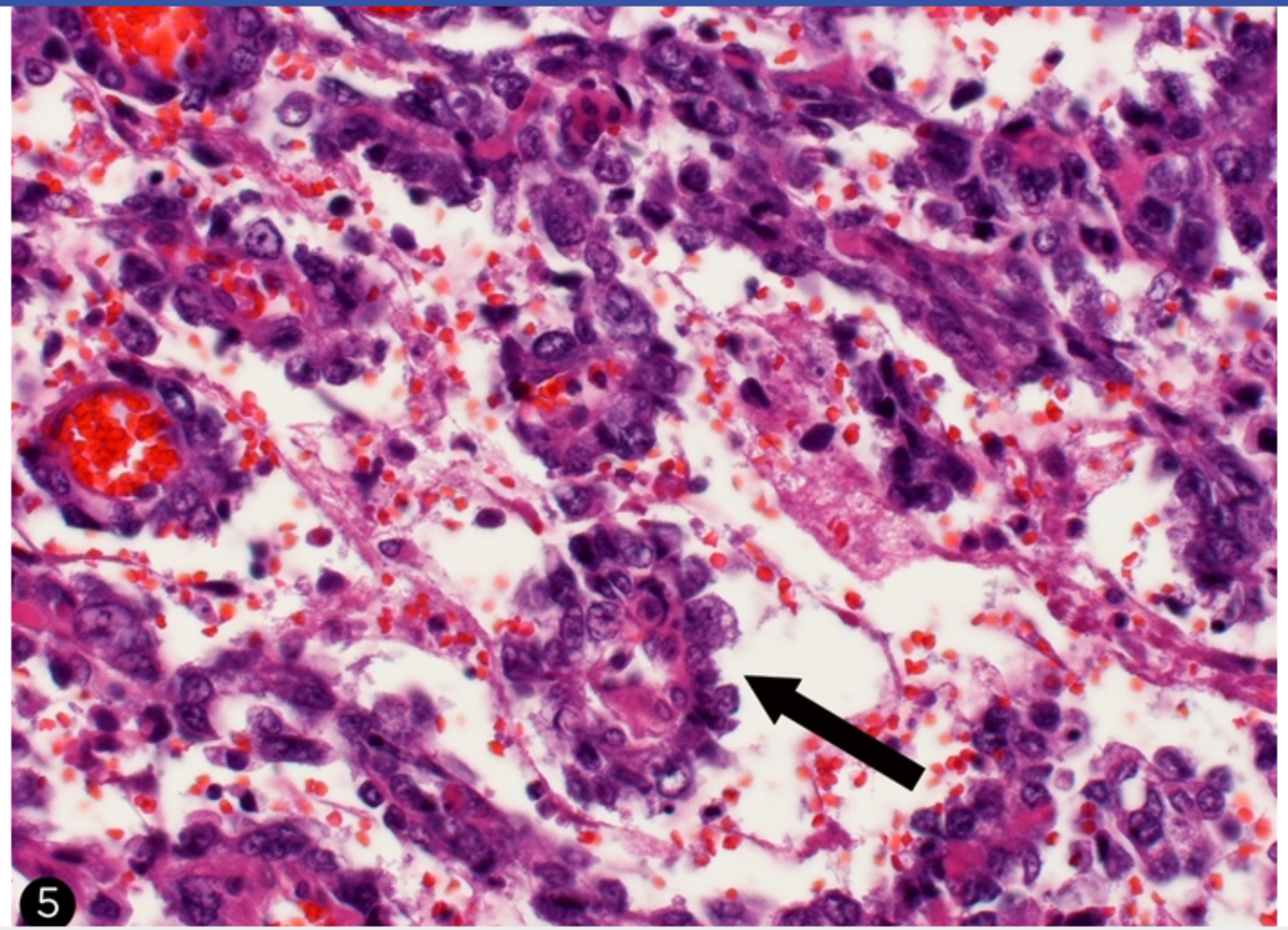

Zoom In | Zoom Out | Reset | Add To New Card | Existing Card

- Granulosa cell tumor of the ovary: tumor review.

Block Time Remaining: 00:02:32
TUTOR

6 | Feedback | Suspend | End Block

Exhibit Display

Zoom In | Zoom Out | Reset | Add To New Card | Existing Card

- Granulosa cell tumor of the ovary: tumor review.

Exhibit Display

Zoom In | Zoom Out | Reset | Add To New Card | Existing Card

- Granulosa cell tumor of the ovary: tumor review.

mass of a ruptured ovarian cyst. It is a common cause of ovarian cancer in pregnancy. Histology shows vesicular cells with clear cytoplasm and large central nuclei due to an increased nucleus to cytoplasm ratio (eg, "fried egg cells").

(Choice B) An endodermal sinus (eg, yolk sac) tumor is a malignant germ cell ovarian tumor that typically presents with abdominal pain due to ovarian torsion without virilization. The neoplasm is characterized by Schiller-Duval bodies, which are glomerulus-like papillary structures with a central vessel (black arrow).

(Choice C) A granulosa cell tumor is a rare sex cord-stromal tumor that produces excessive estrogen (eg, abnormal uterine bleeding due to endometrial hyperplasia, precocious puberty). These tumors are characterized by Call-Exner bodies, small follicle-like structures filled with eosinophilic secretions that are lined by granulosa cells containing coffee bean nuclei (black arrows).

(Choice D) A mature cystic teratoma, the most common benign germ cell tumor, is usually identified as a nonfunctional adnexal mass in an asymptomatic patient. Pathologic findings include keratinized epithelial tissue with sebaceous glands.

(Choice E) Serous cystadenocarcinoma is the most common epithelial ovarian cancer that classically presents in a post-menopausal patient who has an adnexal mass and ascites without excess hormonal activity. Psammoma bodies are concentrically laminated, calcified spheric deposits found on biopsy.

Educational objective:
Sertoli-Leydig cell tumors of the ovary arise from the sex cord stroma and secrete testosterone. Typical features include a large ovarian mass and signs of virilization. Tubular structures lined by round Sertoli cells and surrounded by a fibrous stroma are seen on pathology.

References

- Granulosa cell tumor of the ovary: tumor review.
- Sertoli-Leydig cell tumor with heterologous element: a case report and a review of the literature.

Pathology	Female Reproductive System & Breast	Ovarian cancer
Subject	System	Topic

Copyright © UWorld. All rights reserved.

A 54-year-old man comes to the office due to difficulty maintaining an erection for the last several weeks. He says, "One night I was having sex with my wife and could not maintain an erection. Since then, it has continued to be a problem." The patient still has morning erections. His medical history is significant for hypertension, coronary artery disease, and depression. He has been married for 20 years but reports that he and his wife have been arguing since he began spending more time at work following a promotion 2 months ago. His current medications include amlodipine, lisinopril, and bupropion. Physical examination is unremarkable. Which of the following is the most likely cause of this patient's erectile dysfunction?

- A. Advancing age
- B. Antidepressant-induced sexual dysfunction
- C. Antihypertensive-induced adverse effect
- D. Psychological distress
- E. Vascular insufficiency

Submit

1 2 3 4 5 6 7 8 9 10 11 12 13 14 15 16 17 18 19 20 21 22 23 24 25 26 27 28 29 30

A 54-year-old man comes to the office due to difficulty maintaining an erection for the last several weeks. He says, "One night I was having sex with my wife and could not maintain an erection. Since then, it has continued to be a problem." The patient still has morning erections. His medical history is significant for hypertension, coronary artery disease, and depression. He has been married for 20 years but reports that he and his wife have been arguing since he began spending more time at work following a promotion 2 months ago. His current medications include amlodipine, lisinopril, and bupropion. Physical examination is unremarkable. Which of the following is the most likely cause of this patient's erectile dysfunction?

- A. Advancing age (1%)
- B. Antidepressant-induced sexual dysfunction (5%)
- C. Antihypertensive-induced adverse effect (3%)
- ✓ D. Psychological distress (86%)
- E. Vascular insufficiency (2%)

Omitted
Correct answer
D

86%
Answered correctly

02 secs
Time Spent

03/10/2020
Last Updated

Explanation

The temporal association between this patient's arguments with his wife and subsequent onset of **erectile dysfunction** (ED) makes **psychogenic** factors the most likely cause of his ED. The presence of **spontaneous nocturnal erections** is another important diagnostic clue as this demonstrates the integrity of neurologic reflexes and corpus cavernosa blood flow. Loss of normal nocturnal erections occurs in men with organic ED but is not seen with psychogenic etiologies.

The temporal association between this patient's arguments with his wife and subsequent onset of **erectile dysfunction** (ED) makes **psychogenic** factors the most likely cause of his ED. The presence of **spontaneous nocturnal erections** is another important diagnostic clue as this demonstrates the integrity of neurologic reflexes and corpus cavernosa blood flow. Loss of normal nocturnal erections occurs in men with organic ED but is not seen with psychogenic etiologies.

ED can be caused by organic factors, psychogenic factors, or a combination of both. Psychogenic causes include performance anxiety, depression, sexual trauma, and/or relationship problems and are typically associated with an **abrupt onset** triggered by stress, as in this patient. In contrast, men suffering from organic causes of ED (eg, vascular insufficiency) tend to have a slower progression of symptoms, with intermittent ED later becoming more persistent in nature **(Choice E)**.

(Choice A) There tends to be an increase in the incidence of ED with advancing age. However, the sudden onset of this patient's dysfunction during a time of relationship and work stress makes a psychogenic cause more likely.

(Choices B and C) Antidepressants, particularly selective serotonin reuptake inhibitors, have been associated with sexual dysfunction. However, the norepinephrine-dopamine reuptake inhibitor bupropion has not been associated with sexual dysfunction. Of the antihypertensive agents, thiazide diuretics and sympathetic blockers (eg, clonidine, methyldopa) have the greatest risk for ED. Angiotension-converting enzyme inhibitors (eg, lisinopril) and calcium channel blockers (eg, amlodipine) have the least risk.

Educational objective:
Psychogenic causes of erectile dysfunction include performance anxiety, depression, sexual trauma, relationship problems, and stress. Important clues include sudden-onset and normal nocturnal erections.

References

- The 2018 revision to the process of care model for evaluation of erectile dysfunction.

Pathology	Male Reproductive System	Male sexual dysfunction
Subject	System	Topic

Copyright © UWorld. All rights reserved.

A 29-year-old woman with a history of type 1 diabetes mellitus goes into labor during her 38th week of gestation. She received regular prenatal care, but her blood glucose levels were poorly controlled throughout the pregnancy. During the second stage of labor, fetal descent fails to progress and the infant is delivered by caesarean section. Apgar scores were 8 and 9 at 1 and 5 minutes, respectively. Physical examination shows an infant large for gestational age but is otherwise normal. Which of the following metabolic disturbances is most likely to develop in the neonate?

- A. Diabetic ketoacidosis
- B. Hyperthyroidism
- C. Persistent hypoglycemia
- D. Transient hyperglycemia
- E. Transient hypoglycemia

Submit

A 29-year-old woman with a history of type 1 diabetes mellitus goes into labor during her 38th week of gestation. She received regular prenatal care, but her blood glucose levels were poorly controlled throughout the pregnancy. During the second stage of labor, fetal descent fails to progress and the infant is delivered by caesarean section. Apgar scores were 8 and 9 at 1 and 5 minutes, respectively. Physical examination shows an infant large for gestational age but is otherwise normal. Which of the following metabolic disturbances is most likely to develop in the neonate?

- A. Diabetic ketoacidosis (1%)
- B. Hyperthyroidism (0%)
- C. Persistent hypoglycemia (8%)
- D. Transient hyperglycemia (12%)
- ✓ E. Transient hypoglycemia (76%)

Omitted
Correct answer
E

76%
Answered correctly

01 sec
Time Spent

03/10/2020
Last Updated

Explanation

Neonatal complications of diabetes during pregnancy

Neonatal complications of diabetes during pregnancy

- Premature delivery
- Fetal macrosomia
- Congenital malformations
  - Neural tube defects
  - Cardiovascular anomalies
  - Caudal regression syndrome
- Respiratory distress
- Transient hypoglycemia
- Polycythemia & hyperviscosity

©UWorld

Diabetes during pregnancy is associated with a number of neonatal complications, including **transient hypoglycemia**. In pregnant women with poorly controlled diabetes mellitus, the fetus is subjected to high blood glucose levels since glucose freely crosses the placenta; however, maternal insulin is not able to cross the placenta. The resulting fetal hyperglycemia leads to a compensatory rise in fetal insulin production and islet cell hyperplasia. Fetal hyperinsulinemia promotes abnormal fetal growth, resulting in **macrosomia**. After birth, the neonate is no longer exposed to the mother's high blood glucose levels, but a hyperinsulinemic state persists for several days, predisposing the neonate to developing hypoglycemia.

(Choices A and D) Diabetic ketoacidosis and hyperglycemia do not occur in the newborn of a diabetic mother even if diabetes is poorly controlled during pregnancy, as the fetus is able to synthesize appropriate amounts of insulin.

(Choice B) Graves' disease during pregnancy can be complicated by neonatal hyperthyroidism caused by placental transfer of maternal thyroid-stimulating antibodies.

(Choice C) Hypoglycemia in the neonate of a diabetic mother typically resolves within 3-7 days of birth as the hyperinsulinemia remits. Persistent hypoglycemia should prompt investigation for inborn metabolic abnormalities or genetic defects affecting insulin secretion (eg, persistent

©UWorld

Diabetes during pregnancy is associated with a number of neonatal complications, including **transient hypoglycemia**. In pregnant women with poorly controlled diabetes mellitus, the fetus is subjected to high blood glucose levels since glucose freely crosses the placenta; however, maternal insulin is not able to cross the placenta. The resulting fetal hyperglycemia leads to a compensatory rise in fetal insulin production and islet cell hyperplasia. Fetal hyperinsulinemia promotes abnormal fetal growth, resulting in **macrosomia**. After birth, the neonate is no longer exposed to the mother's high blood glucose levels, but a hyperinsulinemic state persists for several days, predisposing the neonate to developing hypoglycemia.

(Choices A and D) Diabetic ketoacidosis and hyperglycemia do not occur in the newborn of a diabetic mother even if diabetes is poorly controlled during pregnancy, as the fetus is able to synthesize appropriate amounts of insulin.

(Choice B) Graves' disease during pregnancy can be complicated by neonatal hyperthyroidism caused by placental transfer of maternal thyroid-stimulating antibodies.

(Choice C) Hypoglycemia in the neonate of a diabetic mother typically resolves within 3-7 days of birth as the hyperinsulinemia remits. Persistent hypoglycemia should prompt investigation for inborn metabolic abnormalities or genetic defects affecting insulin secretion (eg, persistent hyperinsulinemic hypoglycemia of infancy).

Educational objective:
Neonates born to mothers with poorly controlled diabetes during pregnancy are exposed to high maternal glucose levels in utero, resulting in excessive fetal insulin production and islet hyperplasia. Fetal hyperinsulinemia persists for several days following birth and predisposes the infant to transient hypoglycemia.

References

- Hypoglycemia rates in the first days of life among term infants born to diabetic mothers.

Pathology	Pregnancy, Childbirth & Puerperium	Diabetes mellitus
Subject	System	Topic

A 49-year-old woman, gravida 2, para 2, comes to the office due to 10 months of irregular vaginal bleeding. Her last menstrual period was 3 years ago. She has a history of hypothyroidism and takes levothyroxine daily. Ultrasound reveals a thickened endometrium and a solid left adnexal mass. Endometrial biopsy is abnormal, and the patient requires surgery. Intraoperatively, the ovarian mass is yellow and firm. Pathology reports small cuboidal cells in sheets with gland-like structures containing acidophilic material. The cells are arranged in a microfollicular pattern around a pink, eosinophilic center. Which of the following is most likely secreted by this patient's tumor?

- A. α-fetoprotein
- B. β-hCG
- C. CA-125
- D. Estrogen
- E. Testosterone
- F. Thyroxine

Submit

A 49-year-old woman, gravida 2, para 2, comes to the office due to 10 months of irregular vaginal bleeding. Her last menstrual period was 3 years ago. She has a history of hypothyroidism and takes levothyroxine daily. Ultrasound reveals a thickened endometrium and a solid left adnexal mass. Endometrial biopsy is abnormal, and the patient requires surgery. Intraoperatively, the ovarian mass is yellow and firm. Pathology reports small cuboidal cells in sheets with gland-like structures containing acidophilic material. The cells are arranged in a microfollicular pattern around a pink, eosinophilic center. Which of the following is most likely secreted by this patient's tumor?

- A. α-fetoprotein (15%)
- B. β-hCG (9%)
- C. CA-125 (23%)
- ✓ D. Estrogen (38%)
- E. Testosterone (1%)
- F. Thyroxine (11%)

Omitted
Correct answer
D

38%
Answered correctly

01 sec
Time Spent

02/05/2020
Last Updated

Explanation

Granulosa cell tumor of the ovary

Granulosa cell tumor of the ovary	
Clinical features	• Large, unilateral adnexal mass • ↑Estrogen (endometrial hyperplasia, precocious puberty) • ↑Inhibin
Histology	• Call-Exner bodies (cuboidal granulosa cells in a rosette pattern with coffee bean nuclei) • Yellow theca cells with lipid

©UWorld

Granulosa cell tumors comprise approximately 5% of all ovarian tumors and are primarily identified in **postmenopausal** women. These tumors are derived from the ovarian stroma and are classified as **sex cord-stromal tumors**, which contain a predominance of granulosa cells and a scattering of theca cells. The granulosa cells are small and cuboidal in shape, grow in cords or sheets, and form follicle- or rosette-like structures (**Call-Exner bodies**) that have a gland-like appearance with a pink eosinophilic center and coffee bean nuclei (black arrows). Theca cells are plump with lipid contents, which give the mass a yellow color on gross inspection.

Typically, granulosa-theca cell tumors are **unilateral** and large. Unlike epithelial ovarian cancers, these masses **secrete estrogen** and can present with **endometrial hyperplasia** (eg, postmenopausal bleeding with thickened endometrium on ultrasound). The unopposed estrogen leads to hyperplasia of the endometrial cells and glands, and the increased cellular division of the hyperplastic cells in turn increases the risk of cellular atypia and endometrial carcinoma. In young patients, excessive estrogen levels may cause precocious sexual development.

(Choice A) α-fetoprotein (AFP) is normally produced by the fetal liver and yolk sac, but it can also be used as a tumor marker in patients with hepatocellular, nonseminomatous testicular, or ovarian carcinomas.

(Choice B) β-hCG is used to confirm pregnancy and screen for gestational trophoblastic disease and germ cell tumors.

©UWorld

Granulosa cell tumors comprise approximately 5% of all ovarian tumors and are primarily identified in **postmenopausal** women. These tumors are derived from the ovarian stroma and are classified as **sex cord-stromal tumors**, which contain a predominance of granulosa cells and a scattering of theca cells. The granulosa cells are small and cuboidal in shape, grow in cords or sheets, and form follicle- or rosette-like structures (**Call-Exner bodies**) that have a gland-like appearance with a pink eosinophilic center and coffee bean nuclei (black arrows). Theca cells are plump with lipid contents, which give the mass a yellow color on gross inspection.

Typically, granulosa-theca cell tumors are **unilateral** and large. Unlike epithelial ovarian cancers, these masses **secrete estrogen** and can present with **endometrial hyperplasia** (eg, postmenopausal bleeding with thickened endometrium on ultrasound). The unopposed estrogen leads to hyperplasia of the endometrial cells and glands, and the increased cellular division of the hyperplastic cells in turn increases the risk of cellular atypia and endometrial carcinoma. In young patients, excessive estrogen levels may cause precocious sexual development.

(Choice A) α-fetoprotein (AFP) is normally produced by the fetal liver and yolk sac, but it can also be used as a tumor marker in patients with hepatocellular, nonseminomatous testicular, or ovarian carcinomas.

(Choice B) β-hCG is used to confirm pregnancy and screen for gestational trophoblastic disease and germ cell tumors.

(Choice C) Cancer antigen 125 (CA-125) is elevated in epithelial carcinomas of the ovary (eg, serous, endometrioid, clear cell). Stromal tumors do not release significant amounts of CA-125.

(Choice E) Testosterone is produced by Sertoli-Leydig tumors, another type of ovarian sex cord tumor. Affected patients present with evidence of hyperandrogenism (eg, hirsutism, clitoromegaly, deepening voice).

(Choice F) Struma ovarii is a germ cell tumor of the ovary that can cause hyperthyroidism by secreting thyroxine. Histopathology of this tumor reveals mature thyroid tissue.

Educational objective:
Granulosa cell tumors are sex-cord stromal tumors of the ovary that secrete estrogen and can cause endometrial hyperplasia. Call-Exner bodies (cells arranged in a microfollicular or rosette pattern) are seen on microscopy. On gross pathology, the tumor appears yellow due to the lipid content in theca cells.

Settings

1 2 3 4 5 6 7 8 9 10 11 12 13 14 15 16 17 18 19 20 21 22 23 24 25 26 27 28 29 30

Item 25 of 32
Question Id: 1158

Mark | Previous | Next | Full Screen | Tutorial | Lab Values | Notes | Calculator | Reverse Color | Text Zoom | Settings

Exhibit Display

Zoom In | Zoom Out | Reset | Add To New Card | Existing Card

Block Time Remaining: 00:02:36
TUTOR

4 | Feedback | Suspend | End Block

Typically, granulosa-theca cell tumors are **unilateral** and large. Unlike epithelial ovarian cancers, these masses **secrete estrogen** and can present with **endometrial hyperplasia** (eg, postmenopausal bleeding with thickened endometrium on ultrasound). The unopposed estrogen leads to hyperplasia of the endometrial cells and glands, and the increased cellular division of the hyperplastic cells in turn increases the risk of cellular atypia and endometrial carcinoma. In young patients, excessive estrogen levels may cause precocious sexual development.

(Choice A) α-fetoprotein (AFP) is normally produced by the fetal liver and yolk sac, but it can also be used as a tumor marker in patients with hepatocellular, nonseminomatous testicular, or ovarian carcinomas.

(Choice B) β-hCG is used to confirm pregnancy and screen for gestational trophoblastic disease and germ cell tumors.

(Choice C) Cancer antigen 125 (CA-125) is elevated in epithelial carcinomas of the ovary (eg, serous, endometrioid, clear cell). Stromal tumors do not release significant amounts of CA-125.

(Choice E) Testosterone is produced by Sertoli-Leydig tumors, another type of ovarian sex cord tumor. Affected patients present with evidence of hyperandrogenism (eg, hirsutism, clitoromegaly, deepening voice).

(Choice F) Struma ovarii is a germ cell tumor of the ovary that can cause hyperthyroidism by secreting thyroxine. Histopathology of this tumor reveals mature thyroid tissue.

Educational objective:
Granulosa cell tumors are sex-cord stromal tumors of the ovary that secrete estrogen and can cause endometrial hyperplasia. Call-Exner bodies (cells arranged in a microfollicular or rosette pattern) are seen on microscopy. On gross pathology, the tumor appears yellow due to the lipid content in theca cells.

References

- Pathology of the adnexal mass.

Pathology	Female Reproductive System & Breast	Ovarian cancer
Subject	System	Topic

Copyright © UWorld. All rights reserved.

A 29-year-old man comes to the office due to increased sweating, heat intolerance, insomnia, and unintentional weight loss over the past 4 weeks. The patient has also noticed that his right testis feels bigger than the left but has had no scrotal pain. He has no prior medical problems and takes no medications. The patient does not use tobacco, alcohol, or illicit drugs. Blood pressure is 121/71 mm Hg and pulse is 108/min. On examination, the thyroid is mildly enlarged. Testicular examination reveals an enlarged, nontender right testicle. Laboratory testing shows elevated serum thyroxine and triiodothyronine levels. Scrotal ultrasonography demonstrates a hypoechoic mass within the right testicle. Elevated levels of which of the following substances would most likely explain this patient's symptoms?

A. Alpha-fetoprotein

B. Follicle-stimulating hormone

C. Human chorionic gonadotropin

D. Lactate dehydrogenase

E. Placenta-like alkaline phosphatase

Submit

A 29-year-old man comes to the office due to increased sweating, heat intolerance, insomnia, and unintentional weight loss over the past 4 weeks. The patient has also noticed that his right testis feels bigger than the left but has had no scrotal pain. He has no prior medical problems and takes no medications. The patient does not use tobacco, alcohol, or illicit drugs. Blood pressure is 121/71 mm Hg and pulse is 108/min. On examination, the thyroid is mildly enlarged. Testicular examination reveals an enlarged, nontender right testicle. Laboratory testing shows elevated serum thyroxine and triiodothyronine levels. Scrotal ultrasonography demonstrates a hypoechoic mass within the right testicle. Elevated levels of which of the following substances would most likely explain this patient's symptoms?

- A. Alpha-fetoprotein (10%)
- B. Follicle-stimulating hormone (19%)
- ✓ C. Human chorionic gonadotropin (61%)
- D. Lactate dehydrogenase (4%)
- E. Placenta-like alkaline phosphatase (3%)

Omitted
Correct answer
C

61%
Answered correctly

02 secs
Time Spent

03/01/2020
Last Updated

Explanation

Common serum tumor markers	
Marker	Tumor associations

Common serum tumor markers	
Marker	**Tumor associations**
Alpha-fetoprotein	• Hepatocellular carcinoma • Germ cell
CA 19-9	• Pancreatic
CA 125	• Ovarian
Carcinoembryonic antigen	• Gastrointestinal (eg, colorectal)
Human chorionic gonadotropin	• Choriocarcinoma • Germ cell
Prostate-specific antigen	• Prostate

The human glycoprotein hormone family includes 4 hormones: hCG, TSH, FSH, and LH. Each is a heterodimeric structure consisting of an identical alpha subunit noncovalently associated with a unique but homologous beta subunit, which confers its specific biologic properties. The beta subunits of **hCG and TSH share significant sequence homology**; this structural similarity allows hCG to bind and activate the TSH receptor, albeit with much lower affinity than TSH.

hCG is normally produced in the placenta but can also be released by a number of malignancies, especially **choriocarcinoma** and nonseminomatous **germ cell tumors**. This patient likely has a testicular germ cell tumor producing large quantities of hCG. Activation of TSH receptors on the thyroid gland by high levels of hCG can cause **paraneoplastic hyperthyroidism**, presenting with weight loss, sweating, and heat intolerance.

(Choice A) Alpha-fetoprotein can be used as a tumor marker for a number of malignancies, including hepatocellular carcinoma and nonseminomatous germ cell tumors of the testes. However, elevated levels would not result in symptoms of hyperthyroidism.

The human glycoprotein hormone family includes 4 hormones: hCG, TSH, FSH, and LH. Each is a heterodimeric structure consisting of an identical alpha subunit noncovalently associated with a unique but homologous beta subunit, which confers its specific biologic properties. The beta subunits of **hCG and TSH share significant sequence homology**; this structural similarity allows hCG to bind and activate the TSH receptor, albeit with much lower affinity than TSH.

hCG is normally produced in the placenta but can also be released by a number of malignancies, especially **choriocarcinoma** and nonseminomatous **germ cell tumors**. This patient likely has a testicular germ cell tumor producing large quantities of hCG. Activation of TSH receptors on the thyroid gland by high levels of hCG can cause **paraneoplastic hyperthyroidism**, presenting with weight loss, sweating, and heat intolerance.

(Choice A) Alpha-fetoprotein can be used as a tumor marker for a number of malignancies, including hepatocellular carcinoma and nonseminomatous germ cell tumors of the testes. However, elevated levels would not result in symptoms of hyperthyroidism.

(Choice B) FSH is produced by gonadotrophs in the anterior pituitary cells. It is not a marker for testicular tumors and has no affinity for thyroid receptors.

(Choice D) Lactate dehydrogenase is an enzyme involved in anaerobic glycolysis. Although increased levels can occur with both seminomatous and nonseminomatous tumors of the testes, this enzyme does not interact with TSH receptors.

(Choice E) The majority of circulating alkaline phosphatase comes from bone, liver, gastrointestinal tract, and placenta. Placenta-like alkaline phosphatase is a nonspecific tumor marker that can be increased in testicular seminoma and other malignancies but has no homology with TSH.

Educational objective:
Human chorionic gonadotropin (hCG) has a structure similar to TSH. Patients with testicular germ cell tumors or gestational trophoblastic disease may develop very high serum hCG concentrations, which can stimulate TSH receptors and cause paraneoplastic hyperthyroidism.

References

- Paraneoplastic hyperthyroidism.
- Thyrotropic action of human chorionic gonadotropin.

hCG is normally produced in the placenta but can also be released by a number of malignancies, especially **choriocarcinoma** and nonseminomatous **germ cell tumors**. This patient likely has a testicular germ cell tumor producing large quantities of hCG. Activation of TSH receptors on the thyroid gland by high levels of hCG can cause **paraneoplastic hyperthyroidism**, presenting with weight loss, sweating, and heat intolerance.

(Choice A) Alpha-fetoprotein can be used as a tumor marker for a number of malignancies, including hepatocellular carcinoma and nonseminomatous germ cell tumors of the testes. However, elevated levels would not result in symptoms of hyperthyroidism.

(Choice B) FSH is produced by gonadotrophs in the anterior pituitary cells. It is not a marker for testicular tumors and has no affinity for thyroid receptors.

(Choice D) Lactate dehydrogenase is an enzyme involved in anaerobic glycolysis. Although increased levels can occur with both seminomatous and nonseminomatous tumors of the testes, this enzyme does not interact with TSH receptors.

(Choice E) The majority of circulating alkaline phosphatase comes from bone, liver, gastrointestinal tract, and placenta. Placenta-like alkaline phosphatase is a nonspecific tumor marker that can be increased in testicular seminoma and other malignancies but has no homology with TSH.

Educational objective:
Human chorionic gonadotropin (hCG) has a structure similar to TSH. Patients with testicular germ cell tumors or gestational trophoblastic disease may develop very high serum hCG concentrations, which can stimulate TSH receptors and cause paraneoplastic hyperthyroidism.

References

- Paraneoplastic hyperthyroidism.
- Thyrotropic action of human chorionic gonadotropin.

Pathology	Male Reproductive System	Testicular cancer
Subject	System	Topic

Copyright © UWorld. All rights reserved.

A 44-year-old woman, gravida 2, para 2, is being evaluated after having several episodes of painless postcoital bleeding. She emigrated from Guatemala 5 years ago and has not received any preventative health care. The patient is married and gave birth to two girls via vaginal delivery at home in Guatemala. Her menstrual periods have been regular, and she uses barrier contraceptives. Speculum examination reveals an ulcerative lesion at the external cervical os. Cervical biopsy shows malignant squamous cells invading the underlying stroma. Further analysis of the malignant cells reveals that a double-stranded DNA virus, which encodes several proteins including E6 and E7, has integrated into the host genome. Which of the following is the most likely mechanism by which these viral proteins are involved in this patient's condition?

- A. Constitutive activation of a cytoplasmic signal transducer protein
- B. Constitutive activation of a transmembrane growth factor receptor
- C. Inactivation of DNA repair proteins
- D. Inhibition of cell cycle regulatory proteins
- E. Enhancement of growth factor synthesis and secretion

Submit

A 44-year-old woman, gravida 2, para 2, is being evaluated after having several episodes of painless postcoital bleeding. She emigrated from Guatemala 5 years ago and has not received any preventative health care. The patient is married and gave birth to two girls via vaginal delivery at home in Guatemala. Her menstrual periods have been regular, and she uses barrier contraceptives. Speculum examination reveals an ulcerative lesion at the external cervical os. Cervical biopsy shows malignant squamous cells invading the underlying stroma. Further analysis of the malignant cells reveals that a double-stranded DNA virus, which encodes several proteins including E6 and E7, has integrated into the host genome. Which of the following is the most likely mechanism by which these viral proteins are involved in this patient's condition?

A. Constitutive activation of a cytoplasmic signal transducer protein (2%)

B. Constitutive activation of a transmembrane growth factor receptor (2%)

C. Inactivation of DNA repair proteins (6%)

✓ D. Inhibition of cell cycle regulatory proteins (85%)

E. Enhancement of growth factor synthesis and secretion (2%)

Omitted
Correct answer
D

85%
Answered correctly

01 sec
Time Spent

03/17/2020
Last Updated

Explanation

This patient has biopsy-confirmed squamous cell **carcinoma of the cervix** as a result of **human papillomavirus (HPV)** infection. HPV is a small double-stranded DNA virus with multiple genotypes. High-risk subtypes 16 and 18 are most commonly identified in cervical cancers.

The oncogenic capability of HPV is dependent on its ability to integrate into the host genome and subsequently produce **viral proteins E6 and E7**,

This patient has biopsy-confirmed squamous cell **carcinoma of the cervix** as a result of **human papillomavirus (HPV)** infection. HPV is a small double-stranded DNA virus with multiple genotypes. High-risk subtypes 16 and 18 are most commonly identified in cervical cancers.

The oncogenic capability of HPV is dependent on its ability to integrate into the host genome and subsequently produce **viral proteins E6 and E7**, which interact with cell cycle regulatory proteins **p53 and Rb**, respectively. E6 binds p53, leading to its ubiquination and subsequent proteasomal degradation. Without p53, the cell is unable to halt cell growth to repair damaged DNA or trigger apoptosis when DNA is damaged beyond repair. Similarly, E7 binds Rb and displaces bound transcription factors, promoting unregulated DNA replication and cyclin-mediated cell cycling. The collective effects of E6 and E7 lead to **inhibition of cell cycle regulation** and evasion of apoptosis, consequently increasing malignant potential.

(Choice A) *RAS* and *BRAF* are proto-oncogenes that code for cytoplasmic signal transducer proteins, which upregulate cellular proliferation and differentiation when activated. Mutations causing constitutive activation of these proteins are linked to development of pancreatic cancer (Ras) and malignant melanomas (BRAF).

(Choice B) Mutations resulting in upregulation of the epithelial growth factor receptor (*EGFR*) gene have been implicated in the development of solid tumors (eg, colon, breast, lung).

(Choice C) MSH2 is a DNA mismatch repair protein encoded by the *MSH2* gene, which leads to ineffective DNA repair when inactivated. This is the pathogenic basis of hereditary nonpolyposis colorectal cancer (HNPCC).

(Choice E) Platelet derived growth factor (PDGF) activity is essential for normal development of the central nervous system during the embryonic period. Upregulation of PDGF synthesis and corresponding receptor activation are responsible for the malignant transformation of glial cells in glioblastoma.

Educational objective:
Human papillomavirus (HPV) oncogenicity relies on the inhibitory effects of viral proteins E6 and E7 on cell cycle regulatory proteins p53 and Rb. This allows cells infected with HPV to undergo unchecked cellular proliferation and evasion of apoptosis, promoting genomic instability and malignant transformation.

References

- The role of HPV E6 and E7 oncoproteins in HPV-associated cervical carcinogenesis.

A 29-year-old woman comes to the office due to an intermittent nipple discharge for the past several weeks. She has had no fever or breast pain. The patient has never been pregnant despite having unprotected intercourse. She experienced menarche at age 12. Beginning a year ago, the patient's menses slowed to 2- to 3-month intervals and stopped completely 6 months ago. She has no other medical conditions and takes no medications. The patient's mother was diagnosed with metastatic breast cancer at age 60 and died recently. BMI is 31 kg/m^2. On physical examination, white discharge is expressible from both nipples. The remainder of the physical examination is within normal limits. Urine β-hCG testing is negative. Which of the following is the most likely diagnosis in this patient?

- A. Fibroadenoma
- B. Fibrocystic changes of the breast
- C. Galactocele
- D. Inflammatory breast carcinoma
- E. Intraductal papilloma
- F. Lobular breast carcinoma
- G. Paget disease of the breast
- H. Pituitary adenoma

Submit

A 29-year-old woman comes to the office due to an intermittent nipple discharge for the past several weeks. She has had no fever or breast pain. The patient has never been pregnant despite having unprotected intercourse. She experienced menarche at age 12. Beginning a year ago, the patient's menses slowed to 2- to 3-month intervals and stopped completely 6 months ago. She has no other medical conditions and takes no medications. The patient's mother was diagnosed with metastatic breast cancer at age 60 and died recently. BMI is 31 kg/m^2. On physical examination, white discharge is expressible from both nipples. The remainder of the physical examination is within normal limits. Urine β-hCG testing is negative. Which of the following is the most likely diagnosis in this patient?

A. Fibroadenoma (0%)

B. Fibrocystic changes of the breast (1%)

C. Galactocele (5%)

D. Inflammatory breast carcinoma (0%)

E. Intraductal papilloma (7%)

F. Lobular breast carcinoma (0%)

G. Paget disease of the breast (1%)

✓ H. Pituitary adenoma (82%)

Omitted
Correct answer
H

82%
Answered correctly

01 sec
Time Spent

02/02/2020
Last Updated

Explanation

Prolactinoma	
Clinical features	• **Premenopausal women**: Oligomenorrhea/amenorrhea, infertility, galactorrhea, hot flashes, decreased bone density • **Postmenopausal women**: Mass-effect symptoms (headache, visual field defects) • **Men**: Infertility, decreased libido, impotence, gynecomastia
Laboratory/ imaging	• Serum prolactin (often >200 ng/mL) • Tests to rule out renal insufficiency (creatinine) & hypothyroidism (TSH, thyroxine) • MRI of the brain/pituitary
Treatment	• Dopamine agonist (cabergoline) • Trans-sphenoidal surgery

Galactorrhea is the abnormal secretion of breast milk not associated with pregnancy or breastfeeding. It is most commonly due to excess prolactin, which directly stimulates milk secretion in the breasts. **Hyperprolactinemia** also causes **amenorrhea** in women due to the inhibitory effect of prolactin on hypothalamic GnRH secretion.

Lactotroph adenomas (**prolactinomas**) are the most common hormonally active pituitary tumors and can cause very high prolactin levels. In addition, unlike most pituitary hormones, which are under positive regulation from the hypothalamus, prolactin is under negative regulation by hypothalamic dopaminergic neurons via the pituitary stalk, and any disruption of these pathways (eg, by a nonfunctioning pituitary adenoma) can cause moderate hyperprolactinemia.

In premenopausal women, such as this patient, prolactinomas typically present with galactorrhea and irregular menses. However, in men and postmenopausal women, early symptoms (eg, decreased libido) are often mild and nonspecific, and presentation typically occurs at a later stage with headaches and bitemporal hemianopsia due to compression of the optic chiasm in the **suprasellar region**. The diagnosis can be confirmed by **MRI of the brain**, and **dopamine agonists** (eg, bromocriptine, cabergoline) can be used to suppress prolactin secretion.

(Choice A) Fibroadenomas are benign neoplasms of the breast that often occur in young women. They present as a painless unilateral breast mass without nipple discharge.

Lactotroph adenomas (**prolactinomas**) are the most common hormonally active pituitary tumors and can cause very high prolactin levels. In addition, unlike most pituitary hormones, which are under positive regulation from the hypothalamus, prolactin is under negative regulation by hypothalamic dopaminergic neurons via the pituitary stalk, and any disruption of these pathways (eg, by a nonfunctioning pituitary adenoma) can cause moderate hyperprolactinemia.

In premenopausal women, such as this patient, prolactinomas typically present with galactorrhea and irregular menses. However, in men and postmenopausal women, early symptoms (eg, decreased libido) are often mild and nonspecific, and presentation typically occurs at a later stage with headaches and bitemporal hemianopsia due to compression of the optic chiasm in the **suprasellar region**. The diagnosis can be confirmed by **MRI of the brain**, and **dopamine agonists** (eg, bromocriptine, cabergoline) can be used to suppress prolactin secretion.

(Choice A) Fibroadenomas are benign neoplasms of the breast that often occur in young women. They present as a painless unilateral breast mass without nipple discharge.

(Choice B) Fibrocystic changes of the breast, a normal variant in which breasts feel dense and lumpy, commonly presents with cyclic mastalgia.

(Choice C) Galactocele, a mass filled with breast milk, can occur with hyperprolactinemia but is more often seen with normal lactation following pregnancy.

(Choices D, F, and G) Inflammatory breast carcinoma presents with diffuse breast induration, erythema, and peau d'orange (orange peel) skin due to blockage of lymphatic drainage by cancerous invasion. Lobular breast carcinoma typically presents as a painless breast mass. Paget disease is a manifestation of ductal carcinoma characterized by crusty, scaly redness on the nipple and areola with oozing and bleeding. Breast cancer may be associated with nipple discharge, but white galactorrhea is unusual, and menses are generally unaffected.

(Choice E) Intraductal papilloma is a benign tumor within the mammary duct. It is the most common cause of spontaneous nipple discharge, but the discharge is unilateral and typically bloody or serosanguineous.

Educational objective:
Prolactinomas are the most common hormonally active pituitary adenomas. The excess prolactin produced by these tumors can cause galactorrhea and amenorrhea in premenopausal women. With a large mass, visual changes and headaches may occur due to compression of the optic chiasm.

Exhibit Display

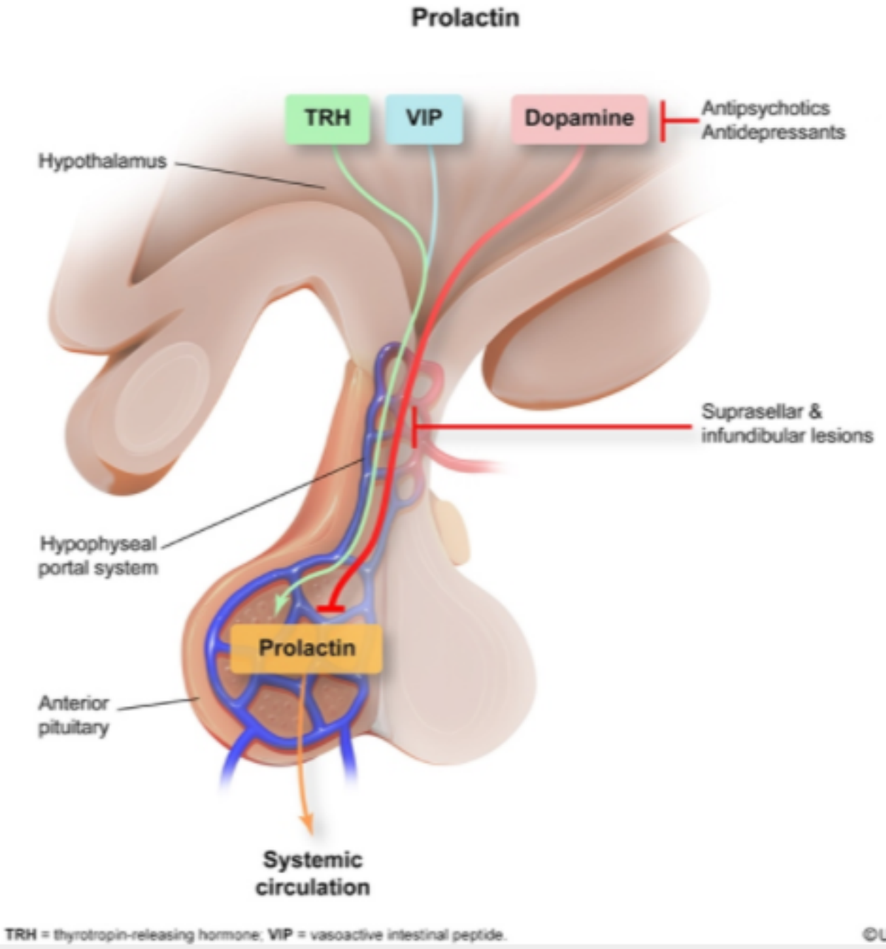

Zoom In | Zoom Out | Reset | Add To New Card | Existing Card

optic chiasm.

Settings

1
2
3
4
5
6
7
8
9
10
11
12
13
14
15
16
17
18
19
20
21
22
23
24
25
26
27
28
29
30

Item 28 of 32
Question Id: 1917

Mark | Previous | Next | Full Screen | Tutorial | Lab Values | Notes | Calculator | Reverse Color | Text Zoom | Settings

Exhibit Display

Zoom In | Zoom Out | Reset | Add To New Card | Existing Card

optic chiasm.

Block Time Remaining: 00:02:40
TUTOR

3 | Feedback | Suspend | End Block

Settings

1
2
3
4
5
6
7
8
9
10
11
12
13
14
15
16
17
18
19
20
21
22
23
24
25
26
27
28
29
30

Item 28 of 32
Question Id: 1917

Mark | Previous | Next | Full Screen | Tutorial | Lab Values | Notes | Calculator | Reverse Color | Text Zoom | Settings

Exhibit Display

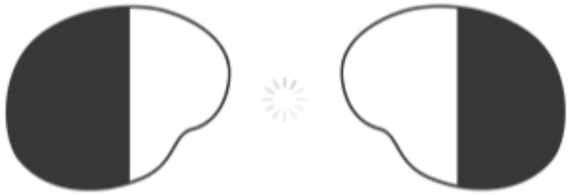

Zoom In | Zoom Out | Reset | Add To New Card | Existing Card

Block Time Remaining: 00:02:40
TUTOR

3 | Feedback | Suspend | End Block

(Choice A) Fibroadenomas are benign neoplasms of the breast that often occur in young women. They present as a painless unilateral breast mass without nipple discharge.

(Choice B) Fibrocystic changes of the breast, a normal variant in which breasts feel dense and lumpy, commonly presents with cyclic mastalgia.

(Choice C) Galactocele, a mass filled with breast milk, can occur with hyperprolactinemia but is more often seen with normal lactation following pregnancy.

(Choices D, F, and G) Inflammatory breast carcinoma presents with diffuse breast induration, erythema, and peau d'orange (orange peel) skin due to blockage of lymphatic drainage by cancerous invasion. Lobular breast carcinoma typically presents as a painless breast mass. Paget disease is a manifestation of ductal carcinoma characterized by crusty, scaly redness on the nipple and areola with oozing and bleeding. Breast cancer may be associated with nipple discharge, but white galactorrhea is unusual, and menses are generally unaffected.

(Choice E) Intraductal papilloma is a benign tumor within the mammary duct. It is the most common cause of spontaneous nipple discharge, but the discharge is unilateral and typically bloody or serosanguineous.

Educational objective:
Prolactinomas are the most common hormonally active pituitary adenomas. The excess prolactin produced by these tumors can cause galactorrhea and amenorrhea in premenopausal women. With a large mass, visual changes and headaches may occur due to compression of the optic chiasm.

References

- Update on prolactinomas. Part 1: clinical manifestations and diagnostic challenges.
- Prolactinomas.

Pathology	Female Reproductive System & Breast	Pituitary adenoma
Subject	System	Topic

Copyright © UWorld. All rights reserved.

A 34-year-old woman comes to the office for follow-up after 2 abnormal Papanicolaou test results. The patient has had 4 lifetime sex partners, uses oral contraceptive pills, and has never been pregnant. She has no other medical problems and does not use tobacco, alcohol, or illicit drugs. Her mother has breast cancer. Physical examination is normal. A cervical biopsy reveals high-grade cervical intraepithelial neoplasia. Which of the following is the most likely finding on histopathology?

A. Atypical glandular elements invading the basement membrane

B. Cells with nuclear atypia only in the basal epithelial layer

C. Expansion of immature basal cells to the epithelial surface

D. Nests of atypical cells in the subepithelial stroma

E. Suprabasilar cells with perinuclear vacuolization only

Submit

A 34-year-old woman comes to the office for follow-up after 2 abnormal Papanicolaou test results. The patient has had 4 lifetime sex partners, uses oral contraceptive pills, and has never been pregnant. She has no other medical problems and does not use tobacco, alcohol, or illicit drugs. Her mother has breast cancer. Physical examination is normal. A cervical biopsy reveals high-grade cervical intraepithelial neoplasia. Which of the following is the most likely finding on histopathology?

- A. Atypical glandular elements invading the basement membrane (13%)
- B. Cells with nuclear atypia only in the basal epithelial layer (15%)
- ✓ C. Expansion of immature basal cells to the epithelial surface (53%)
- D. Nests of atypical cells in the subepithelial stroma (11%)
- E. Suprabasilar cells with perinuclear vacuolization only (5%)

Omitted
Correct answer
C

53%
Answered correctly

01 sec
Time Spent

01/21/2020
Last Updated

Explanation

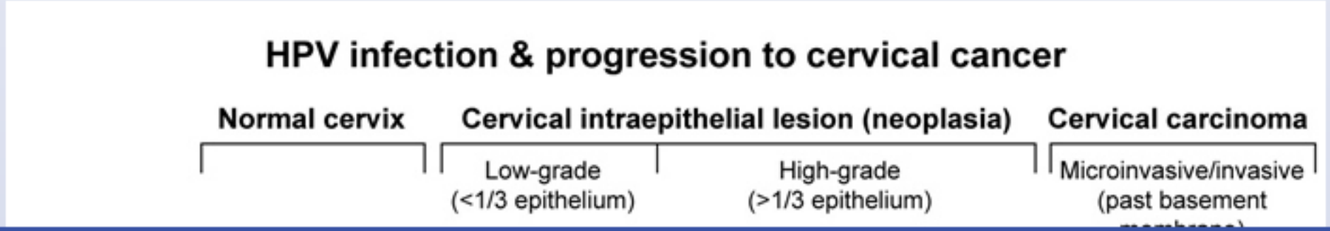

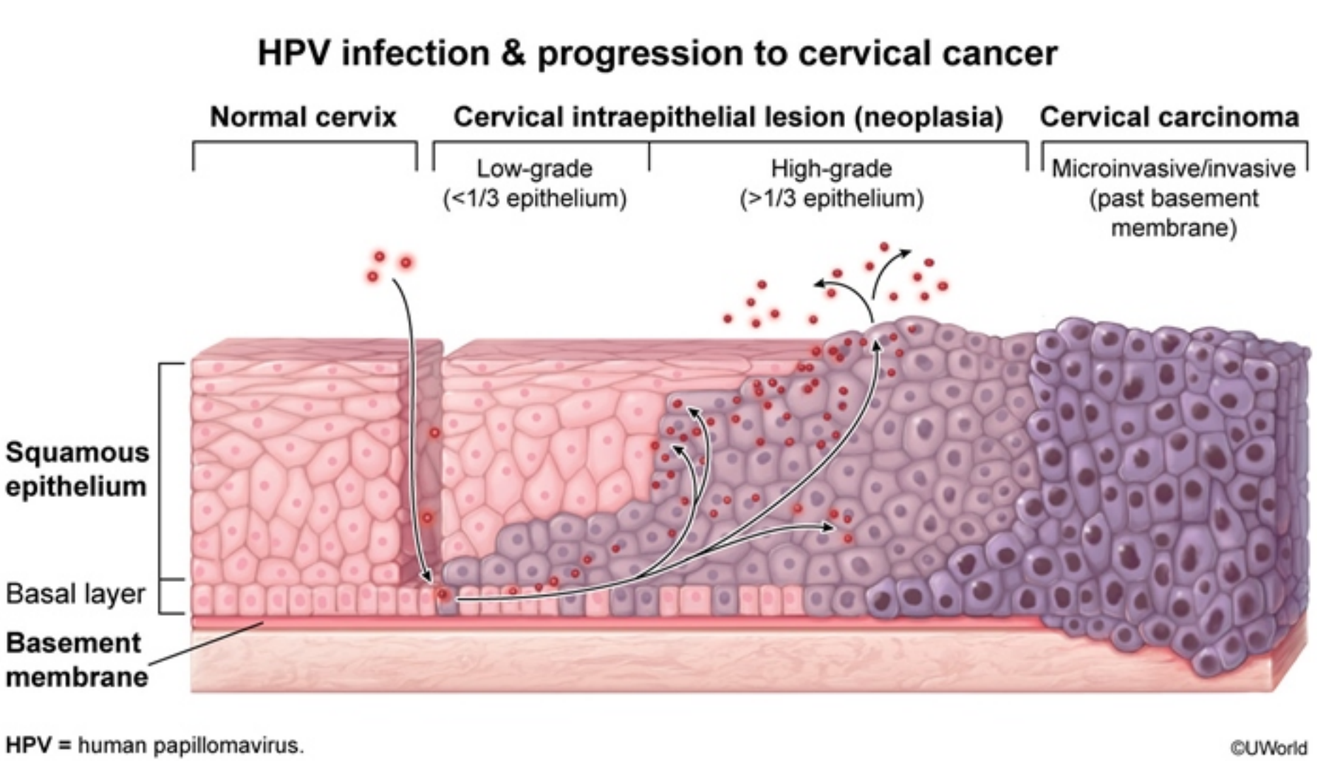

Human papillomavirus (HPV) infection of basal cervical cells can progress to malignancy. Cervical cancer screening is initially done with cervical cytology in Papanicolaou (Pap) tests, which sometimes leads to further evaluation (eg, colposcopy, biopsy) if certain squamous or glandular abnormalities are seen.

This patient had 2 abnormal Pap test results and now has a biopsy showing **cervical intraepithelial neoplasia (CIN)**, which indicates one of the following types of **squamous** abnormalities:

- **High-grade CIN** (high-grade squamous intraepithelial lesions [HSILs]) means that the atypical cells have invaded **beyond the lower one-third** of the cervical epithelium (eg, to the **epithelial surface**), as seen on this patient's biopsy. HSILs have a high rate of progression to

abnormalities are seen.

This patient had 2 abnormal Pap test results and now has a biopsy showing **cervical intraepithelial neoplasia (CIN)**, which indicates one of the following types of **squamous** abnormalities:

- **High-grade CIN** (high-grade squamous intraepithelial lesions [HSILs]) means that the atypical cells have invaded **beyond the lower one-third** of the cervical epithelium (eg, to the **epithelial surface**), as seen on this patient's biopsy. HSILs have a high rate of progression to cancer.
- Low-grade CIN (low-grade squamous intraepithelial lesions [LSILs]) means that the cells have not invaded past the lower one-third of the cervical epithelium. In most cases, LSILs regress spontaneously **(Choice B)**.

(Choices A and D) Basement membrane invasion (eg, atypical cells in subepithelial stroma) signifies carcinoma. When atypical glandular cells (originating from the endocervix) are seen on Pap tests, a biopsy is often required and can reveal squamous CIN, despite the original glandular findings.

(Choice E) HPV infection can cause perinuclear vacuolization (koilocytic change) due to viral proteins. This does not reflect any malignant or premalignant conditions.

Educational objective:
Human papillomavirus infection of basal cervical cells can progress to premalignant and cancerous lesions. Cervical intraepithelial neoplasia refers to atypical squamous cells and is classified as low-grade squamous intraepithelial lesions (if extending <1/3 of the epithelium) or high-grade squamous intraepithelial lesions (if extending beyond). Basement membrane breach signifies invasive disease.

References

- The Pap Test and Bethesda 2014. "The reports of my demise have been greatly exaggerated." (after a quotation from Mark Twain).
- A fusion-based approach for uterine cervical cancer histology image classification.
- The Lower Anogenital Squamous Terminology Standardization project for HPV-associated lesions: background and consensus recommendations from the College of American Pathologists and the American Society for Colposcopy and Cervical Pathology.

A 29-year-old nulliparous woman with HIV comes to the office for her first gynecological examination. The patient acquired HIV from her mother at birth and has been noncompliant with health maintenance visits. Menarche was at age 10, cycles occur every 28 days, and her last menstrual period was 2 weeks ago. The patient has 1 lifetime male partner with whom she has been sexually active for 7 years; they use condoms consistently. Her mother had cervical cancer at age 46 and died of AIDS-related complications at age 48. The patient drinks 3-4 cans of beer each night and does not use tobacco or illicit drugs. Papanicolaou test reveals high-grade cervical dysplasia. Which of the following is the strongest risk factor for cervical dysplasia in this patient?

- A. Age at first intercourse
- B. Alcohol consumption
- C. Early menarche
- D. Family history of cervical cancer
- E. Immunosuppression
- F. Nulliparity

Submit

A 29-year-old nulliparous woman with HIV comes to the office for her first gynecological examination. The patient acquired HIV from her mother at birth and has been noncompliant with health maintenance visits. Menarche was at age 10, cycles occur every 28 days, and her last menstrual period was 2 weeks ago. The patient has 1 lifetime male partner with whom she has been sexually active for 7 years; they use condoms consistently. Her mother had cervical cancer at age 46 and died of AIDS-related complications at age 48. The patient drinks 3-4 cans of beer each night and does not use tobacco or illicit drugs. Papanicolaou test reveals high-grade cervical dysplasia. Which of the following is the strongest risk factor for cervical dysplasia in this patient?

- A. Age at first intercourse (14%)
- B. Alcohol consumption (0%)
- C. Early menarche (4%)
- D. Family history of cervical cancer (15%)
- ✓ E. Immunosuppression (61%)
- F. Nulliparity (2%)

Omitted
Correct answer
E

61%
Answered correctly

02 secs
Time Spent

05/11/2020
Last Updated

Explanation

Risk factors for cervical cancer

Risk factors for cervical cancer
• Infection with high-risk HPV strains (eg, 16, 18) • History of sexually transmitted diseases • Early onset of sexual activity • Multiple or high-risk sexual partners • Immunosuppression • Oral contraceptive use • Low socioeconomic status • Tobacco use

HPV = human papillomavirus.

The strongest risk factor for **cervical dysplasia** (also known as cervical intraepithelial neoplasia) and **carcinoma** is infection with **human papillomavirus (HPV) type 16 or 18**. HPV is transmitted primarily through sexual intercourse but can also be spread via skin-to-skin contact. Most invasive cervical cancer specimens and high-grade cervical lesions contain HPV DNA. Other risk factors for cervical dysplasia are listed in the table above.

Cervical cancer is rare in young immunocompetent women as their immune systems can normally combat HPV infection. Approximately 50% of patients with untreated high-grade dysplasia will experience spontaneous regression, whereas only 5% will develop invasive cancer. However, individuals with **HIV** are unable to mount an immune response against HPV due to **immunosuppression** from **T cell deficiency**. Therefore, patients with HIV infection commonly have persistent HPV infection, which allows HPV DNA to become incorporated into the epithelial cells. HIV coinfection may also enhance expression of HPV **viral oncogenes E6 and E7**, leading to cervical dysplasia/cancer. Therefore, patients with HIV require frequent Papanicolaou screening for cervical dysplasia/cancer.

(Choice A) Women who have intercourse before age 18 have twice the risk of cervical cancer compared to women who have initial intercourse after age 21.

(Choice B) Alcohol consumption increases the risk of breast cancer but is not associated with cervical cancer. However, tobacco use is a

The strongest risk factor for **cervical dysplasia** (also known as cervical intraepithelial neoplasia) and **carcinoma** is infection with **human papillomavirus (HPV) type 16 or 18**. HPV is transmitted primarily through sexual intercourse but can also be spread via skin-to-skin contact. Most invasive cervical cancer specimens and high-grade cervical lesions contain HPV DNA. Other risk factors for cervical dysplasia are listed in the table above.

Cervical cancer is rare in young immunocompetent women as their immune systems can normally combat HPV infection. Approximately 50% of patients with untreated high-grade dysplasia will experience spontaneous regression, whereas only 5% will develop invasive cancer. However, individuals with **HIV** are unable to mount an immune response against HPV due to **immunosuppression** from **T cell deficiency**. Therefore, patients with HIV infection commonly have persistent HPV infection, which allows HPV DNA to become incorporated into the epithelial cells. HIV coinfection may also enhance expression of HPV **viral oncogenes E6 and E7**, leading to cervical dysplasia/cancer. Therefore, patients with HIV require frequent Papanicolaou screening for cervical dysplasia/cancer.

(Choice A) Women who have intercourse before age 18 have twice the risk of cervical cancer compared to women who have initial intercourse after age 21.

(Choice B) Alcohol consumption increases the risk of breast cancer but is not associated with cervical cancer. However, tobacco use is a significant risk factor for cervical cancer.

(Choice C) Age at menarche does not affect cervical cancer risk. However, women with menarche before age 12 are at increased risk for breast and endometrial cancers.

(Choice D) Family history of cervical cancer is not a risk factor for cervical dysplasia/cancer. There is no genetic component to cervical dysplasia/cancer as the majority of cervical dysplasias and cancers are caused by HPV, and HPV is a predominantly sexually transmitted infection.

(Choice F) Parity does not affect cervical cancer risk. Anovulatory cycles in nulliparous women increase the risk of endometrial cancer.

Educational objective:
Human papillomavirus (HPV) infection, especially with strain 16 or 18, is the strongest risk factor for development of cervical dysplasia and invasive cervical carcinoma. HIV coinfection allows HPV infection to persist and enhances expression of HPV oncogenes, increasing the risk for

require frequent Papanicolaou screening for cervical dysplasia/cancer.

(Choice A) Women who have intercourse before age 18 have twice the risk of cervical cancer compared to women who have initial intercourse after age 21.

(Choice B) Alcohol consumption increases the risk of breast cancer but is not associated with cervical cancer. However, tobacco use is a significant risk factor for cervical cancer.

(Choice C) Age at menarche does not affect cervical cancer risk. However, women with menarche before age 12 are at increased risk for breast and endometrial cancers.

(Choice D) Family history of cervical cancer is not a risk factor for cervical dysplasia/cancer. There is no genetic component to cervical dysplasia/cancer as the majority of cervical dysplasias and cancers are caused by HPV, and HPV is a predominantly sexually transmitted infection.

(Choice F) Parity does not affect cervical cancer risk. Anovulatory cycles in nulliparous women increase the risk of endometrial cancer.

Educational objective:
Human papillomavirus (HPV) infection, especially with strain 16 or 18, is the strongest risk factor for development of cervical dysplasia and invasive cervical carcinoma. HIV coinfection allows HPV infection to persist and enhances expression of HPV oncogenes, increasing the risk for cervical dysplasia/cancer.

References

- Evidence for frequent regression of cervical intraepithelial neoplasia-grade 2.
- ACOG Practice Bulletin No. 131: screening for cervical cancer.

Pathology	Female Reproductive System & Breast	Cervical cancer
Subject	System	Topic

Copyright © UWorld. All rights reserved.

A 45-year-old man comes to the office due to fatigue, lack of sexual desire, and inability to maintain an erection. A year ago, he was advised to lose weight with diet and exercise due to mildly elevated fasting glucose levels. The patient has smoked a pack of cigarettes daily for the past 20 years and drinks an alcoholic beverage 3-4 times per month. Blood pressure is 110/70 mm Hg and pulse is 65/min. Oxygen saturation is 99% on room air. BMI is 29 kg/m^2. Skin examination shows increased pigmentation over the knuckles and face. The liver is palpable 3-4 cm below the right costal margin. The remainder of the examination reveals small testes. Which of the following is most likely contributing to the development of the patient's symptoms?

A. Aortoiliac atherosclerosis

B. Autoimmune adrenalitis

C. Ectopic ACTH production

D. Fibrosis of the seminiferous tubules

E. Iron deposition in the pituitary gland

Submit

A 45-year-old man comes to the office due to fatigue, lack of sexual desire, and inability to maintain an erection. A year ago, he was advised to lose weight with diet and exercise due to mildly elevated fasting glucose levels. The patient has smoked a pack of cigarettes daily for the past 20 years and drinks an alcoholic beverage 3-4 times per month. Blood pressure is 110/70 mm Hg and pulse is 65/min. Oxygen saturation is 99% on room air. BMI is 29 kg/m^2. Skin examination shows increased pigmentation over the knuckles and face. The liver is palpable 3-4 cm below the right costal margin. The remainder of the examination reveals small testes. Which of the following is most likely contributing to the development of the patient's symptoms?

- A. Aortoiliac atherosclerosis (3%)
- B. Autoimmune adrenalitis (18%)
- C. Ectopic ACTH production (25%)
- D. Fibrosis of the seminiferous tubules (4%)
- ✓ E. Iron deposition in the pituitary gland (48%)

Omitted
Correct answer
E

48%
Answered correctly

01 sec
Time Spent

07/05/2020
Last Updated

Explanation

Clinical manifestations of hereditary hemochromatosis	
Skin	• Hyperpigmentation

Clinical manifestations of hereditary hemochromatosis	
Skin	• Hyperpigmentation
Musculoskeletal	• Arthritis (particularly 2nd & 3rd MCP joints) • Chondrocalcinosis
Gastrointestinal	• Elevated liver enzymes, hepatomegaly (early) • Cirrhosis & hepatocellular carcinoma (late)
Endocrine	• Diabetes mellitus • Hypopituitarism (eg, secondary hypogonadism, hypothyroidism)
Cardiac	• Restrictive or dilated cardiomyopathy • Conduction abnormalities

MCP = metacarpophalangeal.

This patient's decreased libido, erectile dysfunction, and testicular atrophy are indicative of **hypogonadism**. These findings, in combination with **hyperpigmentation** of the skin, **elevated glucose**/diabetes mellitus, and **hepatomegaly**, are strongly suggestive of **hereditary hemochromatosis** (HH).

HH is an autosomal recessive disorder characterized by excessive intestinal iron absorption and accumulation in various tissues. **Secondary hypogonadism** occurs in HH due to **deposition of iron in the pituitary gland**, resulting in decreased gonadotropin secretion and subsequent testicular failure. In women, HH is often not diagnosed until after menopause, as premenopausal women have ongoing menstrual blood loss that usually prevents significant iron overload and symptom development; therefore, amenorrhea is a rare finding in women with HH.

(Choice A) Atherosclerotic disease is a common cause of erectile dysfunction in older men, especially those with a history of smoking, but it typically would not affect libido and would not cause hyperpigmentation or hepatomegaly.

(Choice B) Autoimmune adrenalitis is a common cause of primary adrenal insufficiency (ie, Addison disease). Hyperpigmentation is common

This patient's decreased libido, erectile dysfunction, and testicular atrophy are indicative of **hypogonadism**. These findings, in combination with **hyperpigmentation** of the skin, **elevated glucose**/diabetes mellitus, and **hepatomegaly**, are strongly suggestive of **hereditary hemochromatosis** (HH).

HH is an autosomal recessive disorder characterized by excessive intestinal iron absorption and accumulation in various tissues. **Secondary hypogonadism** occurs in HH due to **deposition of iron in the pituitary gland**, resulting in decreased gonadotropin secretion and subsequent testicular failure. In women, HH is often not diagnosed until after menopause, as premenopausal women have ongoing menstrual blood loss that usually prevents significant iron overload and symptom development; therefore, amenorrhea is a rare finding in women with HH.

(Choice A) Atherosclerotic disease is a common cause of erectile dysfunction in older men, especially those with a history of smoking, but it typically would not affect libido and would not cause hyperpigmentation or hepatomegaly.

(Choice B) Autoimmune adrenalitis is a common cause of primary adrenal insufficiency (ie, Addison disease). Hyperpigmentation is common due to increased cosecretion of melanocyte-stimulating hormone with ACTH, but patients typically have orthostatic hypotension (due to loss of mineralocorticoid) and hypoglycemia (not hyperglycemia).

(Choice C) Ectopic ACTH secretion causes paraneoplastic Cushing syndrome (eg, small cell lung cancer). Patients may develop hyperpigmentation and hyperglycemia but also often have hypertension and proximal muscle weakness. Small testes are not seen.

(Choice D) Testicular fibrosis is a common manifestation of Klinefelter syndrome (KS). Hypogonadism due to KS is typically apparent at puberty and is often associated with a eunuchoid habitus, sparse body hair, and high-pitched voice. Hepatomegaly is not common.

Educational objective:
Hereditary hemochromatosis can cause secondary hypogonadism due to deposition of iron in the pituitary gland, resulting in decreased gonadotropin secretion. Patients who develop secondary hypogonadism are also at risk for deficiencies in other pituitary hormones (eg, central hypothyroidism).

Pathology	Male Reproductive System	Hemochromatosis
Subject	System	Topic

hyperpigmentation of the skin, **elevated glucose**/diabetes mellitus, and **hepatomegaly**, are strongly suggestive of **hereditary hemochromatosis** (HH).

HH is an autosomal recessive disorder characterized by excessive intestinal iron absorption and accumulation in various tissues. **Secondary hypogonadism** occurs in HH due to **deposition of iron in the pituitary gland**, resulting in decreased gonadotropin secretion and subsequent testicular failure. In women, HH is often not diagnosed until after menopause, as premenopausal women have ongoing menstrual blood loss that usually prevents significant iron overload and symptom development; therefore, amenorrhea is a rare finding in women with HH.

(Choice A) Atherosclerotic disease is a common cause of erectile dysfunction in older men, especially those with a history of smoking, but it typically would not affect libido and would not cause hyperpigmentation or hepatomegaly.

(Choice B) Autoimmune adrenalitis is a common cause of primary adrenal insufficiency (ie, Addison disease). Hyperpigmentation is common due to increased cosecretion of melanocyte-stimulating hormone with ACTH, but patients typically have orthostatic hypotension (due to loss of mineralocorticoid) and hypoglycemia (not hyperglycemia).

(Choice C) Ectopic ACTH secretion causes paraneoplastic Cushing syndrome (eg, small cell lung cancer). Patients may develop hyperpigmentation and hyperglycemia but also often have hypertension and proximal muscle weakness. Small testes are not seen.

(Choice D) Testicular fibrosis is a common manifestation of Klinefelter syndrome (KS). Hypogonadism due to KS is typically apparent at puberty and is often associated with a eunuchoid habitus, sparse body hair, and high-pitched voice. Hepatomegaly is not common.

Educational objective:
Hereditary hemochromatosis can cause secondary hypogonadism due to deposition of iron in the pituitary gland, resulting in decreased gonadotropin secretion. Patients who develop secondary hypogonadism are also at risk for deficiencies in other pituitary hormones (eg, central hypothyroidism).

Pathology	Male Reproductive System	Hemochromatosis
Subject	System	Topic

Copyright © UWorld. All rights reserved.

A 26-year-old woman is being evaluated for lower abdominal discomfort. Her past medical history is significant for mild intermittent asthma and migraines without aura. She has never been pregnant. The patient is sexually active with her husband, and they use condoms for contraception. She smokes a half-pack of cigarettes daily and drinks alcohol socially. Her mother was diagnosed with breast cancer at age 52, and her grandfather died of colon cancer at age 77. The patient's BMI is 30 kg/m^2. Ultrasound examination of the abdomen reveals a right-sided adnexal mass that is subsequently removed laparoscopically. Histologic findings are shown in the image below. Which of the following is the most likely diagnosis?



Settings

1 2 3 4 5 6 7 8 9 10 11 12 13 14 15 16 17 18 19 20 21 22 23 24 25 26 27 28 29 30

Item 32 of 32
Question Id: 11652

Mark | Previous | Next | Full Screen | Tutorial | Lab Values | Notes | Calculator | Reverse Color | Text Zoom | Settings

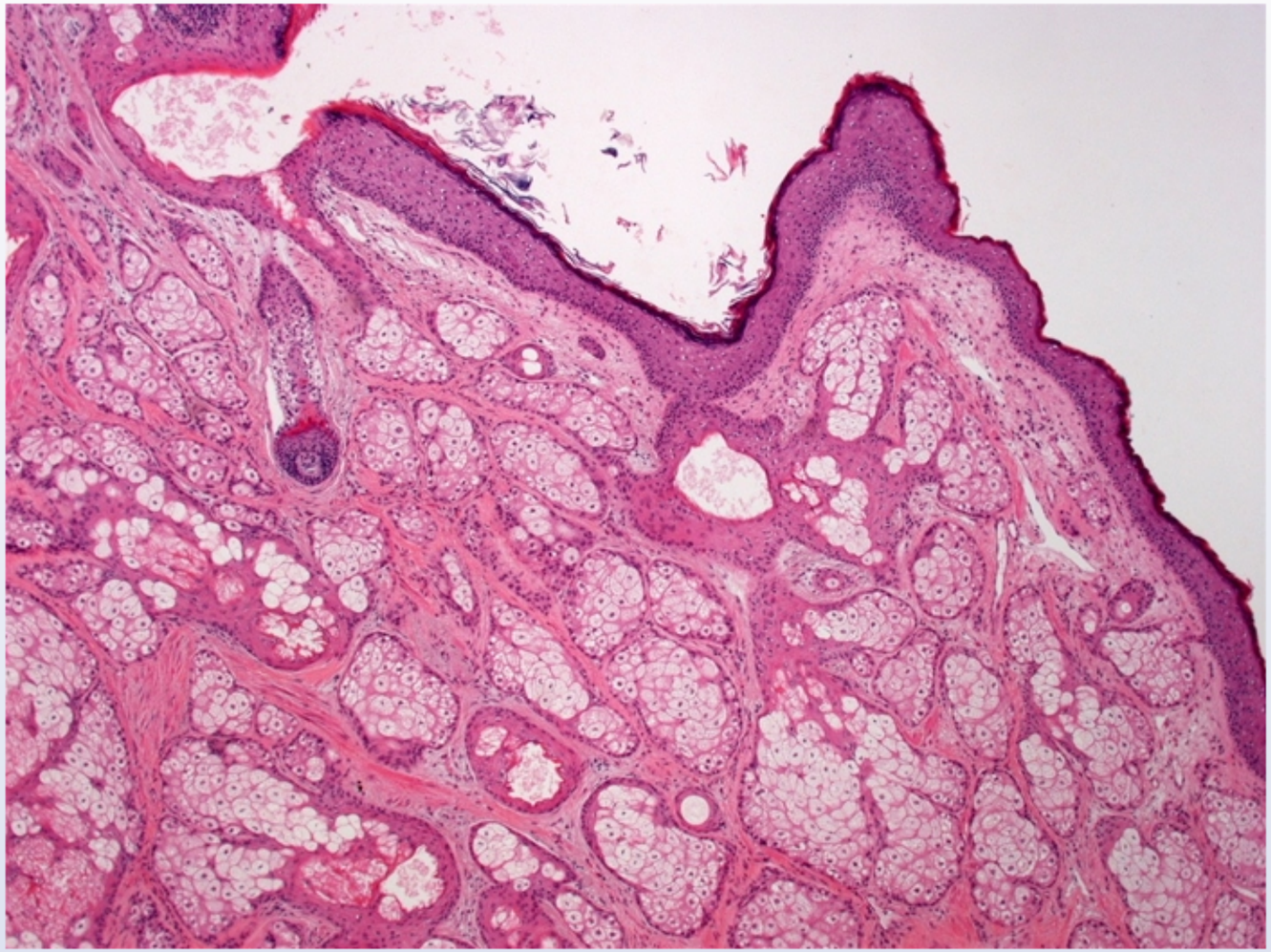

A. Ectopic pregnancy

B. Endometriosis

Block Time Remaining: 00:02:47
TUTOR

6 | Feedback | Suspend | End Block

Settings

1 2 3 4 5 6 7 8 9 10 11 12 13 14 15 16 17 18 19 20 21 22 23 24 25 26 27 28 29 30

Item 32 of 32
Question Id: 11652

Mark | Previous | Next | Full Screen | Tutorial | Lab Values | Notes | Calculator | Reverse Color | Text Zoom | Settings

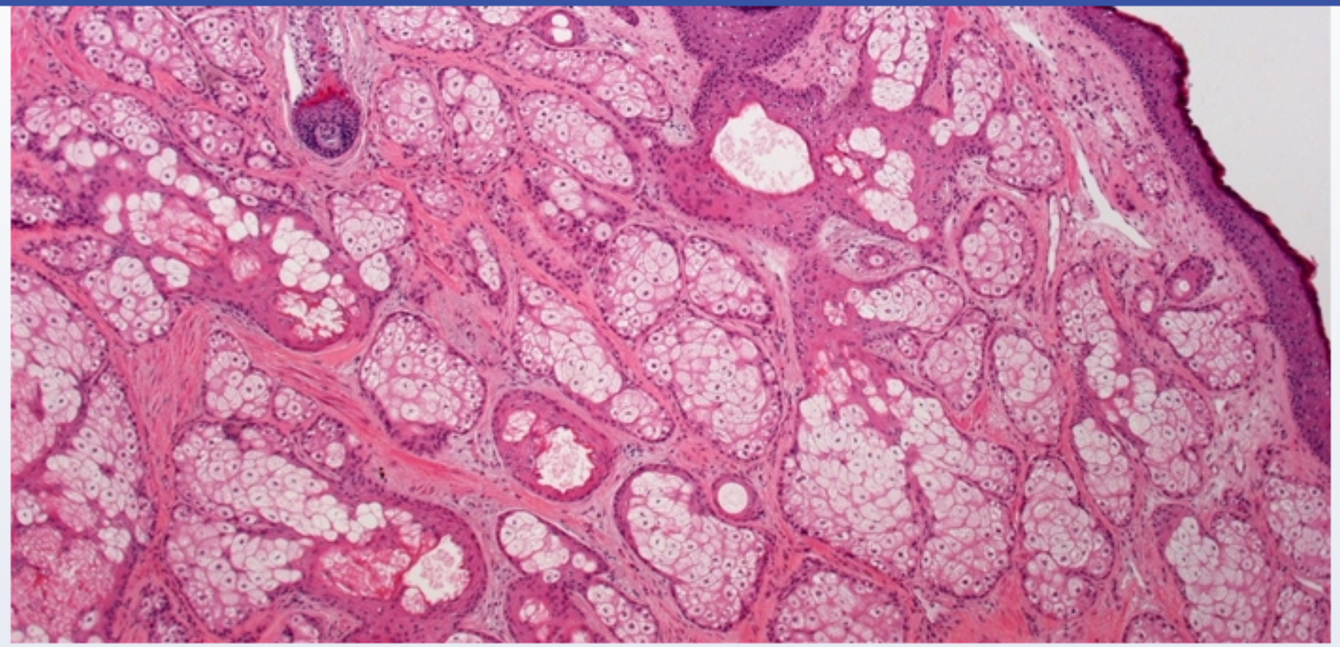

A. Ectopic pregnancy

B. Endometriosis

C. Mature teratoma

D. Ovarian carcinoma

E. Polycystic ovarian syndrome

Submit

Block Time Remaining: 00:02:49
TUTOR

6 | Feedback | Suspend | End Block

Settings

1 2 3 4 5 6 7 8 9 10 11 12 13 14 15 16 17 18 19 20 21 22 23 24 25 26 27 28 29 30

Item 32 of 32
Question Id: 11652

Mark | Previous | Next | Full Screen | Tutorial | Lab Values | Notes | Calculator | Reverse Color | Text Zoom | Settings

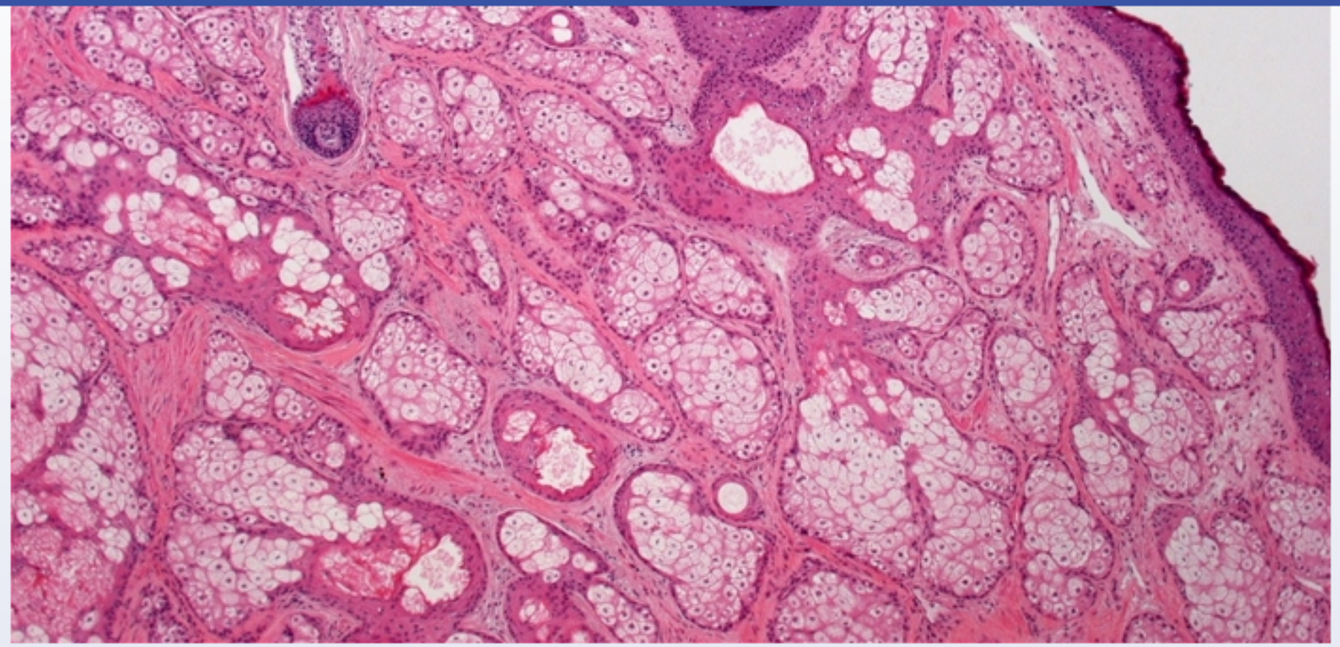

- A. Ectopic pregnancy (3%)
- B. Endometriosis (15%)
- ✓ C. Mature teratoma (36%)
- D. Ovarian carcinoma (31%)
- E. Polycystic ovarian syndrome (13%)

Omitted
Correct answer

36%
Answered correctly

06 secs
Time Spent

05/02/2020
Last Updated

Block Time Remaining: 00:02:50
TUTOR

6 | Feedback | Suspend | End Block

1
2
3
4
5
6
7
8
9
10
11
12
13
14
15
16
17
18
19
20
21
22
23
24
25
26
27
28
29
30

Explanation

This patient has a **teratoma**, one of the most common subtypes of ovarian germ cell tumors (which occur most frequently in females age 10-30). Based on their histologic differentiation, teratomas are divided into mature and immature types. **Mature** teratomas of the ovaries are usually **benign** and contain cell lines of >1 germ layer. A diversity of tissues, including **hair** follicles, skin, **teeth**, bones, and other tissues, can be seen on histologic examination. In the image above, skin tissue (epidermis and keratin) is seen outlining the structure, with abundant sebaceous glands and a hair follicle.

This patient has a **teratoma**, one of the most common subtypes of ovarian germ cell tumors (which occur most frequently in females age 10-30). Based on their histologic differentiation, teratomas are divided into mature and immature types. **Mature** teratomas of the ovaries are usually **benign** and contain cell lines of >1 germ layer. A diversity of tissues, including **hair** follicles, skin, **teeth**, bones, and other tissues, can be seen on histologic examination. In the image above, skin tissue (epidermis and keratin) is seen outlining the structure, with abundant sebaceous glands and a hair follicle.

(Choice A) In ectopic pregnancy, the blastocyst implants outside the endometrial cavity. If not diagnosed in a timely manner, ectopic pregnancies can become life-threatening. Transvaginal ultrasonography and β-hCG measurements are used for diagnosis. Immature chorionic villi would be seen at the site of ectopic implantation (eg, fallopian tube) but not in the uterus.

(Choice B) Endometriosis is normal endometrial mucosa implanted outside the uterine cavity. Histologic features can include the presence of normal endometrium with glands (red arrow) and stroma.

(Choice D) The median age at diagnosis of ovarian carcinoma is 60. Complex cysts, defined by the presence of cystic and solid components, are commonly seen. Depending on the type, histologic findings can include sheets of tumor cells (with enlarged irregular nuclei, prominent nucleoli, and eosinophilic cytoplasm) forming pseudoglandular spaces and papillae.

(Choice E) Polycystic ovarian syndrome presents with polycystic ovaries on ultrasonography, clinical/biochemical evidence of hyperandrogenism, and oligo/anovulation. Histologic changes include enlarged, sclerotic follicles.

Educational objective:
Teratomas are the most common subtype of germ cell tumor. Ovarian teratomas occur most frequently in females age 10-30. They are divided into mature (cell lines of >1 germ layer, commonly including hair, teeth, and skin) and immature types.

References

- Germ cell tumors of the gonads: a selective review emphasizing problems in differential diagnosis, newly appreciated, and controversial issues
- Updates in the management of ovarian germ cell tumors

Settings

1 2 3 4 5 6 7 8 9 10 11 12 13 14 15 16 17 18 19 20 21 22 23 24 25 26 27 28 29 30

Item 32 of 32
Question Id: 11652

Mark | Previous | Next | Full Screen | Tutorial | Lab Values | Notes | Calculator | Reverse Color | Text Zoom | Settings

Exhibit Display

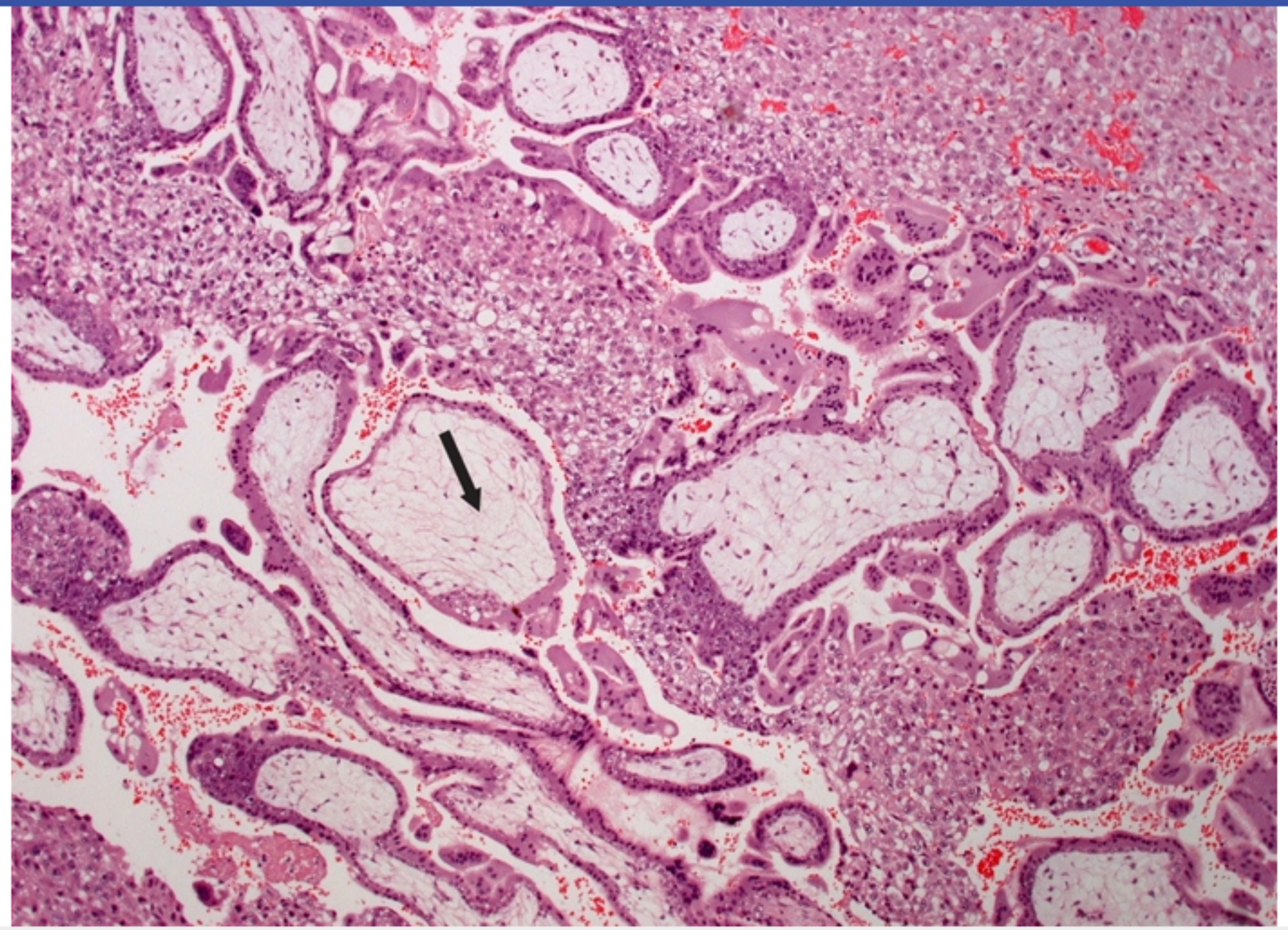

Zoom In | Zoom Out | Reset | Add To New Card | Existing Card

Block Time Remaining: 00:02:50
TUTOR

6 | Feedback | Suspend | End Block

Settings

1 2 3 4 5 6 7 8 9 10 11 12 13 14 15 16 17 18 19 20 21 22 23 24 25 26 27 28 29 30

Item 32 of 32
Question Id: 11652

Mark | Previous | Next | Full Screen | Tutorial | Lab Values | Notes | Calculator | Reverse Color | Text Zoom | Settings

Exhibit Display

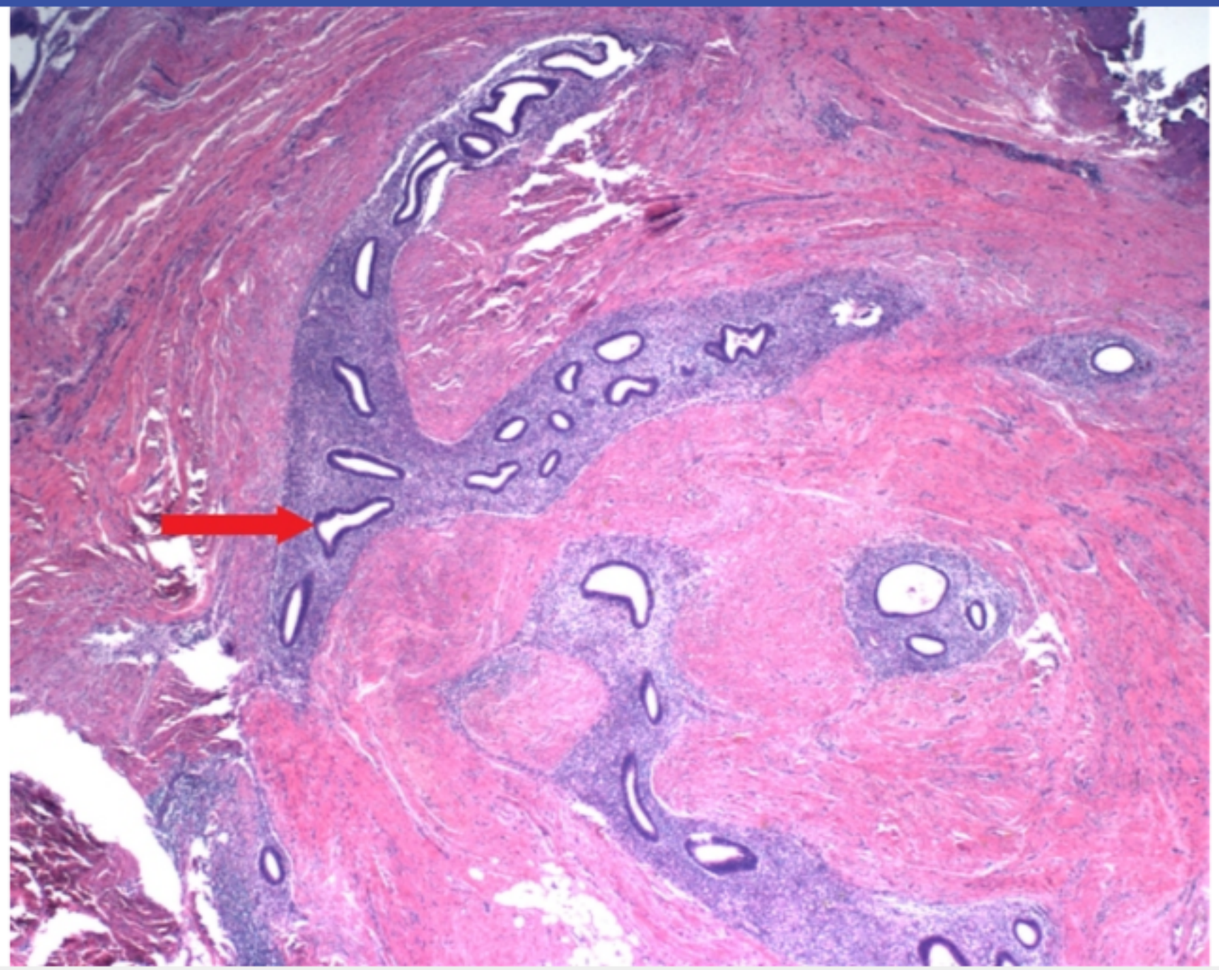

Zoom In | Zoom Out | Reset | Add To New Card | Existing Card

Block Time Remaining: 00:02:50
TUTOR

6 | Feedback | Suspend | End Block

Settings

1 2 3 4 5 6 7 8 9 10 11 12 13 14 15 16 17 18 19 20 21 22 23 24 25 26 27 28 29 30

Item 32 of 32
Question Id: 11652

Mark | Previous | Next | Full Screen | Tutorial | Lab Values | Notes | Calculator | Reverse Color | Text Zoom | Settings

Exhibit Display

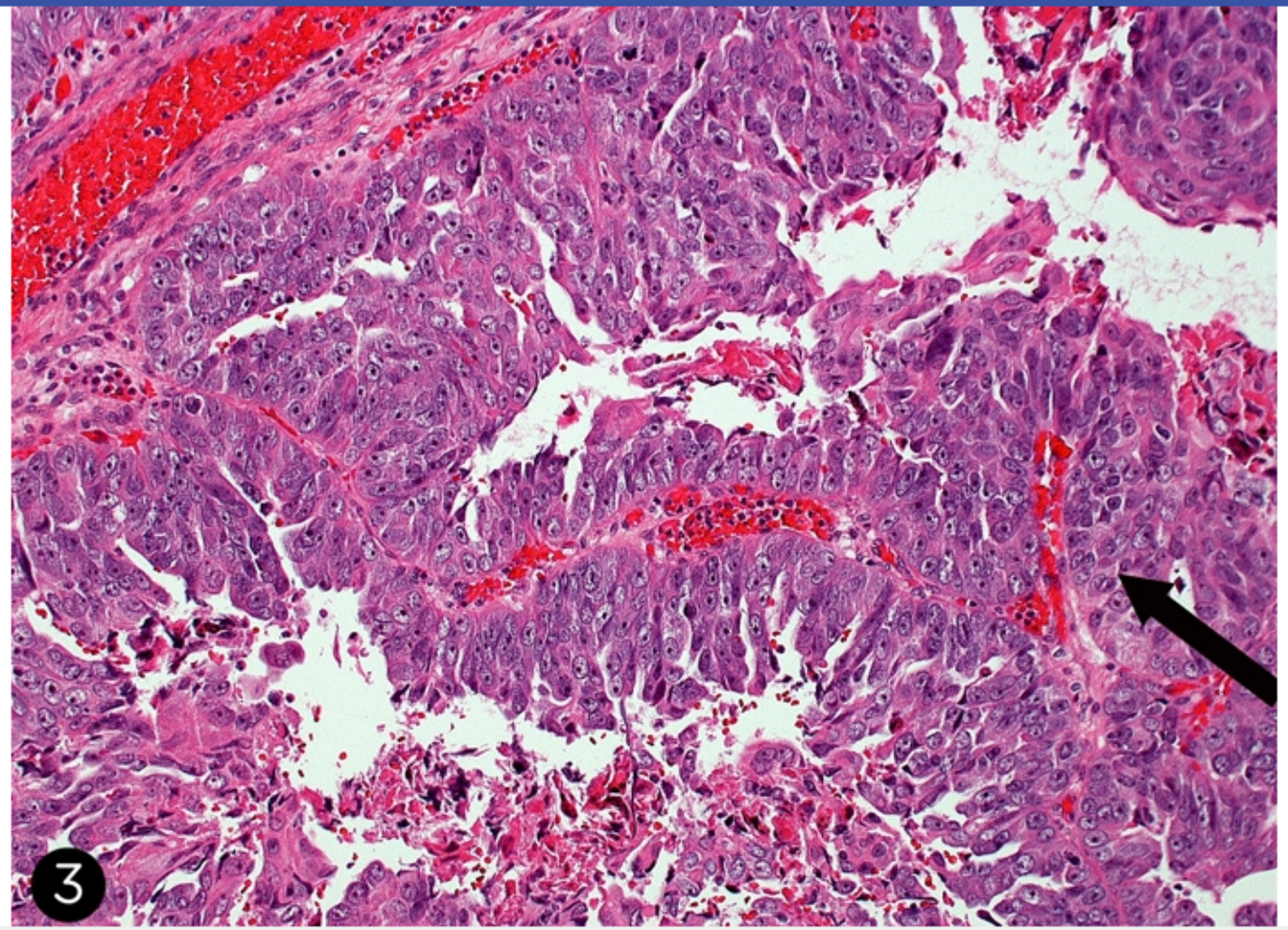

Zoom In | Zoom Out | Reset | Add To New Card | Existing Card

Block Time Remaining: 00:02:50
TUTOR

6 | Feedback | Suspend | End Block